

---

# Preorthodontic Uncovering and Autonomous Eruption of Palatally Impacted Maxillary Canines

Vincent G. Kokich

**Palatally impacted maxillary canines are a challenge for any orthodontist. Often the surgeon will perform an incorrect uncovering technique, the orthodontic mechanics to erupt the tooth could be inappropriate, and as a result the periodontal and esthetic outcome could be disastrous. However, in the adolescent patient, the management of palatally impacted maxillary canines can be predictable, stable, and esthetic. However, to accomplish these results, the orthodontist and surgeon must select the appropriate method of surgical uncovering. This article discusses the advantages of preorthodontic uncovering and autonomous eruption of palatally impacted maxillary canines. The surgical technique will be described and illustrated, and consecutively treated cases will be displayed. An evidence-based discussion will feature the benefits of preorthodontic uncovering and autonomous eruption of palatally impacted maxillary canines. (Semin Orthod 2010; 16:205-211.) © 2010 Elsevier Inc. All rights reserved.**

After mandibular third molars, maxillary canines are the second most commonly impacted teeth among patients referred for orthodontic treatment.<sup>1</sup> The authors of previous studies have shown that approximately two-thirds of maxillary canines are impacted palatally and one-third are impacted labially.<sup>2</sup> The incidence of palatal impaction has been estimated to be within 1% and 2.5% of the general population.<sup>3,4</sup> There are generally 2 methods for managing palatal impactions: preventive and surgical. If a palatal impaction were diagnosed at an early age, and if the crown of the displaced canine were not positioned past the root of the adjacent lateral incisor, extraction of the primary canine could be an effective method of redirecting the eruption of the displaced canine.<sup>5,6</sup> However, if the

tooth were displaced too far toward the mesial or the diagnosis were made at a later age, then primary canine extraction would be ineffective.<sup>4</sup>

Another approach to permit natural correction of the ectopically positioned maxillary canine is to extract the primary canine and open space orthodontically between the maxillary lateral incisor and the primary first molar or permanent first premolar.<sup>7</sup> This method has been shown to predictably redirect the eruptive path of the palatally displaced tooth toward the center of the alveolar ridge. However, this method requires further treatment to consolidate the extra space created by pushing the lateral incisor and premolar apart.

Recently, researchers have shown that the application of cervical headgear in addition to extraction of the maxillary primary canines in young adolescent subjects resulted in an improved path of eruption of the palatally displaced permanent canine in 80% of the cases.<sup>8</sup> However, not all orthodontic patients need cervical headgear as a part of their orthodontic therapy. Therefore, this technique would not be applicable for all patients with palatally impacted canines.

---

*Department of Orthodontics, School of Dentistry, University of Washington, Seattle, WA.*

*Address correspondence to V.G. Kokich, Department of Orthodontics, School of Dentistry, University of Washington, Seattle, WA 98195. E-mail: vggkokich@u.washington.edu*

*© 2010 Elsevier Inc. All rights reserved.*

*1073-8746/10/1603-0\$30.00/0*

*doi:10.1053/j.sodo.2010.05.008*

In most clinical cases of palatal canine impaction, the patient is not referred to the orthodontist until the teeth are fully erupted or the canine crown is displaced significantly toward the mesial and past the lateral incisor root. In these cases, surgical exposure of the canine is necessary followed by orthodontic movement of the tooth into the dental arch. If the canine crown were uncovered surgically, 2 options exist for tooth eruption: autonomous eruption or guided orthodontic eruption. This article discusses the differences in these 2 surgical approaches for correcting palatal impaction of the maxillary canine with an emphasis on autonomous eruption.

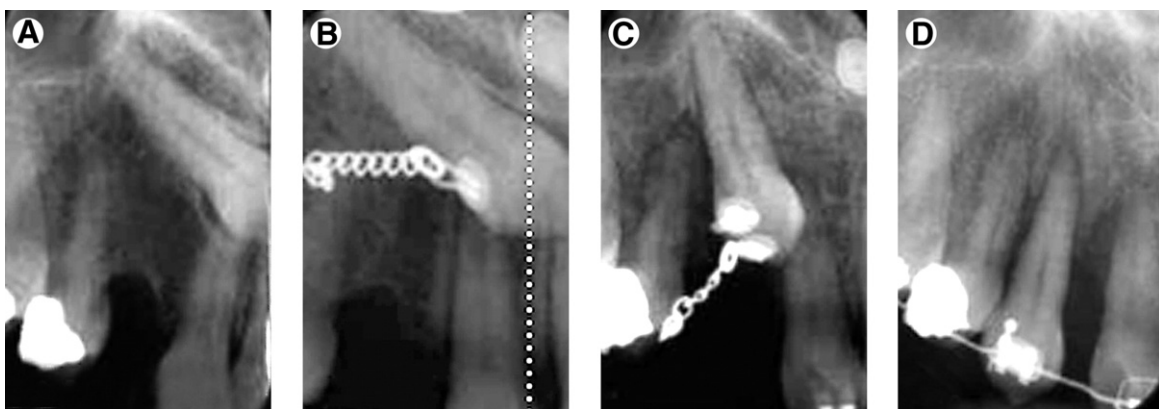
### Closed Eruption

I believe that this term is confusing. It actually refers to elevating a mucoperiosteal flap, exposing the impacted canine crown, removing sufficient bone to permit tooth movement, attaching a piece of gold chain, covering the tooth by repositioning the flap, and leaving the gold chain exiting through the palatal gingiva. Once the area has healed, then the tooth can be guided orthodontically into the oral cavity. This technique has been used for many years to successfully erupt palatally impacted canines. However, if the direction of the eruption were inappropriate, then the crown of the canine could cause root resorption, bone loss, and disadvantageous periodontal consequences (Fig 1).

Becker and Zilberman<sup>9</sup> described the appropriate direction for erupting palatally displaced canines using the closed technique. Their conclusion was that the eruption force should be directed lingually and away from the root of the lateral incisor. This makes sense because this method would not require the canine to be pushed against the palatal bone and would not cause damage to the root of the lateral incisor. Once the crown is erupted into the oral cavity, then it could be moved laterally toward the alveolar ridge.

However, many orthodontists do not use the appropriate direction of eruption for a palatally impacted canine and simply pull the tooth laterally toward the edentulous alveolar ridge (Fig 1). This situation usually meets with immediate resistance when the crown of the canine compresses against the adjacent palatal bone. When enamel meets bone, there are no cells in enamel to resorb the adjacent bone physiologically. Therefore, a process of pressure necrosis occurs as the canine crown is pushed against the bone. The bone will resorb in front of the canine as it eventually moves laterally, but the process occurs slowly (Fig 1B, C). Probably the worst side effect of this type of movement is that as the bone in front of the advancing crown is resorbed, no bone is laid down behind the canine crown (Fig 1D).

Researchers<sup>10-14</sup> have investigated the outcome of palatally impacted canines that have



**Figure 1.** This young adult female had her palatally impacted maxillary right canine uncovered with the closed technique (A). Instead of being erupted toward the lingual, the crown was pulled laterally through the palatal cortical bone (B,C). Although the bone resorbed through pressure necrosis, no bone was laid down behind the crown (D). As a result, there is a significant periodontal defect on the distal of the lateral incisor and mesial of the canine.

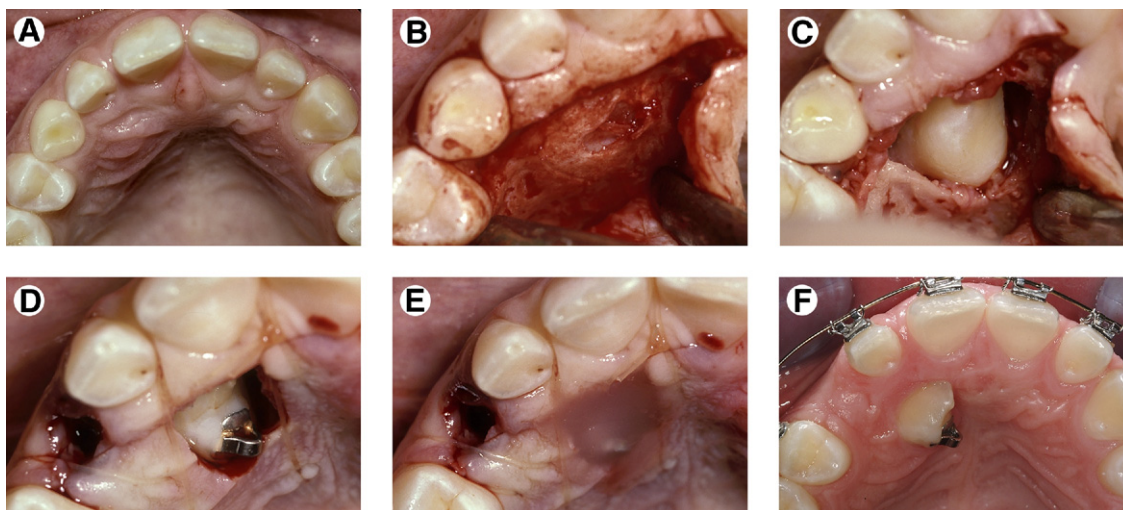
been moved in this manner and show that the bone levels and attachment levels on the distal of the lateral incisor and mesial of the previously impacted canine are located more apically than on the contralateral nonimpacted control canine. In addition, the esthetic outcome of teeth erupted in this manner is also compromised. It is important to remember that the closed eruption technique does not result in less healthy bone and attachment around a previously impacted canine. The problem is with the direction of eruption of the canine crown beneath the palatal tissue. If the closed eruption technique is chosen, then the tooth should first be erupted lingually and then laterally, so it will not compromise the bone levels or cause root resorption of the lateral incisor.

### Preorthodontic Exposure and Autonomous Eruption

Another option for treating a palatally impacted maxillary canine is to surgically uncover the tooth and allow it to erupt autonomously before beginning orthodontic treatment.<sup>2,15</sup> With this procedure, a mucoperiosteal, envelope flap is elevated starting apical to the gingival sulcus on

the lingual surfaces of the maxillary lateral and central incisors in the area of the palatally impacted tooth (Fig 2A, B). Once the flap has been elevated, there is typically a thin layer of bone covering the lingual surface of the canine crown (Fig 2B). This bone can be removed with either a curette or a handpiece and bur. Sufficient palatal bone should be removed down to the level of the cemento-enamel junction (Fig 2C).

Then, a bracket or cleat is bonded to the lingual surface of the canine crown (Fig 2D). The flap is repositioned over the tooth and a small hole is made in the gingival tissue over the canine crown, so the tooth will have no impediment to erupting autonomously. This open surgical defect is covered with a dressing that is mechanically attached to the lingual bracket or cleat (Fig 2E). Then, this tooth is allowed to erupt. With this technique, if sufficient bone is removed, the palatally impacted canine will typically erupt autonomously to the level of the occlusal plane within 6 to 9 months (Fig 2F). Then, the canine can be moved laterally toward the alveolar ridge. During this type of movement, the root is moving through the bone facilitated by the surrounding periodontal membrane.



**Figure 2.** This 14-year-old female adolescent had a palatally impacted maxillary right canine (A). An envelope mucoperiosteal flap was elevated about three millimeters apical to the lingual margins of the maxillary lateral and central incisors (B) before placement of orthodontic appliances. The crown of the impacted tooth was exposed with a curette (C), a cleat was bonded to the lingual surface of the crown (D), and a light-cured dressing was secured to the tooth (E). After about 6 months, the canine had erupted autonomously (F) and the remaining orthodontic appliances were placed to help facilitate moving the canine laterally. (Color version of figure is available online.)

## Discussion

There are several advantages to preorthodontic uncovering and autonomous eruption of a palatally impacted maxillary canine. First, no fixed or removable orthodontic mechanics are necessary to erupt the canine. If the bone and gingiva are removed from over the canine crown, it will erupt on its own into the palate. In fact, it has been our experience that the canine crown will erupt toward the center of the palate and away from the lateral and central incisor roots. This is advantageous, because researchers have shown that when the canine crown is positioned near the lateral and central incisor roots, root resorption well into the dentin could have already occurred.<sup>16-18</sup> As the crown of the canine erupts away from the lateral and central roots, reparative cellular cementum will be laid down along the root surface.<sup>19</sup>

A second advantage to preorthodontic uncovering and autonomous eruption of the palatally impacted canine is that the surgery can be performed during the mixed dentition, before orthodontic therapy begins. This sequencing before orthodontic bracketing allows for shorter time in orthodontic appliances because the brackets are not typically placed until the canine has completely erupted into the palate. Our treatment times for patients treated in this manner have been reduced substantially compared with traditional treatment times for patients with palatally impacted canines.<sup>20</sup>

A third advantage to preorthodontic uncovering is that the bone and attachment adjacent to teeth erupted in this manner is healthier compared with closed eruption and dragging the canine crown laterally through the bone. In a retrospective evaluation of more than 20 patients treated with the preorthodontic uncovering technique,<sup>21</sup> we found that the bone levels and sulcus depths on the mesial and distal the previously impacted canine and adjacent lateral incisor and first premolar were similar to the contralateral nonimpacted control canine. In a previous study we evaluated the closed eruption technique<sup>11</sup> and we typically observed crestal bone loss and deeper sulcus depths adjacent to canines that had been moved laterally through the bone using the closed technique.

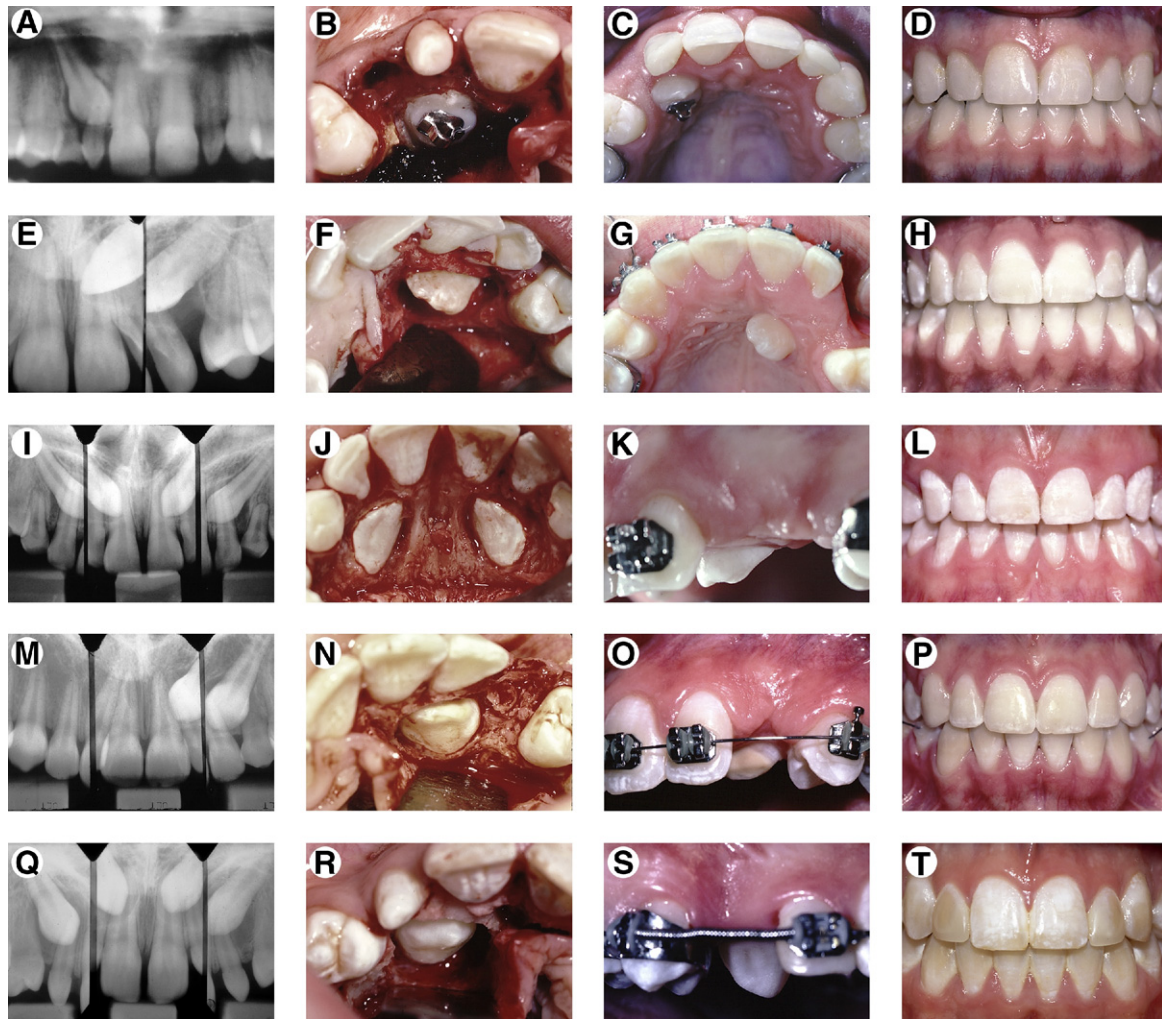
Why don't palatally impacted canines simply erupt without surgical intervention? Why would

they erupt spontaneously when the bone and tissue are removed? I have often wondered about the phenomenon of autonomous eruption. I believe that when the canine crown becomes displaced ectopically lingual to the lateral incisor root the expanding follicle simply does not have the ability to penetrate the somewhat thicker palatal cortical bone and the much thicker palatal gingival tissue. This seems to be the likely explanation, because when we remove these impediments to tooth eruption, the canines will always erupt into the palate and away from the adjacent teeth.

A common criticism of preorthodontic uncovering is that a hole in the gingiva over the crown remains after the surgery. It is assumed that this tissue wound would produce pain and morbidity for the young orthodontic patient. This has not been our experience. First, Gharaibeh and Al-Nimri,<sup>22</sup> when comparing open versus closed techniques for uncovering palatal impactions, have shown that there was no difference in pain response between these 2 techniques. Second, we typically bond a cleat or bracket to the lingual surface of the canine to mechanically secure a dressing to the tooth. This light-cured dressing covers the wound and allows the gingiva to reform up to the wound margins, but prevents bone and tissue from growing over the exposed crown. We do not remove this dressing for perhaps 3 to 4 months, after the tooth has substantially erupted. At that time, the previous wound has healed, the gingival margin has developed around the erupting crown, and the dressing is no longer needed. In fact we will typically remove the bracket as well as the dressing at this time because the lingual bracket does not afford the correct attachment to the tooth when it is time to move the root laterally. At that time, we will place a bracket on the labial surface to move the tooth laterally.

Another common question regarding this technique is whether the permanent canine will erupt if it is horizontally impacted and not oriented toward its normal path of eruption. In the consecutive series of patients illustrated in [Figure 3](#) of this article, the second and third cases illustrate nearly horizontally impacted maxillary canines. In both cases, no orthodontic treatment was begun until the impacted teeth had erupted sufficiently into the palate. Because the teeth were horizontally impacted, the eruption process lasted for almost 1 year. But the teeth did





**Figure 3.** This figure shows five consecutively treated patients who had their palatally impacted maxillary canines (A, E, I, M, Q) uncovered "before" placement of orthodontic appliances (B, F, J, N, R). In all cases, the impacted canines erupted autonomously (C, G, K, O, S) and did not require any vertical forces to move them into the oral cavity. After the completion of orthodontics, it is difficult to determine which teeth had been previously impacted (D, H, L, P, T). (Color version of figure is available online.)

erupt and did not require additional uncovering or eruptive mechanics. The completed results in both cases show permanent canines that blend in nicely with the adjacent tissues.

We have also attempted preorthodontic uncovering of palatally impacted canines in adults. Although we have had some success in seeing these teeth erupt spontaneously in young adults, the eruption process is much slower. Also, for adults older than 30 years of age, we prefer to uncover the palatally impacted canine, erupt it actively into the palate using a palatal spring, followed by lateral movement of the canine root

into the dental arch. However, even in these cases, occasionally even though the canine root may be mobile, it will not erupt and must be extracted.<sup>23</sup>

Why do impacted canines in adults respond much more slowly? Although there are no studies documenting the integrity and structure of the periodontal ligament of unerupted teeth, we think the periodontal ligament around an unerupted tooth could undergo disuse atrophy and therefore be less responsive to preorthodontic uncovering. Perhaps it simply takes longer to create a responsive periodontal ligament in a

tooth that has been buried in the alveolus for several decades. Future research should focus on documenting the status of the periodontal ligament around unerupted/impacted teeth in adults to determine if this theory is correct.

We have been pleased with the improved esthetics around the unilateral palatally impacted canines that have been uncovered and allowed to erupt autonomously.<sup>21</sup> In fact, in our recent study, panelists were asked to compare the right and left canines after orthodontic treatment to determine whether there were esthetic differences between the previously impacted and non-impacted control canines. The results showed that panelists could not routinely discern esthetic differences between impacted and nonimpacted canines. In our previous study<sup>11</sup> that evaluated the esthetic appearance of canines uncovered with the closed technique and lateral movement of the canine crown through the bone, the impacted tooth was identified 75% of the time, because of the unesthetic sequelae.

## Conclusions

In conclusion, this article has described and documented the periodontal and esthetic results of a simplified method for dealing with palatally impacted maxillary canines. The technique, the rationale, and the outcome of preorthodontic uncovering and autonomous eruption have been elucidated. The research evidence documenting the esthetic and periodontal responses to this type of treatment have been presented. We believe that preorthodontic uncovering and autonomous eruption of palatally impacted maxillary canines provides a simplified, predictable, biologically sound, less complicated, and more esthetic outcome for young patients with palatal canine impactions, and can reduce the treatment time substantially because the orthodontic brackets in these cases are not placed until the canine has erupted into the palate.

## References

1. Bass T: Observations on the misplaced upper canine tooth. *Dent Practitioner* 18:25-34, 1967
2. Johnston WD: Treatment of palatally impacted canine teeth. *Am J Orthod* 56:589-596, 1968
3. Dachi S, Howell F: A survey of 3874 routine full mouth radiographs. *Oral Surg Oral Med Oral Pathol* 14:1165-1169, 1961
4. Ericson S, Kurol J: Radiographic assessment of maxillary canine eruption in children with clinical signs of eruption disturbances. *Eur J Orthod* 8:133-140, 1986
5. Ericson S, Kurol J: Early treatment of palatally erupting maxillary canines by extraction of the primary canines. *Eur J Orthod* 10:283-295, 1988
6. Jacobs SG: The impacted maxillary canine. Further observations on aetiology, radiographic localization, prevention/interception of impaction, and when to suspect impaction. *Aust Dent J* 41:310-316, 1996
7. Olive RJ: Orthodontic treatment of palatally impacted maxillary canines. *Aust Orthod J* 18:64-70, 2002
8. Leonardi M, Armi P, Franchi L, et al: Two interceptive approaches to palatally displaced canines: A prospective longitudinal study. *Angle Orthod* 74:581-586, 2004
9. Becker A, Zilberman Y: The palatally impacted canine: A new approach to treatment. *Am J Orthod* 74:422-429, 1978
10. Becker A, Kohavi D, Zilberman Y: Periodontal status following the alignment of palatally impacted canine teeth. *Am J Orthod* 84:332-336, 1983
11. Woloshyn H, Artun J, Kennedy DB, et al: Pulpal and periodontal reactions to orthodontic alignment of palatally impacted canines. *Angle Orthod* 64:257-264, 1994
12. Hansson C, Rindler A: Periodontal conditions following surgical and orthodontic treatment of palatally impacted maxillary canines: A follow-up study. *Angle Orthod* 68:167-172, 1998
13. Ling K, Ho C, Kravchuk O, et al: Comparison of surgical and non-surgical methods of treating palatally impacted canines. II Aesthetic outcomes. *Aust Orthod J* 23:8-15, 2007
14. Zasciurinskiene E, Bjerklind K, Smaliliene D, et al: Initial vertical and horizontal position of palatally impacted maxillary canine and effect on periodontal status following surgical-orthodontic treatment. *Angle Orthod* 78:275-280, 2008
15. Clark D: The management of impacted canines: Free physiologic eruption. *J Am Dent Assoc* 82:836-840, 1971
16. Ericson S, Kurol J: Resorption of maxillary lateral incisors caused by ectopic eruption of the canines. A clinical and radiographic analysis of predisposing factors. *Am J Orthod Dentofac Orthop* 94:503-513, 1988
17. Ericson S, Kurol J: Incisor root resorptions due to ectopic maxillary canines imaged by computerized tomography: A comparative study in extracted teeth. *Angle Orthod* 70:276-283, 2000
18. Liu D, Zhang W, Zhang Z, et al: Localization of impacted maxillary canines and observation of adjacent incisor resorption with cone-beam computed tomography. *Oral Surg Oral Med Oral Pathol Oral Radiol Endod* 105:91-98, 2008
19. Owman-Moll P, Kurol J, Lundgren D: Repair of orthodontically induced root resorption in adolescents. *Angle Orthod* 65:403-408, 1995
20. Stewart J, Heo G, Glover K, et al: Factors that relate to treatment duration for patients with palatally impacted maxillary canines. *Am J Orthod Dentofac Orthop* 119:216-225, 2001

21. Schmidt A, Kokich V: Periodontal response to early uncovering, autonomous eruption, and orthodontic alignment of palatally impacted maxillary canines. *Am J Orthod Dentofac Orthop* 131:449-455, 2007
22. Gharaibeh T, Al-Nimri K: Postoperative pain after surgical exposure of palatally impacted canines: Closed-eruption versus open-eruption, a prospective randomized study. *Oral Surg Oral Med Oral Pathol Oral Radiol Endod* 106:339-342, 2008
23. Becker A, Chaushu S: Success rate and duration of orthodontic treatment for adult patients with palatally impacted maxillary canines. *Am J Orthod Dentofac Orthop* 124:509-514, 2003