

## Interrelationship of Orthodontics with Periodontics and Restorative Dentistry

*Vincent G Kokich and Vincent O Kokich*

**T**oday, orthodontics is not just for children and adolescents. For the past two decades, increasing numbers of adults have been referred to orthodontists to correct their malocclusions. Adults are usually wonderful patients, because they are cooperative, clean their teeth, show up for appointments, and are appreciative of the clinician's efforts. However, adults may have problems other than malposed teeth and jaws that make their orthodontic treatment more challenging. Whereas children and adolescents have intact dentitions with few restorations and a healthy periodontium, adults may have old failing restorations, edentulous spaces, abraded teeth, periodontal bone defects, gingival level discrepancies, hopeless teeth, and a variety of other restorative and periodontal problems that could compromise the orthodontic result. In the past, orthodontists made all the decisions about the treatment plan for a child or adolescent. However, in the compromised adult malocclusion, a team of orthodontist, oral and maxillofacial surgeon, periodontist, endodontist, and restorative dentist must interact to make prudent treatment decisions for the patient.

This chapter will elucidate the dilemmas encountered in the orthodontic patient with multidisciplinary problems, and describe a series of 10 guidelines to help manage the interrelationship of orthodontics with periodontics and restorative dentistry.

### Generate Realistic Treatment Objectives

The first step in any type of dental therapy is to establish the treatment objectives. It is impossible to achieve the correct end result if the appropriate goals or objectives have not been identified before treatment. In nonrestored, adolescent patients with complete dentitions, orthodontic treatment objectives tend to be idealistic. After all, if patients have intact dentitions without restorations, it is appropriate to expect that ideal esthetic and occlusal treatment should be attainable, if the patient cooperates. Because of this tendency, most orthodontists are trapped into applying these same idealistic treatment objectives to adult patients with missing teeth, abraded teeth, old restorations, or other restorative and periodontal complications. Idealistic treatment objectives may not be appropriate for the ortho-perio-restorative patient. For these patients, it is important to establish realistic, not idealistic, treatment objectives. Realistic treatment objectives generally should be economically realistic, occlusally realistic, periodontally realistic, and restoratively realistic.<sup>1</sup>

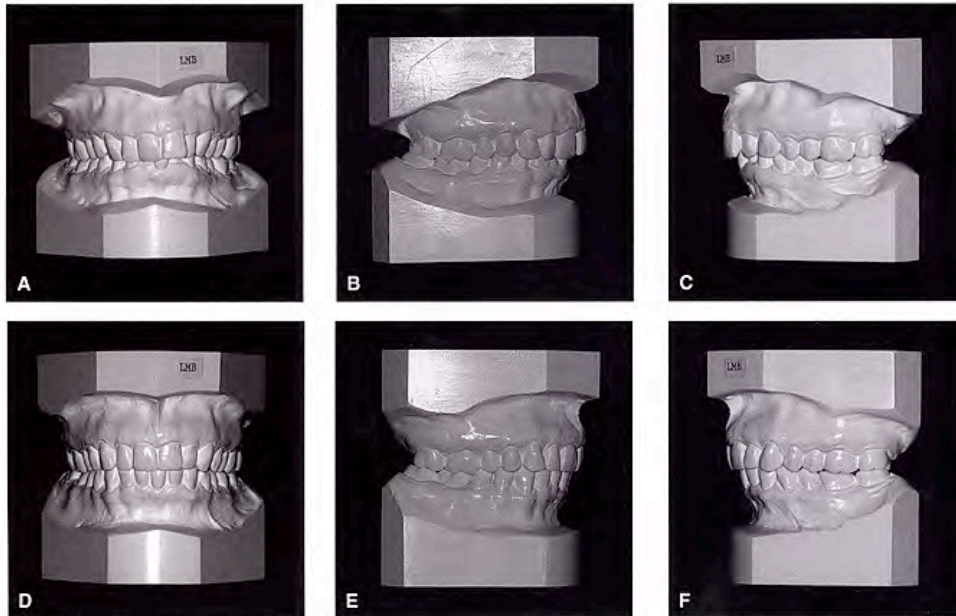
If an adult orthodontic patient is missing several teeth, the edentulous spaces created during orthodontic treatment will require restoration after the removal of the orthodontic appliances. Several restorative alternatives may exist for

replacing the missing teeth. The cost of these restorative treatment plans may differ widely. Furthermore, each type of restoration may require slightly different tooth positioning. Therefore, it is mandatory for the team to establish a treatment plan that is economically realistic for each patient. If the team fails to establish economically realistic objectives, the patient might not complete the restorative treatment following orthodontic therapy.

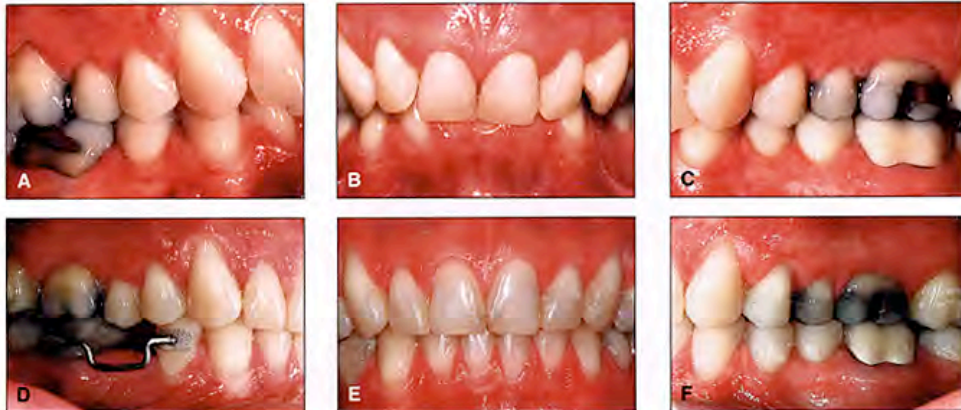In young patients it is important to establish ideal occlusal objectives, such as an Angle Class I canine relationship with normal overbite and overjet relationships. When planning occlusal treatment for young patients, the orthodontist is missing two critically important pieces of information: (1) because of their young age, there is no occlusal history; and (2) the orthodontist unfortunately cannot predict the future habits or problems that a young patient will encounter during his/her lifetime. Therefore, in these situations it is appropriate for the orthodontist to create an ideal occlusion. However, in the adult patient, orthodontists often overlook the most valuable piece of information, i.e. the patient's dental history. Has the

adult patient demonstrated parafunctional occlusal habits, evidence of temporomandibular disorders, cracked teeth or restorations, wear facets, abraded incisors, or other signs and symptoms that would suggest that the treatment plan should alter the existing occlusion? Not all existing occlusions in adult patients need to be corrected to an adolescent ideal (Fig. 18-1). In all adult patients, the dental history, as well as the future restorative requirements, play a greater role in determining the final occlusion (Fig. 18-2). For example, it may not be necessary to correct posterior crossbites in adults who have no occlusal interferences and no shift of the mandible, and who can be restored adequately in a posterior crossbite relationship (Fig. 18-3).

If patients are missing many teeth, it may not be prudent to establish idealistic occlusal objectives. An ideal Angle Class I posterior occlusion is achievable in a patient with a complete nonrestored, nonabraded dentition. However, if the patient is missing several teeth and will require extensive restorative treatment after orthodontics, it may be more prudent to establish treatment objectives that are occlusally realistic for the specific patient. For example, if the patient



**Fig. 18-1** This 68-year-old female had a deep anterior overbite (A) with Class I molar and canine relationships on the right (B) and Class II molar and canine relationships on the left (C). She had no temporomandibular joint symptoms and a healthy periodontium. D Treatment objectives included alignment of teeth in both arches and reduction of the deep overbite. Because of an anterior tooth-size discrepancy, proclined mandibular incisors, and upright maxillary incisors, her treatment objectives did not include correction of the Class II molar and canine relationships on the left. E and F At the end of treatment all treatment objectives were achieved, including maintaining the original posterior occlusal relationships.



**Fig. 18-2** This 52-year-old male had a bilateral Class II, Division 2 malocclusion with a deep anterior overbite (A), retroclined maxillary incisors (B and C), a missing mandibular second premolar, and a mandibular dental midline that deviated to the right. The patient had no temporomandibular joint symptoms, and the periodontium was healthy. Treatment objectives included reduction of the deep overbite (D), opening space for the missing premolar, correction of the dental midline, and establishing normal overjet. Because of the inclination of the anterior teeth and the anterior tooth-size relationships, a Class I canine relationship was established on the right (E), and a Class II relationship was maintained on the left (F). The objectives were achieved without correcting the Class II canine relationship on the right side.

will require extensive restorations after orthodontic treatment, the restorative dentist may suggest altering an Angle Class I occlusion to facilitate restoration of the teeth (Fig. 18-4). It is critical for the orthodontist to be aware of these alterations before bracket placement to achieve an occlusally realistic relationship for the restorative patient.<sup>1</sup>

A common occlusal treatment objective in children is to align the marginal ridges of the posterior teeth in order to produce a uniform vertical relationship between the maxillary and mandibular posterior teeth.<sup>2</sup> In a nonabraded, periodontally healthy adolescent dentition, aligning the marginal ridges helps to establish even contact of the posterior teeth, when they are brought into occlusion. However, in the adult patient with interproximal bone loss and uneven wear of the posterior teeth, the marginal ridges are poor guides for positioning the posterior teeth.<sup>3</sup> In these patients, the periodontal objectives outweigh the occlusal objectives. The role of the orthodontist in the periodontal patient is to level the bone during orthodontic treatment. This could require equilibration and reshaping of the posterior teeth in order to maximize the occlusal contacts. In most of these situations, the teeth that have been equilibrated will require restoration anyway after orthodontic treatment.

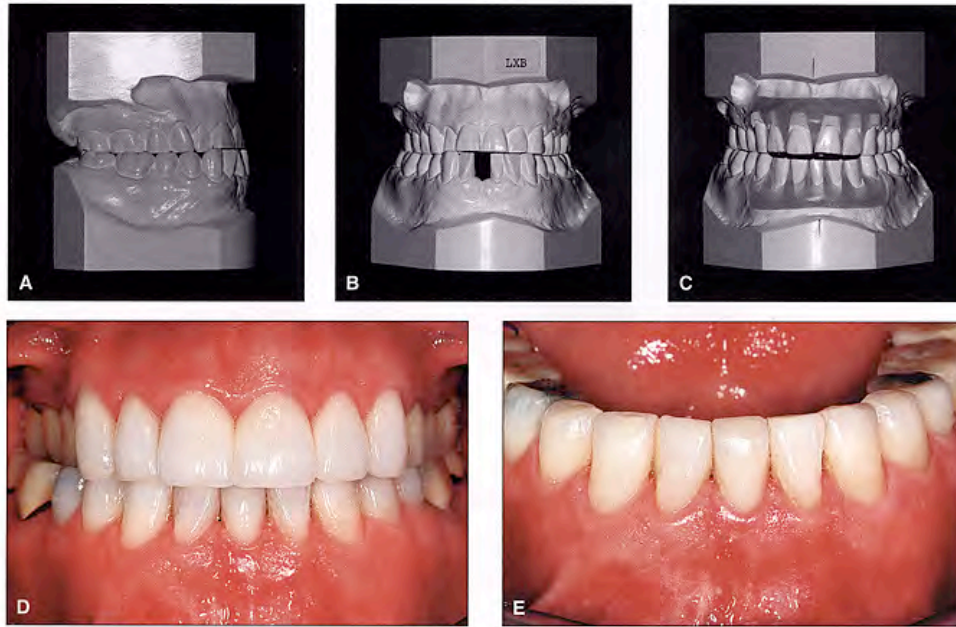
Certain types of restorations require specific positioning of adjacent or opposing teeth. As a result, orthodontists must not establish idealistic treatment objectives for patients who will require extensive restoration. If teeth are

worn or abraded, it may be more important to position the teeth in a restoratively realistic location to facilitate the appropriate restoration.

### Create the Vision

After an orthodontist has treated several hundred adolescent patients with complete dentitions, it is easy for him/her to visualize or foresee the final orthodontic result before beginning treatment. However, some adult orthodontic patients may be missing several permanent teeth. If teeth have been absent for several years, the remaining teeth may have drifted. In other situations it may be necessary to position teeth in unusual situations. These patients may require a combination of orthodontics and restorative dentistry to rehabilitate their occlusion. In these patients it may be difficult for the orthodontist to visualize or foresee the final result as he/she may not be aware of the restorative requirements or the eventual restorative treatment plan. Similarly, it may be difficult for the restorative dentist to visualize the final result as he/she may be unaware of the orthodontic possibilities.

However, it is possible to predetermine the final occlusal and restorative outcome by completing a diagnostic wax setup for these types of patients. A diagnostic setup is mandatory for any patient who is missing multiple permanent teeth<sup>4</sup> and will require a combination of orthodontics and restorative dentistry (see Fig. 18-4). In addition,



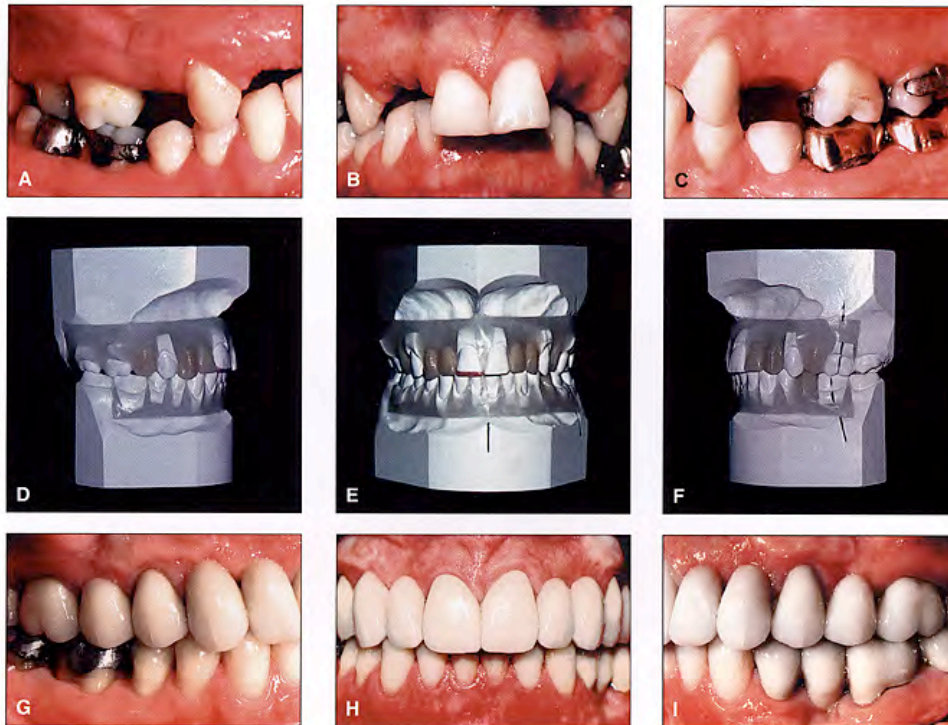
**Fig. 18-3** This 57-year-old male had a Class III end-to-end posterior occlusion with an anterior dental crossbite (A), a missing mandibular incisor (failed endodontic therapy), severe wear of the maxillary incisors, and bilateral posterior dental crossbites with no lateral shift of the mandible (B). He had no temporomandibular joint symptoms, and the periodontium was healthy. Treatment objectives included correction of the anterior crossbite to create an overjet to restore the abraded maxillary incisors. Correction of the bilateral dental crossbites was not a treatment objective. C A diagnostic setup showed that the mandibular space could be closed to create restorative space. The final photographs of the D restored maxillary and E mandibular incisors show that correction of the posterior crossbites was not necessary to achieve the restorative objectives.

patients who will have implants used first for orthodontic anchorage and later for restorative abutments will require a diagnostic setup<sup>5</sup> to position the implants properly prior to the beginning of orthodontics (Fig. 18-5). The orthodontist should never make the restorative decisions, but should consult with the restorative dentist when planning treatment for these types of patients. In that way, the orthodontist may reposition the teeth to simulate realistic orthodontic objectives that will be in harmony with the patient's restorative requirements. Both practitioner and patient can visualize the result. The diagnostic wax setup is the blueprint for treatment in these types of patients.

A diagnostic wax setup is also necessary for patients who have unusual combinations of missing teeth, and in whom the orthodontist is planning to substitute one tooth for another. For example, if a patient were missing maxillary lateral incisors, and the orthodontist were planning canine substitution, a diagnostic wax setup would be mandatory to determine if the occlusion will fit properly

and if the teeth can be shaped accordingly. Occasionally, a patient is missing a central incisor,<sup>6</sup> and a treatment option could be to restore the opposite lateral incisor as a central incisor in order to avoid an implant or fixed bridge (Fig. 18-6). A diagnostic wax setup would be necessary to determine if the tooth arrangement will be both esthetic and functional.

Finally, adult malocclusions with significant mandibular incisor crowding occasionally are treated with extraction of a single mandibular incisor.<sup>7</sup> This type of extraction improves longterm stability, easily eliminates the crowding, simplifies the mechanics, preserves facial esthetics, and improves periodontal health in certain adults. However, before extracting the incisor, the orthodontist must know if the occlusion will fit properly, especially in the canine and incisor region (Fig. 18-7). A diagnostic wax setup will give the clinician the appropriate information to make the correct decision when planning incisor extraction in crowded adult malocclusions.



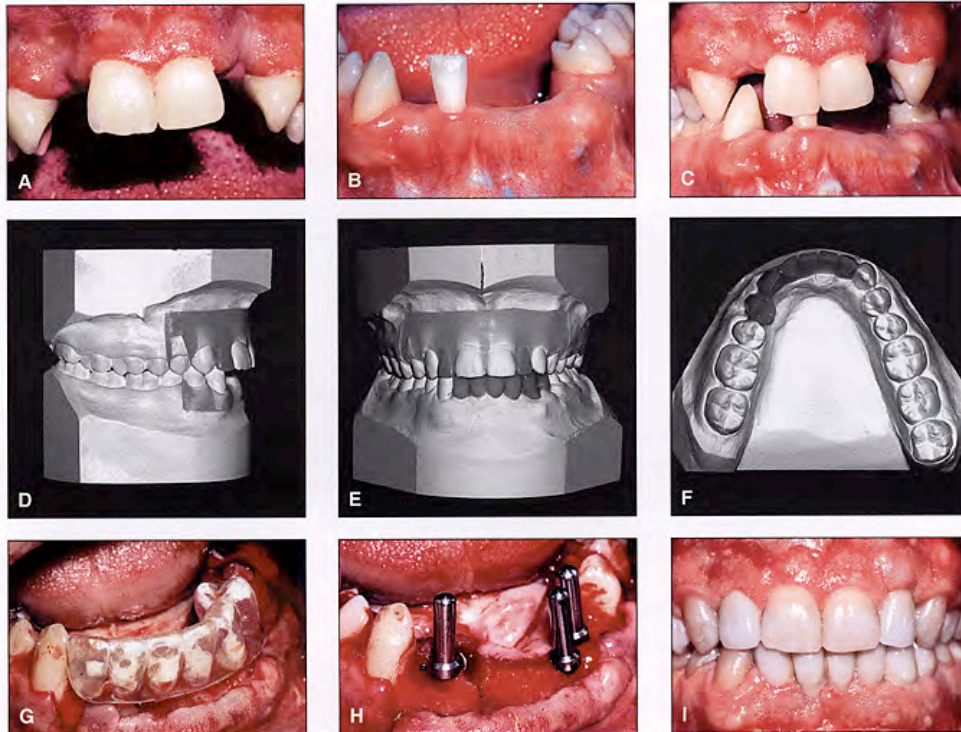
**Fig. 18-4** A-C This 32-year-old female had a Class II, Division 1 malocclusion with a deep anterior overbite. She was congenitally missing both maxillary lateral incisors and all four maxillary premolars. The restorative dentist wanted the maxillary canines positioned in the first premolar positions in order to restore the maxillary arch with three segments of fixed restorations connected at the canines with a semirigid connector. D-F A diagnostic wax setup provided the guide for the orthodontist to position the canines in their appropriate position. G-I After the final restorations were placed, the widths of the pontics and abutments in the maxillary arch were functionally and esthetically correct, because the vision was created with the diagnostic setup.

### Establish the Sequence of Treatment

Many orthodontic–restorative patients also require adjunctive periodontal therapy and orthognathic surgery. As the number of dentists involved in a patient’s treatment increases, the complexity of the treatment also increases. In many of these situations, different specialists must interact at varying intervals during the patient’s overall treatment. Therefore, the team of specialists must not only establish a realistic plan of treatment, but should also determine the sequence of interaction between the different specialists (Fig. 18-8).

This critical step is often overlooked. It requires that the team members meet to discuss the patient’s treatment

before the initiation of therapy. After the sequence of intervention has been determined, it should be recorded by one of the clinicians.<sup>1</sup> A copy of the treatment sequence should be given to each of the participating dentists and to the patient. Then, at any time during treatment, any of the team members can review the sequence, determine his/her point of interaction, and feel secure that the plan is proceeding properly. In addition, the patient is aware of the pathway toward completing treatment. The importance of this step in interdisciplinary treatment cannot be overemphasized. The success in treating a patient with complex restorative, periodontal, orthognathic, and orthodontic problems is dependent on not only the correct plan of treatment, but also the correct sequence of interaction among different practitioners during the course of treatment.



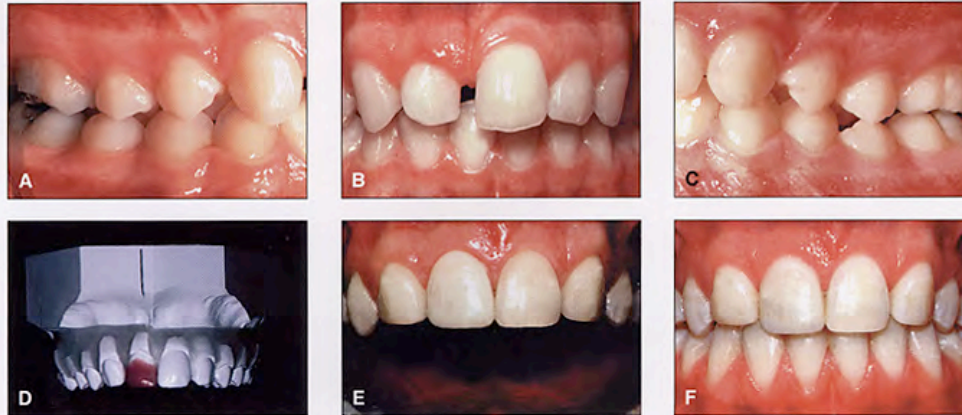**Fig. 18-5** This 24-year-old male was the victim of a robbery during which he was shot in the face and lost **A** his maxillary lateral incisors and **B** most of his mandibular anterior teeth. The restorative plan involved single-tooth implants in the maxilla and an implant-supported bridge in the mandible to replace the missing teeth. The implants were also to be used as anchors to intrude the mandibular right canine and first premolar. **D-F** A diagnostic setup was constructed to determine the appropriate implant position prior to orthodontics. A placement guide (**G**) was constructed from the setup so the surgeon could guide the placement of the implants (**H**). **I** After orthodontics, the same implants that were used as orthodontic anchors were used to restore the missing teeth.

### Identify Who Will Correct the Periodontal Defects

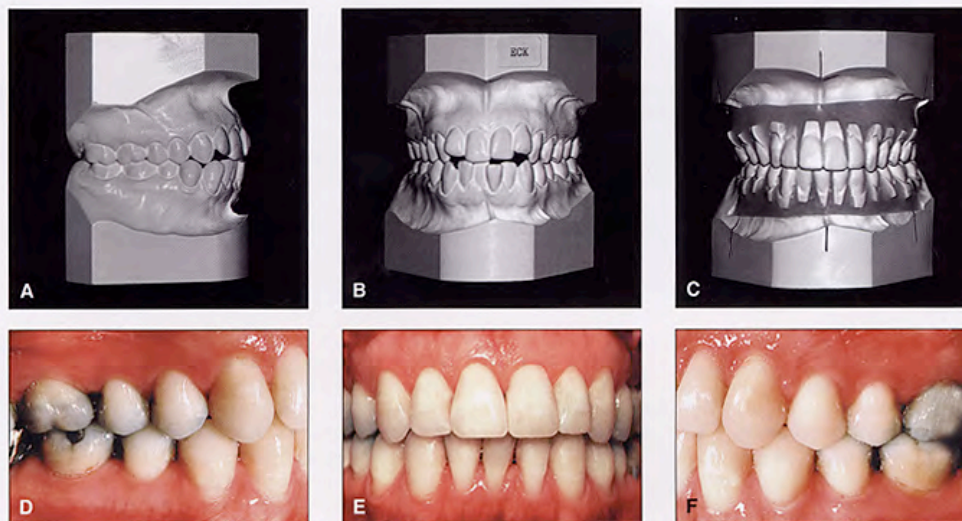
Many adult orthodontic patients have underlying periodontal defects that will need to be resolved before, during, or after the orthodontic therapy. It is mandatory that the orthodontist and periodontist discuss the management of these patients to determine who will be responsible for correcting the periodontal problems.<sup>8</sup> These problems are generally divided into two categories: soft tissue or gingival discrepancies; and hard tissue or bony defects. Gingival discrepancies include recession, lack of attached gingiva, and open gingival embrasures. Bony alveolar defects include interproximal craters, one-, two-, and three-wall

defects, furcation defects, and generalized or localized horizontal bone loss secondary to periodontal disease. Each of these defects must be discussed prior to the initiation of orthodontic bracketing to determine who will be responsible for correcting them.

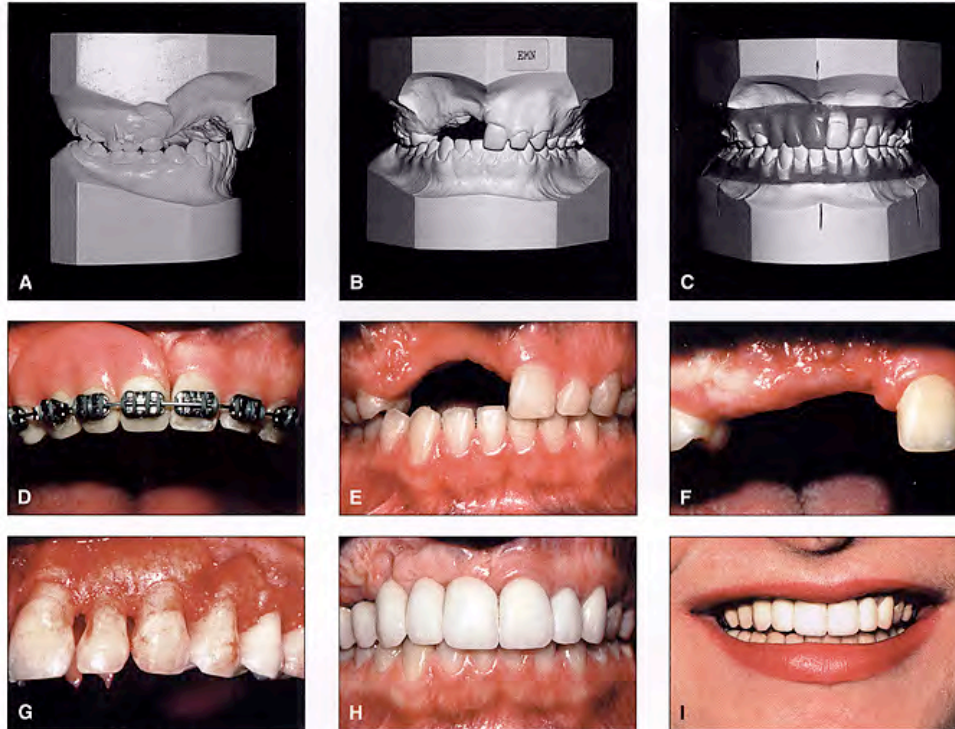
Gingival recession and inadequate attached gingiva often will require the placement of a connective tissue graft. In some cases it is best to perform the grafting prior to orthodontic treatment. This is especially important when the adult patient has pre-existing recession and dental crowding, and will be treated without the extraction of teeth.<sup>3</sup> If there is a dehiscence labial to the tooth, and recession has already occurred, it could get worse during orthodontic treatment. Therefore, the periodontist will



**Fig. 18-6 A-C** This 14-year-old female lost her maxillary right central incisor in a horse-back riding accident as a child. No treatment was done at the time, and the edentulous space had closed partially. She had a bilateral Class II malocclusion, no crowding in either dental arch, and a good facial profile. Although various treatment options were considered initially, the final plan involved extraction of the left lateral incisor, restoration of the right lateral as a central incisor, and bilateral canine substitution. **D** A diagnostic wax setup was necessary to confirm that this plan would satisfy the objectives. The setup helped the orthodontist to achieve an excellent **E** esthetic and **F** occlusal result.



**Fig. 18-7** This 32-year-old female had a bilateral Class I occlusion (**A**) with mild crowding of the maxillary teeth and moderate crowding of the mandibular incisors (**B**). **C** A diagnostic setup was constructed to determine if extraction of a mandibular incisor would eliminate the crowding and permit satisfactory overbite and overjet. **D-F** The setup was invaluable in creating the vision and allowing the orthodontist to achieve a well-interdigitated occlusal result.



**Fig. 18-8** **A** and **B** This 14-year-old female lost her maxillary anterior teeth in a water skiing accident, which left a huge void in the maxillary alveolus. **C** A diagnostic setup was constructed to create the vision for the practitioners and patient. Several treatment options were discussed, but the final plan involved orthodontics (**D** and **E**), segmental maxillary jaw surgery, sagittal split ramus osteotomy, autogenous soft tissue ridge grafting (**F**), crown lengthening (**G**), provisionalization, and final restoration (**H** and **I**). Because of the complexity of the treatment plan, the four practitioners on her team established the sequence of treatment before beginning therapy. Having the flow chart or treatment sequence facilitated the smooth treatment of this complicated case by keeping all practitioners aware of the timing of each of the steps along the way.

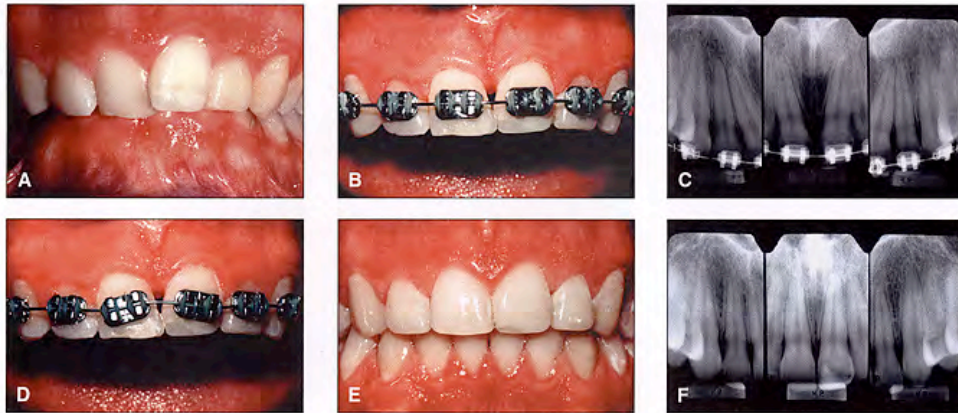
probably place a connective tissue graft prior to the orthodontic therapy to insure that the recession will not progress, and to cover the exposed root with gingiva.

Open gingival embrasures often occur during orthodontic therapy. If not corrected, these dark spaces between the teeth create an esthetic compromise after orthodontic therapy. The presence of a space above the central incisor interproximal contact may be caused by one of three factors.<sup>9</sup> The first possible cause is diverging roots of the maxillary central incisors. This is usually the result of improper bracket placement (Fig. 18-9). In patients with overlapping and abraded maxillary central incisors, brackets may be placed inadvertently at an angle that is not perpendicular to the long axis of the central incisor. As the teeth are aligned, the roots may diverge distally.

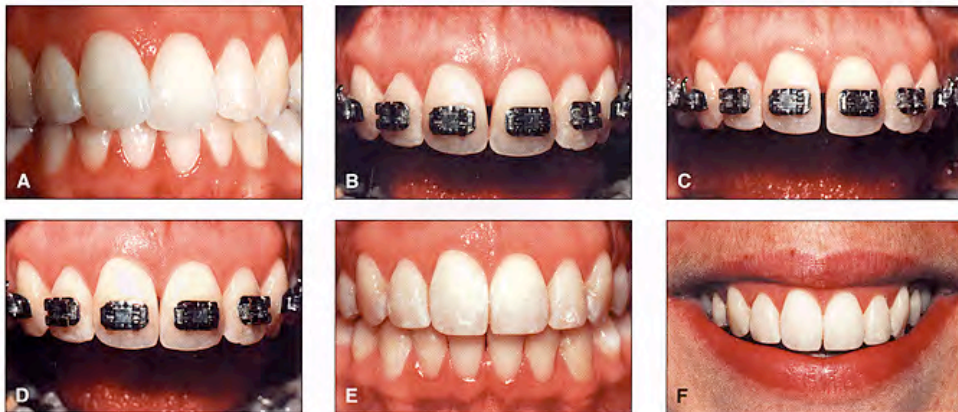
To identify this cause, the clinician should evaluate a periapical radiograph. If the roots diverge, the brackets should be removed and repositioned with the bracket slots perpendicular to the long axes of the roots. As the roots align, the interproximal contact lengthens and moves apically toward the papilla. Usually, the distal-incisal corners of the centrals also move apically. This reflects the amount of incisal wear that may have occurred before orthodontic treatment. These teeth usually require an incisal restoration to restore proper incisal contour.

A second possible cause of space above the interproximal contact of the central incisors is abnormal tooth shape.<sup>9</sup> In some patients, the crowns of the centrals are much wider at the incisal edges than at the cervical region (Fig. 18-10). In these situations the contact between the incisors is





**Fig. 18-9** **A** This young adult male had a Class II deep overbite malocclusion with mild crowding in both arches. **B** During alignment of his overlapped maxillary incisors, an open embrasure developed between the maxillary central incisors. **C** Progress periapical radiographs showed that the central incisor roots were diverted distally, causing the open embrasure. **D** Therefore, the teeth were rebracketed with the bracket slot perpendicular to the long axis of the roots. **E** and **F** This permitted uprighting of the central incisor roots, which moved the contact gingivally and the papilla incisally to close the open embrasure.



**Fig. 18-10** **A** This 28-year-old female had a mildly crowded Class I malocclusion. Four premolars had been extracted early in her life, but no orthodontic treatment had been performed. The objectives were to align the teeth and reduce the overbite. **B** During alignment an open embrasure developed between the central incisors. The papilla height was normal, but the contact between the centrals was too low, due to the triangular shape of the maxillary central incisors. The mesial surfaces of both centrals were reshaped with a diamond disc (**C**), and the space was closed (**D**), moving the contact gingivally toward the normal papilla. **E** and **F** After orthodontics the open embrasure had been eliminated, and the occlusion and esthetics were satisfactory.

located in the incisal 1 mm between the two centrals. This is an unusual contact relationship as the contact should occupy about half the distance between the gingival margin and the incisal edge. One method of correcting this problem is to recontour the mesial surfaces of the central incisors

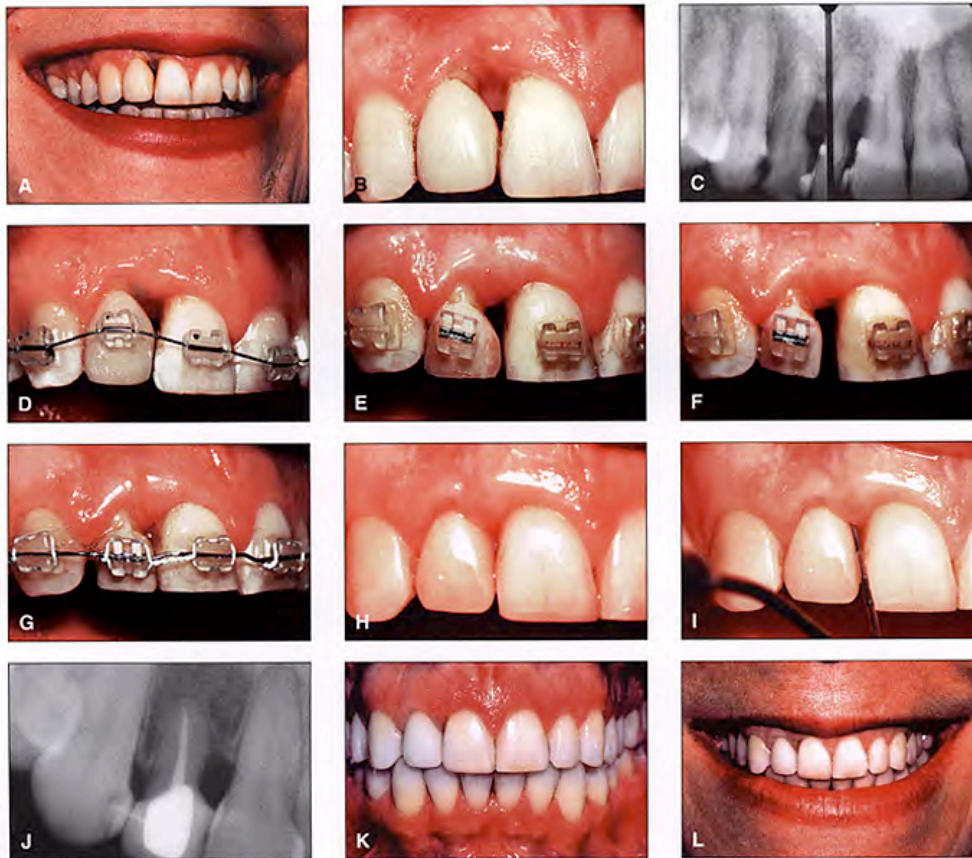and close the space (Fig. 18-10). The other method is to restore the contact with either a composite or porcelain laminate restoration. If recontouring of the tooth will make it too narrow, then restoration is appropriate. In all other cases, recontouring of the teeth and space closure is the

easiest way to correct the open embrasure. The amount of enamel that must be removed from each tooth is equal to half the distance between the mesial surfaces of the incisors at the level of the tip of the papilla. Usually this will be about 0.5–0.75 mm and does not penetrate into the dentin. After this diastema has been created, the space between the teeth is consolidated. As this occurs, the contact lengthens and moves toward the papilla.

In patients with advanced generalized or localized periodontal disease and destruction of the crestal bone between anterior teeth, the papilla may be absent. This produces

an unesthetic large gap after orthodontics. Several methods may be needed to resolve this problem (Fig. 18.11). In some cases, reshaping the adjacent teeth, altering the root angulation, eruption of the adjacent teeth, and restoration will be necessary to move the bone coronally and to squeeze the gingival tissue between the adjacent crowns to establish a papilla between adjacent teeth after orthodontic therapy.

Adult orthodontic patients may also have osseous defects that could compromise the patient's ability to clean his/her teeth adequately and that require correction prior to or during orthodontic therapy.<sup>8</sup> These osseous defects



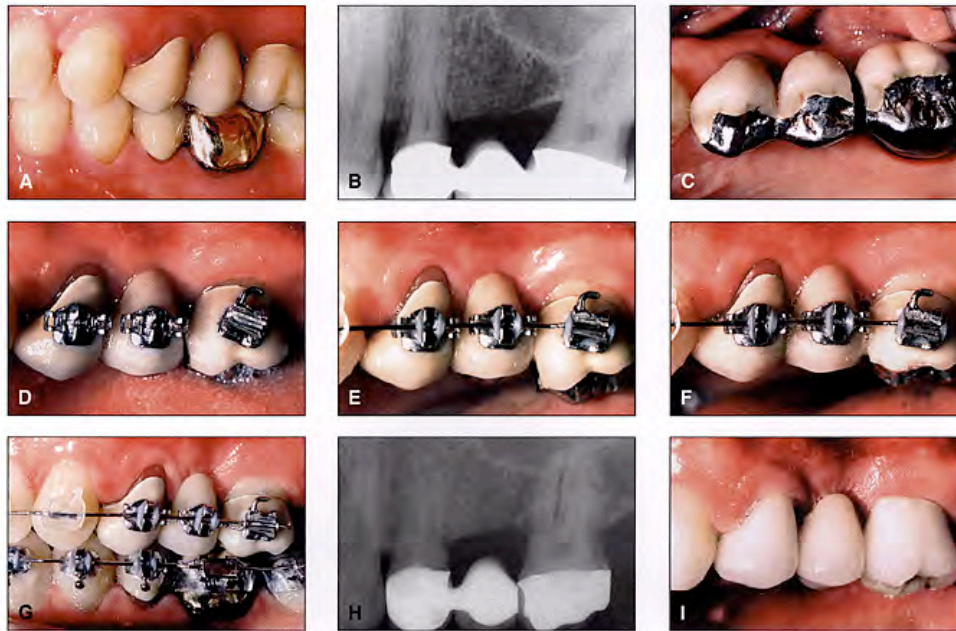
**Fig. 18-11** This adult female had a significant open embrasure between the maxillary right central and lateral incisors (A and B), caused by a periodontal abscess with resultant interproximal bone loss (C). The correction required moving the papilla coronally by D placing brackets nearer the gingival margins of the incisors and E erupting the two teeth. Then, in order to correct the contact problem, the bracket was repositioned (F), the mesial of the lateral was reshaped, and the space was closed (G). A provisional crown was placed after orthodontics (H), and the sulcular depth was reduced significantly (I). J The post-treatment radiograph shows the amount of bone that was created by erupting the tooth incisally. K and L The final restoration looked much more esthetic after the open embrasure had been closed by orthodontics, periodontics, endodontics, and restorative dentistry.

include interproximal craters, one-, two-, and three-wall defects, furcation defects, and horizontal defects. Interproximal craters can be the most volatile intrabony defects in the orthodontic patient. These are two-wall defects, where the remaining walls are the buccal and lingual walls. Attachment loss occurs on the mesial and distal surfaces of the adjacent roots. Orthodontic movement cannot improve interproximal craters.<sup>8</sup> If the crater is mild to moderate, but the patient cannot maintain the area adequately, it may require resective bone removal and recontouring prior to orthodontic bracketing.

*One-wall defects* are treated most efficiently by the orthodontist.<sup>10</sup> In these situations, periodontal pathogenic bacteria have destroyed the attachment on three of the four interproximal walls, leaving one wall remaining. These defects are difficult for a periodontist to manage, because resective surgery could be too destructive, and regenerative therapy is inappropriate. However, orthodontic eruption of the tooth will eliminate the defect (Fig. 18-12). In these situations, the orthodontist must place the bracket more

apically on the facial surface of the crown and perpendicular to the long axis of the root of the tooth. As the tooth erupts, the orthodontist must equilibrate the crown to avoid premature contact with teeth in the opposing arch, and increased mobility of the erupting tooth. The orthodontist should evaluate a progress periapical radiograph to determine when the tooth has erupted sufficiently. When the interproximal bone is flat between adjacent teeth, and the one-wall defect has been eliminated, then the extrusion of the tooth is complete. Most of these erupted and equilibrated teeth will require a crown to cover the dentin that may have been exposed during the eruption process.

*Two-wall defects* are best treated with orthodontics and periodontal surgery.<sup>8</sup> When two walls remain in an interproximal region, and the patient cannot maintain the area, it is difficult for a periodontist to completely resolve the defect with resective or regenerative treatment. These defects often require orthodontic eruption of the affected tooth, followed by crown lengthening to improve the



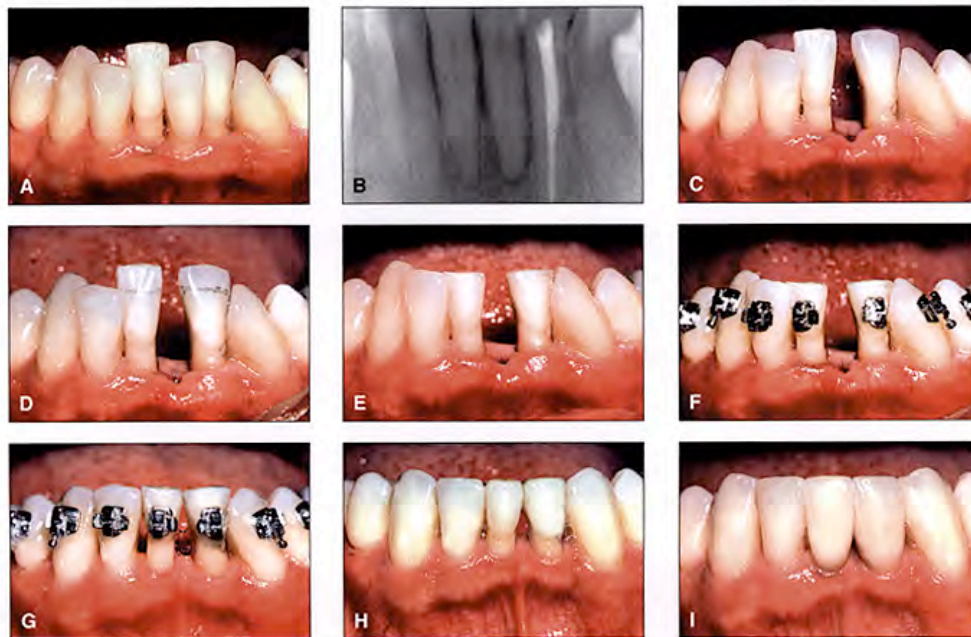**Fig. 18-12** **A** This 43-year-old veterinarian had a 6 mm bleeding pocket on the mesial surface of the maxillary left first molar. This tooth was an abutment for an existing three-unit bridge. **B** The periapical radiograph shows the one-wall defect that was present mesial to the tipped first molar. The treatment plan involved sectioning of the bridge (**C**), placing the molar bracket perpendicular to the long axis of the root (**D**), and inserting an archwire to upright and erupt the tooth (**E**). Because the crown had been overcontoured, the occlusal surface was equilibrated (**F**) to establish satisfactory occlusal contact (**G**). The post-treatment radiograph shows the amount of molar extrusion that was accomplished in order to eliminate the one-wall defect (**H**), so the final bridge could be placed on a periodontally healthy tooth (**I**).

restorability of the tooth. *Three-wall defects* are not resolvable with orthodontics. If the patient cannot maintain a three-wall defect during orthodontic therapy, it must be resolved prior to bracket placement. These defects are generally treated with regenerative therapy, using either autogenous or alloplastic bone grafts in the affected area.<sup>8</sup> Generally, orthodontic tooth movement can begin a short time after placement of the bone graft in order to enhance the fibroblastic and osteoblastic turnover that is necessary to heal the defect and move the adjacent teeth.

Furcation defects are typically divided into three classifications: class 1, 2 and 3. Class 1 furcation defects are typically very shallow and do not enter the molar furcation deeply, and usually are observed or monitored during orthodontic therapy. Class 2 furcation defects extend into the furcation but do not communicate with the opposite side or interproximal region of the tooth. If the patient cannot maintain a class 2 furcation defect, and the tooth is necessary for the occlusal and restorative treatment plan, then the periodontist must treat the furcation prior to orthodontics. Treatment most likely will involve a regenerative approach<sup>8</sup> using membranes to isolate the defect

in order to promote regeneration of the periodontal membrane, while the membrane blocks the ingrowth of the epithelium which would recreate the furcation defect. Class 3 furcation defects are typically not maintainable by patients during orthodontic therapy and decisions about their outcome must be made during the treatment planning process before beginning orthodontics. In the past, hemisection, root amputation, and root separation using orthodontics have been attempted.<sup>3</sup> In some cases these techniques worked nicely. However, today clinicians are more interested in the longterm outcome of treatment and, therefore, most significant class 3 furcations are treated with extraction of the affected tooth and replacement with an implant.<sup>8</sup>

A common periodontal problem among adult orthodontic patients is generalized horizontal bone loss in the anterior region of the mouth. In these situations, if significant bone loss has occurred on all anterior teeth, then often the teeth have disproportionate crown/root ratios. The orthodontist must recognize this problem prior to bracket placement (Fig. 18-13). It may be appropriate in these situations to reduce the clinical crown lengths of these teeth to achieve



**Fig. 18-13** This 61-year-old female had **A** severe crowding of her mandibular incisors and **B** significant horizontal bone loss around her mandibular incisors. **C** A diagnostic wax setup showed that the mandibular left lateral incisor could be extracted to eliminate the crowding. Since the bone levels were flat, the incisal edges were equilibrated prior to bracket placement (**D** and **E**), in order to maintain a flat bony architecture during orthodontics (**F-H**). **J** After bracket removal, the restorative dentist placed porcelain veneers on the teeth to close the open embrasures.

two objectives.<sup>3,8</sup> First, if the crown length is reduced, then the crown/root ratio will improve, and the mobility of the tooth after orthodontic therapy will be reduced. Second, if horizontal bone loss has occurred in only one area, then reduction of crown length will avoid the creation of bony defects between adjacent teeth as the teeth are aligned. The orthodontist should draw on the tooth with a pencil or pen to identify how much crown length must be removed (Fig. 18-13). Then tooth removal should be accomplished slowly with water spray to avoid damaging the pulp of the tooth.<sup>11</sup> Once the new incisal edge has been established, then the orthodontist can use this surface of the tooth as a reference for bracket placement. At the end of treatment, the mobility of the teeth will be improved, and the periodontal defect will be eliminated.

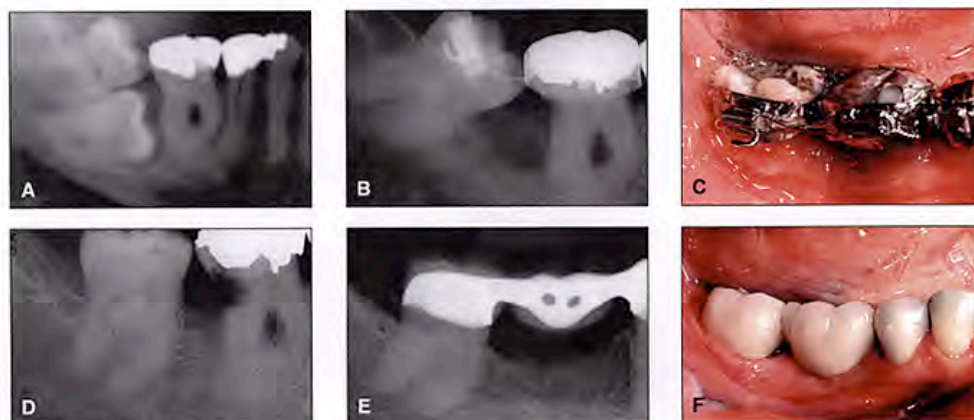
### Negotiate the Extraction of Hopeless Teeth

Occasionally, adults present for orthodontic treatment with teeth that are either periodontally or restoratively hopeless and which require extraction at some point during interdisciplinary treatment (Fig. 18-14). In these situations it is important for all members of the team (restorative dentist, periodontist, orthodontist, and oral and maxillofacial surgeon) to participate in the decision regarding timing of the extraction.<sup>1</sup> If the tooth has a periodontal or pulpal infection that cannot be maintained by the patient, dentist or periodontist during treatment, then the tooth may

require extraction before orthodontic bracketing. However, orthodontic treatment becomes more complicated with each edentulous space that is created prior to orthodontics, especially if that space must be maintained during and after orthodontic therapy. In addition, the mechanics could be more complicated if several teeth must be removed prior to orthodontic treatment. The fewer teeth the patient has, the more difficult it is to anchor the remaining tooth movement. If possible, it is advantageous for the orthodontist to maintain hopeless teeth in the dental arch during orthodontic treatment (Fig. 18-14). They provide anchorage and space maintenance for the orthodontist, and occlusal function and intraoral comfort for the patient. Therefore, it is desirable to extract hopeless teeth after orthodontic treatment as long as the periodontal health of adjacent teeth can be maintained.

### Reshape/Rebuild Teeth with Unusual Crown Form

Some orthodontic–restorative patients have small, malformed teeth that will require restoration after the completion of orthodontic treatment. In some of these situations, the orthodontist must create additional space to restore these teeth. In other situations, the malformed teeth are too large, and must be reduced in width. Ideally, restoration of these small or malformed teeth should be performed before the initiation of orthodontic therapy. However, often there is not enough space to restore the tooth before bracket



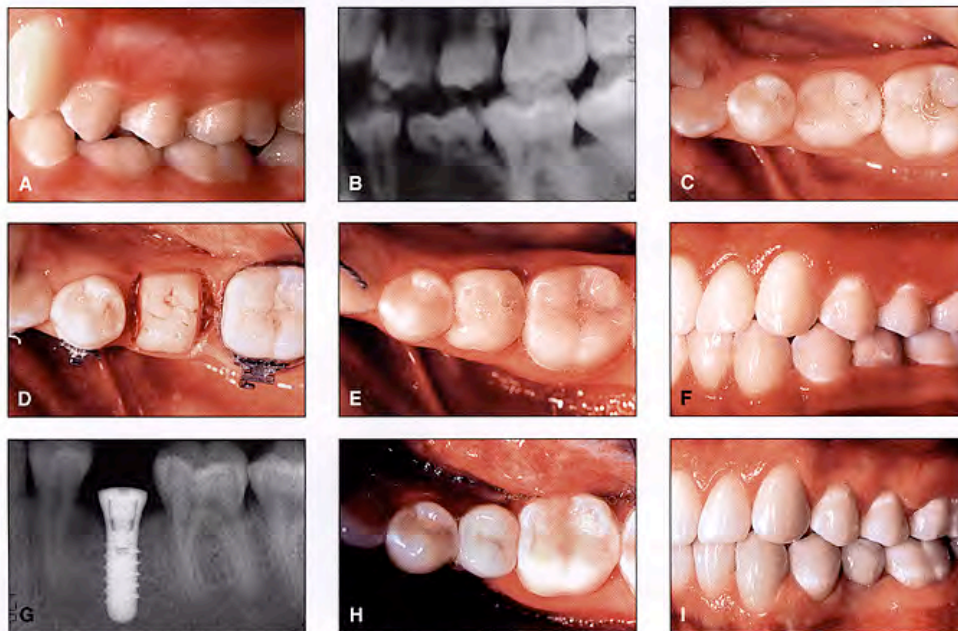
**Fig. 18-14** This 55-year-old female had an impacted mandibular right second molar (A), and the third molar had erupted over the occlusal surface. The first molar had severe bone loss on the distal root, a Class 3 furcation defect, and was considered hopeless. The second molar was extracted (B), and the first molar was used as an anchor to upright the third molar (C and D). Although the first molar would eventually be extracted, the timing of the extraction was delayed until after the orthodontics, and a bridge was chosen to restore the edentulous space (E and F). Timing the extraction of hopeless teeth until after orthodontics can help to facilitate difficult tooth movement.

placement. The team must decide how much space to create for these restorations and the timing of restoring these small or malformed teeth. Two situations are common: retained primary teeth and peg-shaped lateral incisors.

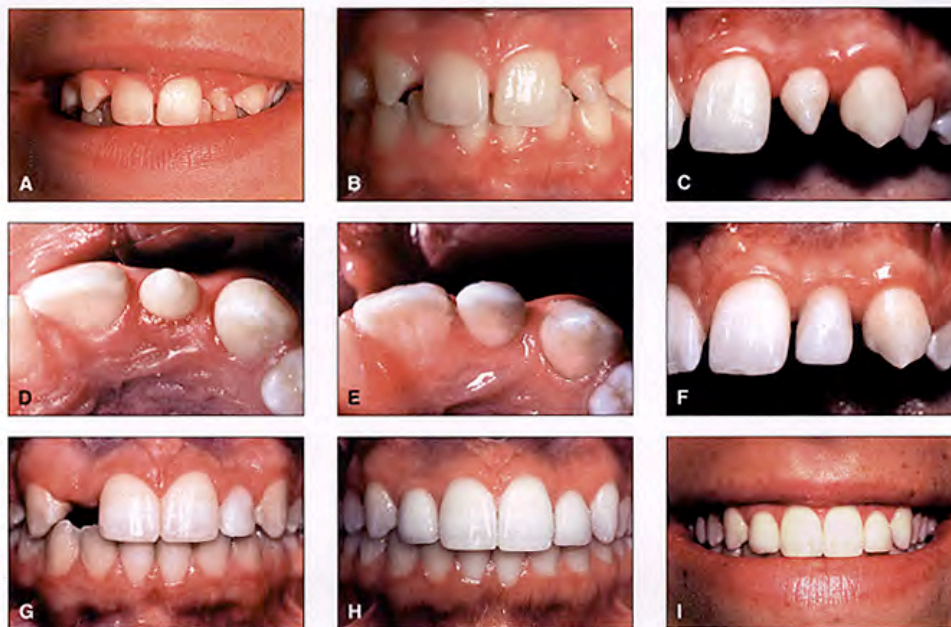When patients are congenitally missing their mandibular second premolars, the primary second molar may be unrestored, caries free, not submerged, and not ankylosed. If the patient will not have an implant placed for several years after orthodontics because of the potential for further jaw growth, then it may be advantageous to reduce and retain the primary molar during orthodontics.<sup>12</sup> After all it will maintain the width of the alveolar bone, prevent supereruption of opposing teeth, and help to maintain mesiodistal width after orthodontics. However, these teeth are too wide and must be reduced to the size of a premolar (Fig. 18-15). After reduction, these teeth have exposed cementum on the mesial and distal surfaces, so it is often advantageous to build-up these teeth with composite. These temporary, inexpensive restorations will help to prevent interproximal caries and provide a better-shaped buccal

surface for bonding of an orthodontic bracket.<sup>12</sup> If the primary molar roots do not resorb excessively during orthodontics, these primary teeth may remain for several years until the patient is old enough to have an implant placed.

Another common orthodontic-restorative problem is peg-shaped or malformed maxillary lateral incisors. In some patients, the best choice for treating a peg-shaped lateral incisor is to restore the malformed tooth to its correct dimension. If sufficient space exists, a composite restoration may be placed before orthodontic treatment (Fig. 18-16). However, in most situations, there is insufficient space to restore the malformed lateral incisors. Therefore, orthodontics is often necessary to create space to build-up peg-shaped lateral incisors. The space is usually acquired by placing open coil-springs on either side of the tooth.<sup>1</sup> This will create space on the mesial and distal surfaces for future restoration. It is generally advantageous to position the tooth closer to the central incisor than the canine, so the emergence profile of the restoration on the mesial surface is rather flat and matches the adjacent



**Fig. 18-15** This 15-year-old female was congenitally missing her mandibular left second premolar (A and B), and the primary second molar was retained (C). The restorative plan was to replace the missing tooth with an implant. To maintain the alveolar ridge width for the implant, but to create the appropriate space for the implant crown, the width of the primary tooth was reduced significantly (D), and the exposed dentin was restored with composite. Two years later, at the end of orthodontics, the primary molar was still present and helped to maintain the intra-arch space (E) and provide an occlusal stop for the opposing premolar (F). One year later, the primary molar was extracted, an implant was placed (G), and 6 months later it was restored with a porcelain crown (H and I).



**Fig. 18-16** This 12-year-old female was congenitally missing her maxillary right lateral incisor (A and B), and the left lateral was cone shaped (C and D). The restorative plan involved replacing the missing tooth with an implant and restoring the malformed lateral incisor with a porcelain crown. A diagnostic wax setup was constructed to determine the appropriate size of the temporary restoration of the malformed lateral incisor (E and F) and facilitated the orthodontic correction of the malocclusion (G). When the patient completed facial growth 3 years later, an implant was placed, and porcelain crowns were placed on the implant and malformed lateral incisors (H and I).

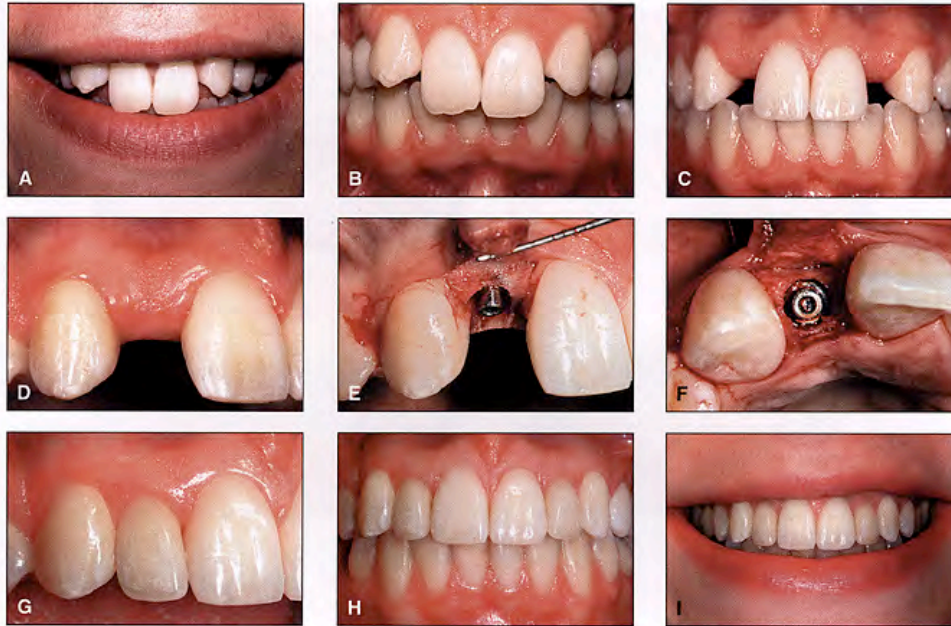
incisors. In this way, most of the overcontouring is on the distal surface, which is less obvious esthetically. In addition, the gingival margin of the peg-shaped tooth should be aligned with the contralateral lateral incisor in order to create symmetric gingival levels and crown lengths after restoration. If these principles are followed, the restored peg-shaped lateral incisor will match the contralateral lateral incisor in size and shape.

### Position Teeth to Facilitate Restorative Dentistry

In the nonrestored adolescent patient, orthodontic positioning of teeth is determined by the size and shape of the teeth. Ideally, if the sizes of all teeth are compatible, then a Class I occlusion with complete interdigitation is possible. However, in the orthodontic–restorative patient, it may not be prudent to position teeth ideally. If restorations are planned for the patient, it may be advantageous to position

teeth to facilitate this restorative treatment. Specific restorations require different types of tooth positioning.

A common orthodontic–restorative situation involves the patient who is congenitally missing one or two maxillary lateral incisors and will have implants to replace the missing tooth or teeth after orthodontic therapy. If the patient were missing one maxillary lateral incisor, the contralateral lateral incisor would determine the amount of space for the implant and crown. However, in some patients the existing lateral incisor may be peg shaped (see Fig. 18-16). In other situations, both lateral incisors are congenitally absent (Fig. 18-17), and the amount of space is determined by two factors<sup>12</sup>; esthetics and occlusion (Fig. 18-17). An esthetic relationship exists between the size of the maxillary central and lateral incisors. The size relationship has been called the “golden proportion”.<sup>13</sup> Ideally, the maxillary lateral incisor should be about two-thirds the width of the central incisor.<sup>14</sup> Since most central incisors are about 9 mm wide, the width of the lateral incisor space should be no less than 6 mm. Today the narrowest implants



**Fig. 18-17** **A** and **B** This 14-year-old female was congenitally missing both maxillary lateral incisors. **C** The treatment plan involved opening space for two implants and two crowns. **D** The labial sulcus depths of the central incisor and canine were 1 mm, there was no incisal wear of either tooth, and the width-to-length proportions of these teeth were normal. **E** and **F** Therefore, the position of the head of the implant was determined by the future gingival margin of the lateral incisor implant crown. When the implant crown was placed (**G**), the gingival margin level was positioned correctly relative to the adjacent teeth as well as the contralateral incisor (**H** and **I**).

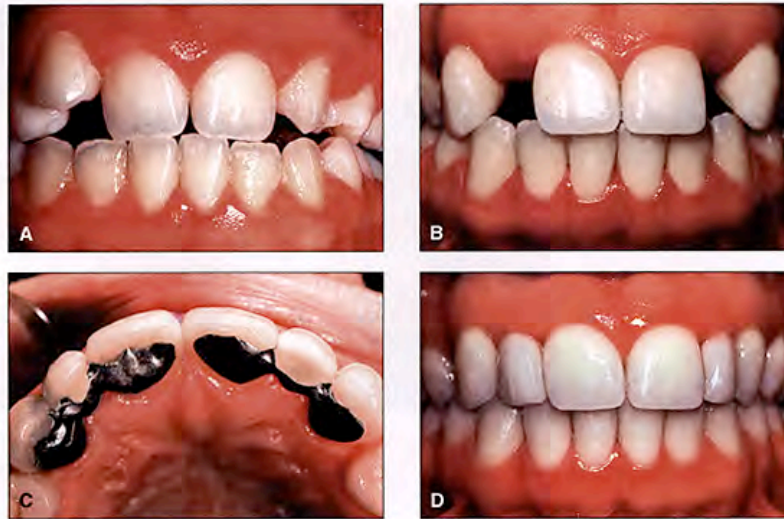
are about 3.2 mm in diameter. If the edentulous space were 6 mm wide, then about 1.4 mm would exist between the implant and the adjacent roots (Fig. 18-17). Previous studies have documented that narrower distances between the implant and adjacent root are more likely to show a reduction in bone height over time.<sup>15,16</sup> So at least 1 mm between implant and adjacent root is desirable.

However, in some situations, the orthodontist may create less than the ideal width for a lateral incisor implant and crown because of the patient's occlusal relationships. The orthodontist should assess the posterior intercuspation as well as the appropriate amount of overbite and overjet. If the correct occlusion has been achieved, and the space for the implant crown is too narrow, the orthodontist should remove interproximal enamel from the central incisors and canines to provide additional width for the lateral incisor implant. In some cases, if the interproximal surfaces of the canines and central incisors are already flat, then the orthodontist must remove enamel interproximally from the premolars.<sup>17</sup> The maxillary premolars generally have

tapered crowns with sufficient thickness of enamel, so they can be reduced without penetrating the dentin interproximally. By reducing the widths of adjacent anterior or posterior teeth, the orthodontist can create sufficient space for lateral incisor implants.

Another method for temporarily replacing congenitally missing maxillary lateral incisors is a resin-bonded bridge. Although this type of restoration has a high incidence of failure caused by debonding, it is a conservative means of replacing a missing maxillary lateral incisor, until an implant can be placed at a later time. If the teeth are in the proper position, the life of a resin-bonded bridge can be increased, and the tendency for debonding may be decreased. Since a resin-bonded bridge depends on surface coverage for retention,<sup>18,19</sup> the greater the area of coverage on the lingual of the teeth, the greater the retention (Fig. 18-18). It is therefore important to position anterior teeth with appropriate overjet and overbite relationships. The anterior overbite should not be excessive, but enough to provide disocclusion of the posterior teeth,





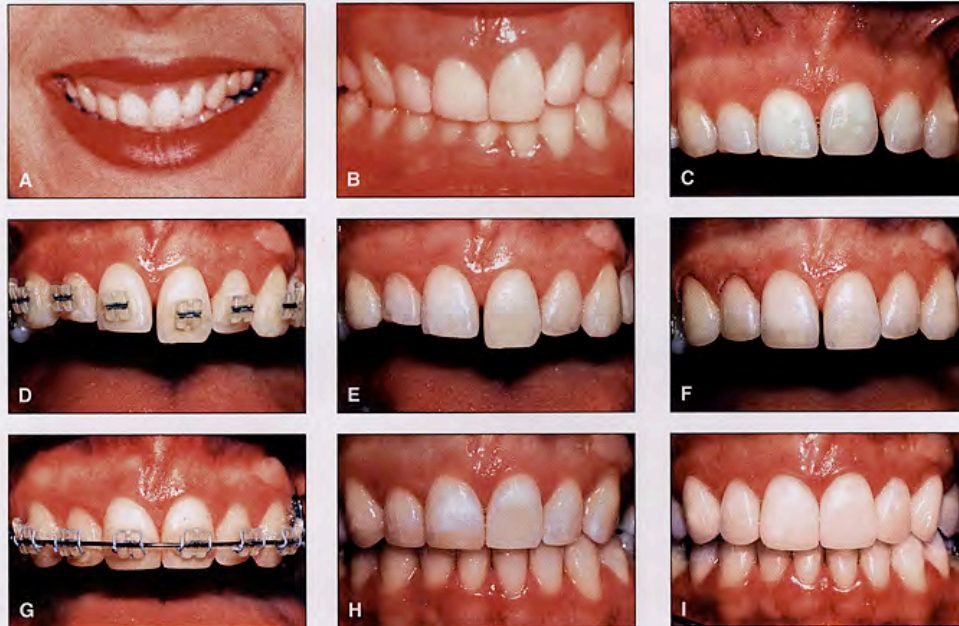**Fig. 18-18** **A** This 22-year-old female was congenitally missing both maxillary lateral incisors. The orthodontic-restorative plan involved opening space **(B)** for bilateral resin-bonded bridges **(C)**. To enhance retention and provide sufficient space for bonding of the metal connectors, the overbite should be minimal **(B)**, and only sufficient to permit posterior disocclusion in protrusive function. Seven years later **(D)**, the original bridge was still in place, and the esthetic appearance was satisfactory.

when the mandible is protruded forward. The anterior overjet should produce contact of the maxillary and mandibular incisors in centric occlusion. The angulation of the maxillary anterior teeth should be upright and oriented more vertically after orthodontic treatment. This will produce a shear force on the major connector of the resin-bonded bridge, which will enhance retention and stability of the bridge.<sup>20</sup> If incisors are proclined, the force on the bonded metal connector will be a tensile force, which could cause debonding of the bridge.

Another common problem in the adult orthodontic patient is wear or abrasion of the maxillary incisors causing uneven gingival levels and unequal crown length of adjacent central incisors (Fig. 18-19). Treatment for this problem could consist of periodontal crown lengthening to level the gingival margins, orthodontic extrusion of the longer central incisor, or intrusion and restoration of the short tooth or teeth. To diagnose this problem adequately, the clinician must first evaluate the labial sulcular depth of the maxillary incisors.<sup>21</sup> If the sulcular depths are uniformly 1 mm, then the discrepancy in gingival margins may be due to uneven wear or trauma of the incisal edges of the anterior teeth. In these situations, the clinician must decide if the amount of gingival discrepancy will be noticeable (Fig. 18-19). If so, bracketing and alignment of these teeth must be accomplished in a way that improves the esthetics and restorability of the abraded teeth. In these

situations, the gingival margins are used as a guide in tooth positioning, not the incisal edges.<sup>22</sup> As the gingival margins are aligned, the discrepancy in the incisal edges becomes more apparent (Fig. 18-19). These incisal discrepancies are restored temporarily with composite restorations, and then restored permanently with porcelain veneer restorations after the teeth have stabilized. If the gingival margin discrepancies are corrected by leveling the gingival margins orthodontically, these tooth positions should be maintained for at least 6 months to avoid relapse. As teeth are intruded, the orientation of the periodontal fibers changes and becomes more oblique.<sup>23</sup> It typically takes at least 6 months for these fibers to reorient themselves in the horizontal position and to stabilize the tooth position.

Mandibular incisal edge abrasion is also a common problem in the adult orthodontic-restorative patient (Fig. 18-20). When this occurs, the mandibular incisors typically erupt in order to maintain contact. This presents a restorative dilemma for the general dentist, because it leaves no space to place the incisal restoration. Without orthodontics to intrude the lower incisors and create restorative space, the patient would require periodontal crown lengthening with bone removal and apical positioning of the gingival margin. If severe wear has occurred, this could also require root canal therapy and a post and coping on the short and abraded mandibular incisors. However, orthodontics is of tremendous benefit for restorative



**Fig. 18-19 A-C** This 29-year-old female had crown length discrepancies between the maxillary right and left central and lateral incisors and canines. The labial sulcular depths of all anterior teeth were 1 mm, and the cemento-enamel junctions were at the bottom of the sulcus. The anterior teeth on the right had been abraded, and the teeth had continued to erupt. Therefore, the correct treatment plan involved intrusion of the right central and lateral incisors and canine (**D**), temporary restoration of these teeth with composite (**E** and **F**), and replacement of the orthodontic brackets (**G**) for 6 months to stabilize the intruded teeth. **H** At the end of orthodontics the lengths of the right and left anterior teeth were equivalent. **I** Two years later, after final restoration with porcelain veneers, the intruded position of the anterior teeth was stable.

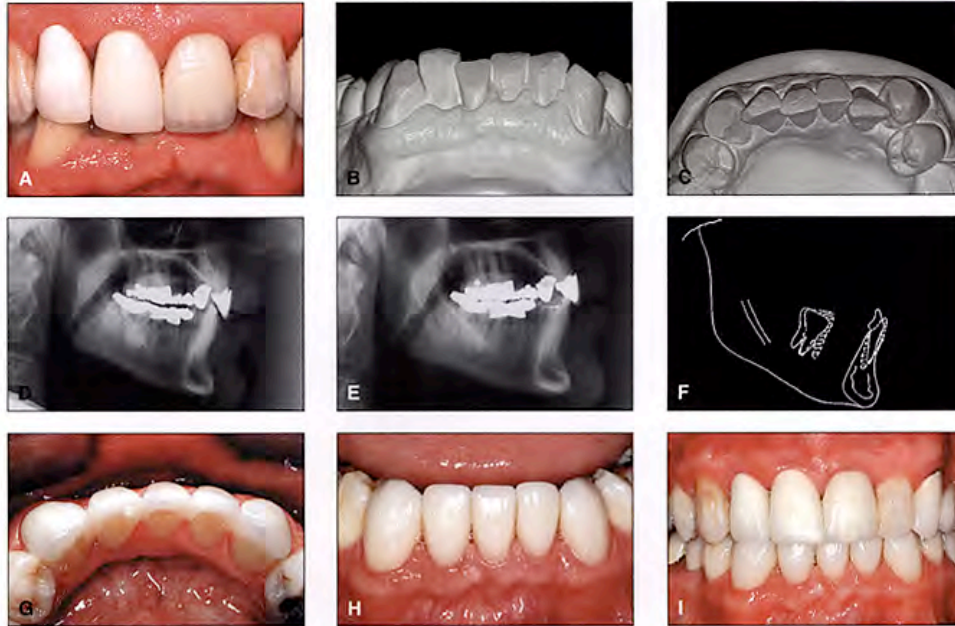
patients with significant wear of their mandibular incisors. By intruding the lower incisors (Fig. 18-20), the orthodontist can create space for the restoration, avoid gingival surgery, eliminate the need for endodontic treatment, and thereby simplify the restoration of the abraded teeth.

When patients are congenitally missing their mandibular permanent second premolars, the clinician must monitor the vertical position of the primary second molar. Occasionally, the mandibular primary second molar will become ankylosed and fused to the alveolus (Fig. 18-21). In these situations, leaving the primary molar may result in a significant vertical bone defect in the edentulous ridge. If an implant is planned in the edentulous site, the vertical defect may be difficult to implant. If an ankylosed primary molar is not extracted early enough, and a vertical ridge defect is produced, one option is to place a bone graft in the area either at the same time or prior to implant placement. Another option is to move the mandibular first premolar into the second premolar position<sup>20</sup> and to place the implant

in the first premolar position (Fig. 18-21). Previous studies have shown that it is possible, within limits, to move a tooth into a narrower edentulous ridge<sup>24,25</sup> in order to create an implant site. The bone that is created behind the moving tooth typically will be as wide as the root of the tooth that was moved. This type of orthodontic movement (called orthodontic implant site development) may eliminate the need for a bone graft in the edentulous site.

### Consider Implants to Facilitate Difficult Tooth Movement

In recent years, dental implants have become an accepted method of replacing missing teeth.<sup>26</sup> Today millions of implants are placed annually to rehabilitate and re-establish patients' occlusions. In many of these individuals, the teeth may be in a less than ideal position to accept the integration of a single implant or groups of implants with



**Fig. 18-20** This 52-year-old male had a deep anterior overbite (A) and a protrusive bruxing habit that produced significant wear of the mandibular incisors (B and C). D There was no space for the restorative dentist to restore these teeth. Orthodontic treatment was initiated to intrude the mandibular incisors (E and F), so they could be restored with porcelain veneers (G and H). I Not only was the deep overbite corrected, but also the orthodontic intrusion had permitted the restoration of esthetics and function to this debilitated dentition.

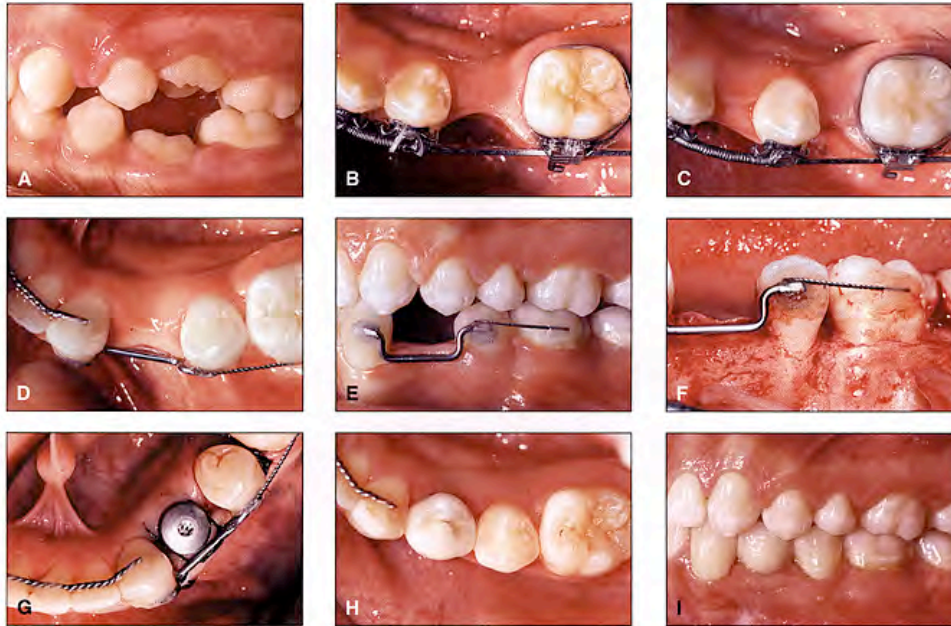
the remaining teeth. These patients could benefit from orthodontics to reposition malposed teeth and enhance the overall occlusal scheme.<sup>27</sup> However, if significant numbers of teeth are missing, the orthodontist is at a disadvantage, because of the lack of anchorage to effect the desired tooth movement.

Several types of implant systems are available to provide anchors for tooth movement. These include subperiosteal implants,<sup>28-30</sup> interproximal transitional implants,<sup>31</sup> palatal implants,<sup>32-34</sup> mini-implants,<sup>35-37</sup> and titanium plates.<sup>38-40</sup> These auxiliaries are typically placed between the roots of teeth, apical to the roots of teeth, or in the retromolar regions of the maxilla and mandible. Although they are efficient anchors for tooth movement and are very versatile, they are also expendable. Usually they are removed after orthodontic treatment and discarded. Although this may be an extra expense for the patient, in a completely edentulous patient, this technology may be appropriate. However, in a partially edentulous patient, where implants will be used as anchors to restore the occlusion, these restorative implants could be used initially for orthodontic anchorage,

and later as restorative abutments after orthodontics has been completed.<sup>27</sup>

The indications<sup>27</sup> for using a restorative implant as an orthodontic anchor include: intra-arch intrusion of teeth that have overerupted; intra-arch retraction of teeth that are proclined; and intra-arch protraction of teeth that are positioned distally (Fig. 18-22). In each of these situations, the implant must be placed prior to orthodontic bracketing. However, the implant must be positioned appropriately, so it will not only satisfy the orthodontic requirements, but also be in a suitable position for the final restoration. The orthodontist must construct a diagnostic wax setup, after consultation with the restorative dentist and surgeon. The diagnostic wax setup must be constructed in a series of specific steps to ensure accuracy. These steps have been documented elsewhere.<sup>27,41,42</sup> The diagnostic wax setup permits construction of a placement guide for the surgeon to provide accurate positioning of implants.

After placement the implants must integrate with the bone prior to orthodontic loading. The timing of implant loading for single implants is determined by the amount



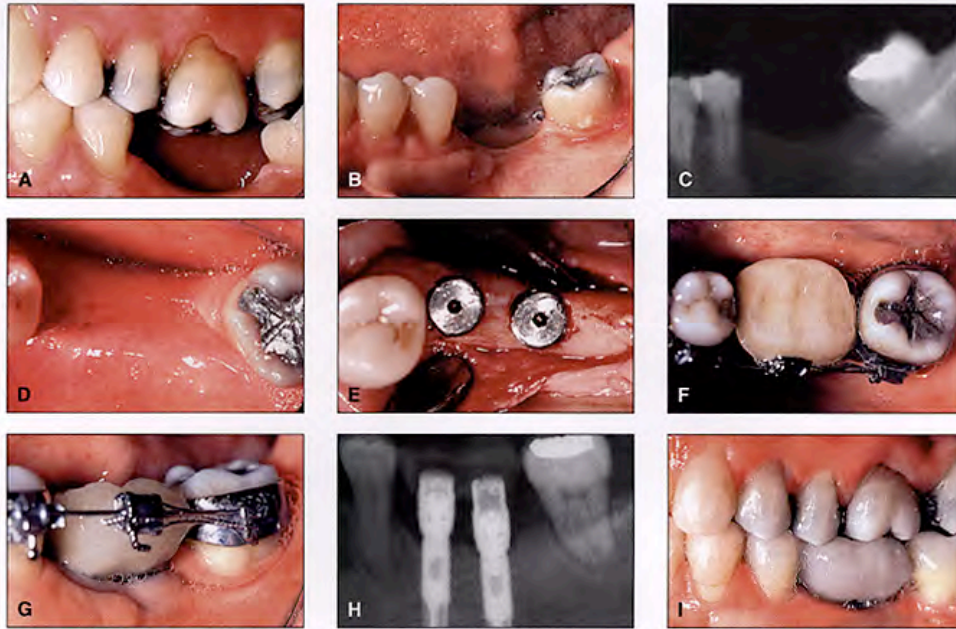
**Fig. 18-21** **A** This 16-year-old female was congenitally missing the mandibular left second premolar, and the primary molar had ankylosed and was submerged. **B** After extraction of the primary molar, the alveolar ridge width decreased significantly. To create adequate ridge width for placement of an implant, the first premolar was moved distally into the second premolar position (**C-E**), and the implant was placed in the first premolar position (**F** and **G**). **H** and **I** The process of "orthodontic implant site development" is an excellent method to facilitate implant placement in sites with deficient bone.

of time required by the bone adjacent to the implant to undergo secondary osteon (remodeling) formation around the implant.<sup>43</sup> If multiple implants are placed at the same time, they are often loaded immediately after placement, using a provisional prosthesis. Even though the bone around the implant has not completely remodeled, the rigidity supplied by cross-arch splinting allows for integration to occur around the functioning implants.<sup>44</sup> Recent research has shown that when implants are loaded with static or continuous load in the same direction, the bone on the implant surface develops more rapidly.<sup>45,46</sup> However, when a dynamic load is applied to the implant (not continuous and in different directions), much less bone develops on the implant surface.<sup>46</sup> When the implant is loaded continuously, the same biomechanic message is delivered to the bony surface, which is to stimulate bone formation on the compressed surface, in order to form more supporting bone. When the force on the implant is dynamic or intermittent, the biomechanic message is not clear, and less bone is formed. Therefore, if implants are to be used for orthodontic anchorage, they could be loaded

immediately, since an orthodontic load is continuous and in the same direction.

Animal studies have shown that when implants are loaded, more bone develops on the pressure or compressive side of the implant.<sup>47</sup> This is the opposite of what happens around teeth. When the periodontal ligament of a tooth is loaded with a compressive force, bone resorbs on the pressure side and deposits on the tension side. However, implants do not have a periodontal ligament, and therefore the bone that forms on the pressure side of the implant is referred to as *buttressing bone*, which develops in response to implant loading.

After the implant has been uncovered, a provisional restoration must be placed so that the orthodontic force can be attached to the implant. The type of provisional restoration varies, depending on the type of orthodontic mechanics.<sup>27</sup> In some situations, a tooth-shaped plastic restoration is required. However, in other situations, a metal abutment is sufficient to provide the anchorage. In general, if orthodontic brackets are not to be used, a simple metal cap can be placed on top of the implant. In most situations,



**Fig. 18-22** **A** This adult female had lost her mandibular left first and second molars due to dental caries, and the maxillary first molar had supererupted. **B-D** In addition, the mandibular third molar had tipped mesially. **E** The restorative plan was to place two premolar implants to replace the missing teeth. The implants would be used as anchorage to upright the third molar and move the tooth (**F** and **G**) and roots (**H**) mesially. **I** By using the implants as anchorage, the posterior occlusion was maintained, and the implants were restored to provide occlusion for the maxillary left first molar.

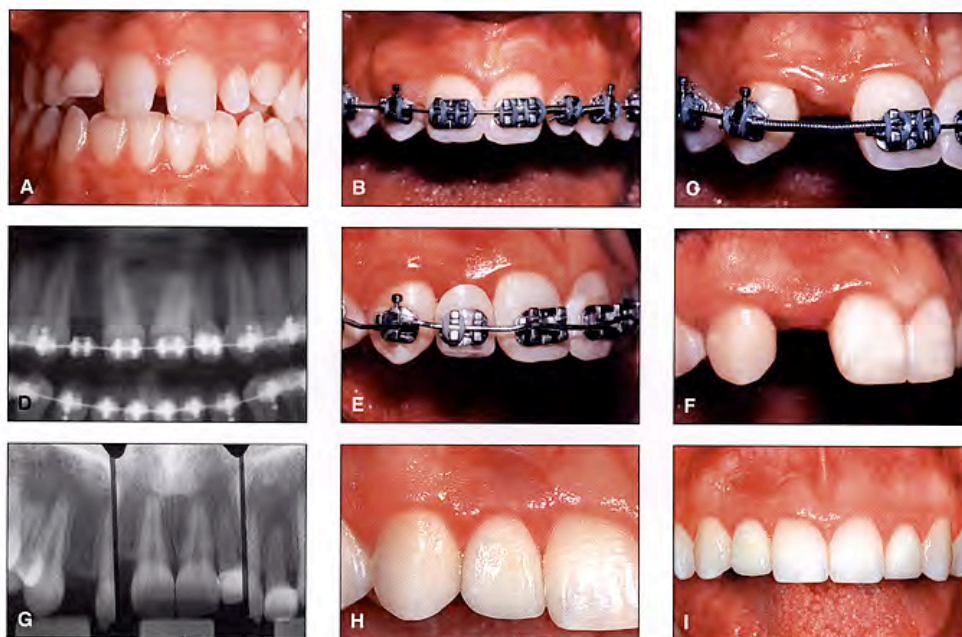
if the teeth adjacent to the implant are to be moved toward the implant, a provisional plastic restoration is necessary to permit accurate positioning of these teeth during the orthodontic process. In these situations, the size of the provisional crown can be ascertained from the diagnostic wax setup used to create the placement guide.

### Evaluate Tooth Position Prior to Bracket Removal

If an orthodontic patient will not require restorations, it is appropriate that the orthodontist makes the final decisions regarding tooth position and appliance removal. However, if the patient will require restorations after orthodontics, the restorative dentist should play a part in the finishing process. It is advantageous to request input from the restorative dentist during final tooth positioning, and the patient should be referred back to the restorative dentist during the final 6 months of treatment. A note or letter should be sent asking for input from the restorative dentist

or periodontist about final tooth positioning, especially in areas where restorations are planned. Not only does the patient benefit from having several individuals evaluate the final result, but also the orthodontist will learn from this interaction about the individual requirements of certain types of restorative patients.

In most orthodontic patients, aligning the crowns of the teeth will produce proper root angulation. Ideally, the roots of the teeth should not be in close interproximal contact. In that way, sufficient bone will be present between the roots of each of the teeth. Proper root angulation may be even more important for the orthodontic-restorative patient. When implants are planned for missing maxillary lateral incisors, it is important to create adequate space for the implant between adjacent roots.<sup>12</sup> As the central incisor and canine are pushed apart, the apices of the roots move toward one another (Fig. 18-23). During orthodontic finishing, radiographs must be taken to assess whether or not proper root angulation has been achieved. If not, the archwire must be removed, and the teeth should either be rebracketed or bends placed in the archwire to achieve



**Fig. 18-23** A This 16-year-old female was congenitally missing her maxillary right lateral incisor, and the left lateral incisor was malformed. The restorative plan involved restoration of the malformed left lateral incisor and placement of an implant and crown to replace the missing right lateral incisor. After aligning the teeth (B) and opening space (C) for the implant, a progress radiograph (D) was indispensable in determining the appropriate tooth and root movement (E) necessary to create the correct final crown (F) and root (G) position prior to implant placement and restoration (H and I).

proper root angulation. If the roots are too close together, an implant cannot be placed.

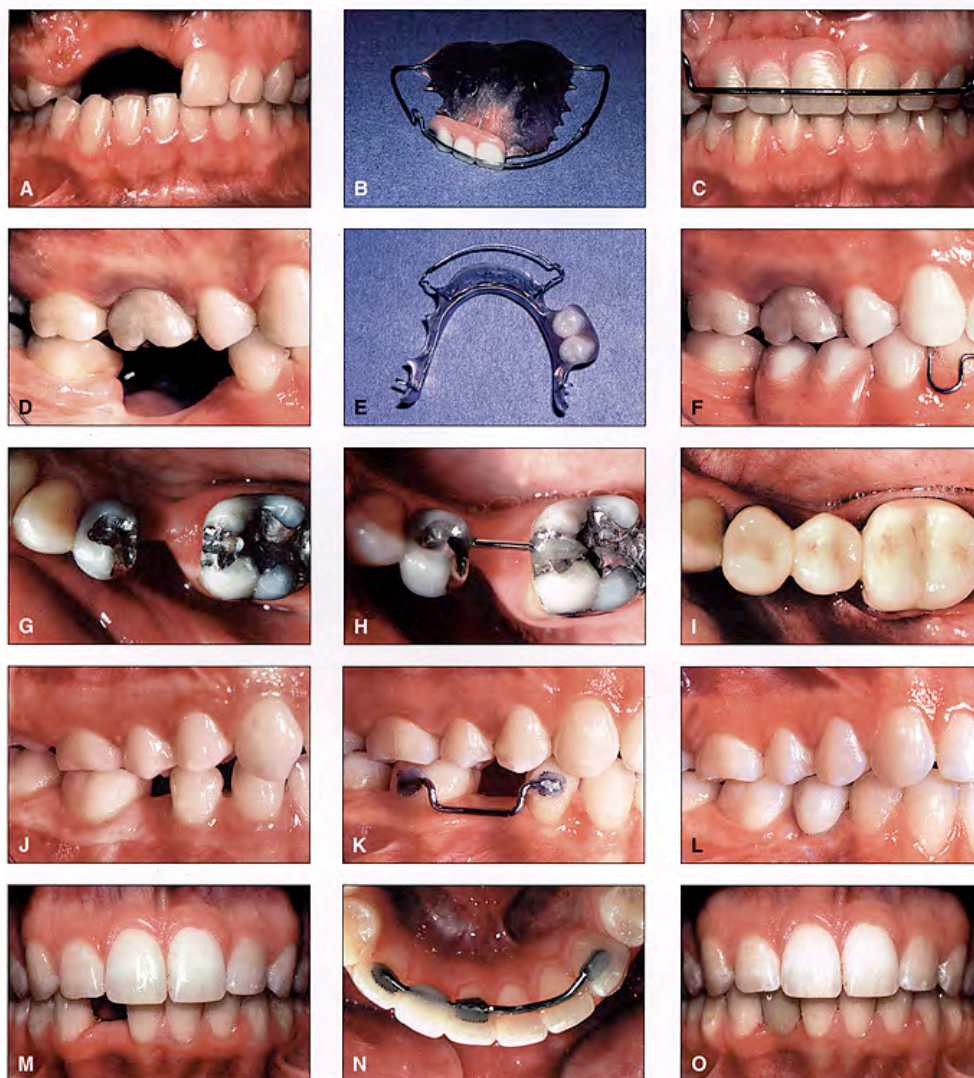### Determine the Appropriate Type of Retention

Fixed and/or removable retainers are used routinely to maintain tooth position immediately after removal of orthodontic appliances. In most orthodontic patients, removable retainers include either maxillary and mandibular Hawley appliances or custom-fit Essix retainers. Fixed retainers typically consist of braided or solid stainless steel or gold wires that are bonded to the lingual surfaces of the maxillary or mandibular anterior teeth. In some patients it is beneficial to place combinations of fixed and removable retainer types. If patients wear their retainers for a sufficient time, the teeth will stabilize. However, the adult orthodontic patient may be missing one or more teeth. In addition, an adult restorative patient may have had prior bone loss, and the periodontally involved teeth could be significantly

mobile. If so, the purpose of retention is not only to stabilize the teeth and reduce mobility, but also to maintain posterior and anterior edentulous spaces, until they are restored with either bridges or implants.

If a patient is missing three or more adjacent anterior or posterior teeth after orthodontic treatment, fixed retention is probably unlikely. Therefore, a removable retainer with prosthetic teeth will be necessary to help stabilize the remaining teeth in that arch, as well as to provide an occlusal stop for teeth in the opposing arch (Fig. 18-24). However, when constructing the removable retainer, occlusal stops are necessary, in order to prevent occlusal loads from damaging the edentulous ridge. These stops are constructed from wire and/or acrylic and can cover the gingula of the anterior teeth or insert onto the occlusal surfaces of posterior teeth.

If one tooth is missing, and an implant or bridge is planned to restore the edentulous space, a fixed bonded wire is more desirable for several reasons (Fig. 18-24). First, the fixed retainer does not require patient compliance. Second, it can stop the opposing occlusion from overerupting



**Fig. 18-24** An important step in any interdisciplinary treatment plan is to select the appropriate method of retaining the orthodontic tooth movement prior to restoration. In patients who are missing several maxillary (A-C) or mandibular (D-F) teeth after orthodontic treatment, it may be prudent to maintain tooth position with a removable retainer with prosthetic teeth to establish satisfactory esthetics and function. If the patient is to have a posterior fixed bridge placed after orthodontic treatment, an intracoronal wire and acrylic splint (G-I) is an excellent method to prevent supereruption of teeth in the opposing arch, and to rigidly maintain tooth position prior to bridge construction. If an implant is to be used to replace a missing mandibular second premolar after orthodontic treatment, it is advantageous to place an extracoronal wire and acrylic splint (J-L) to maintain the space rigidly during implant placement, osseointegration, and final restoration. If a mandibular incisor is missing, and the space is to be maintained after orthodontics (M-O) a fixed mandibular lingual retainer with an attached tooth is a convenient method of retaining the space until the bridge or implant is placed.

Third, teeth can be attached to the bonded wire in order to provide an esthetic temporary replacement for the patient. Whatever the choice of retainer, the important step is to make a decision about the responsibility for retention in perio-restorative patients prior to orthodontic treatment. It is much easier to coordinate the appointments and appliances if the team members make the decisions collectively, so the patient will be provided with the optimum method of retention for his/her specific ortho-perio-restorative situation after appliance removal.

### Summary

This chapter has discussed and illustrated a series of 10 guidelines for managing the orthodontic patient with periodontal or restorative complications. One of the most important steps is to generate realistic treatment objectives that will fit the patient's needs, desires, and financial capabilities, and the goals of the team members. Then, a visual representation of the final result must be created in the form of a diagnostic wax setup. This provides the blueprint or endpoint of treatment for the entire team. Next, the sequence of treatment must be established for patients who will require several steps performed by multiple team

members at varying points during their treatment. This structured list of steps and responsibilities becomes the roadmap for treating the patient. Then, the periodontal problems must be identified, and the person responsible for the treatment of these soft tissue or osseous defects must be determined. If certain teeth are hopeless, the timing of extraction must be sequenced to facilitate the needs of all practitioners on the team. Prior to appliance placement, any malformed, abraded, or broken-down teeth should be built up to facilitate bracketing. The future position of teeth should be determined by the specific restorative or periodontal needs of the patient. If insufficient anchorage exists for tooth movement, implants could be considered for orthodontic as well as restorative anchorage during and after tooth movement. Prior to appliance removal, the orthodontist should ask the restorative dentist and/or periodontist to evaluate the patient's tooth position in order to achieve appropriate crown and root position for restorative treatment, and to determine the type of retention necessary, especially for missing teeth prior to appliance removal. If the team of periodontist, surgeon, orthodontist, and restorative dentist follows these 10 guidelines, the management of ortho-perio-restorative patients will be simplified, predictable, and pleasurable.

### REFERENCES

- Kokich V, Spear F. Guidelines for managing the orthodontic-restorative patient. *Semin Orthod* 1997;3:3-20.
- Casko J, Vaden J, Kokich V, et al. American Board of Orthodontics grading system for dental casts and panoramic radiographs. *Am J Orthod Dentofac Orthop* 1999;114:18-23.
- Mathews D, Kokich V. Managing treatment for the orthodontic patient with periodontal problems. *Semin Orthod* 1997;3:21-38.
- Kokich V. Anterior dental esthetics: An orthodontic perspective. III. Mediolateral relationships. *J Esthet Dent* 1993;5:18-22.
- Kokich V. Managing complex orthodontic problems: The use of implants for anchorage. *Semin Orthod* 1996;2:153-160.
- Kokich V, Nappen D, Shapiro P. Gingival contour and clinical crown length: Their effects on the esthetic appearance of maxillary anterior teeth. *Am J Orthod* 1984;86:89-94.
- Kokich VG, Shapiro PA. Extraction of a mandibular incisor to facilitate orthodontic treatment. *Angle Orthod* 1984;54:139-153.
- Kokich V. The role of orthodontics as an adjunct to periodontal therapy. In: Newman MG, Takei HH, Carranza FA, eds. *Clinical periodontology*. 9th edn. Philadelphia: WB Saunders, 2002:704-718.
- Kokich V. Esthetics: the orthodontic-periodontic-restorative connection. *Semin Orthod* 1996;2:21-30.
- Ingber J. Forced eruption: Part I. A method of treating isolated one and two wall infrabony osseous defects—rationale and case report. *J Periodontol* 1974;45:199-206.
- Zachrisson B, Mjor I. Remodeling of teeth by grinding. *Am J Orthod* 1975;68:543-553.
- Spear F, Mathews D, Kokich V. Interdisciplinary management of single-tooth implants. *Semin Orthod* 1997;3:35-74.
- Lombardi R. The principles of visual perception and their application to dental esthetics. *J Prosthet Dent* 1973;29:359-382.
- Rufenacht C. Structural esthetic rules. In: Rufenacht C, ed. *Fundamentals of esthetics*. Chicago: Quintessence Publishing, 1992:67-134.
- Esposito M, Ekkestube A, Grondahl K. Radiological evaluation of marginal bone loss at tooth surfaces facing single-tooth implants. *Clin Oral Implant Res* 1993;4:151-157.
- Thilander B, Odman J, Grondahl K, Friberg B. Osseointegrated implants in adolescents. An alternative in replacing missing teeth? *Europ J Orthod* 1994;16:84-95.
- Kokich V. Single-tooth implants: Planning with the aid of orthodontics. *J Oral Maxillofac Surg* 2004;62:48-56.
- Creugers N, Kayser A, Van't Hof M. A seven-and-a-half year survival study of resin-bonded bridges. *J Dent Res* 1992;71:1822-1825.
- Boyer D, Williams V, Thayer K, Dennehy G. Analysis of debond rates of resin-bonded bridges. *J Dent Res* 1993;72:1244-1248.
- Kokich V. Orthodontic-restorative management of the adolescent patient. In: McNamara JA Jr, ed. *Orthodontics and dentofacial orthopedics*. Ann Arbor: Needham Press, 2001:425-452.



21. Kokich V. Anterior dental esthetics: An orthodontic perspective. I. Crown length. *J Esthet Dent* 1993;5:19–23.
22. Kokich VG, Kokich VO, Spear F. Maximizing anterior esthetics: An interdisciplinary approach. In: McNamara JA Jr, Kelly K Jr, eds. *Frontiers in dental and facial esthetics*. Ann Arbor, Needham Press, 2001:1–18.
23. Reitan K. Clinical and histologic observations of tooth movement during and after orthodontic treatment. *Am J Orthod* 1967;53:721–745.
24. Stepovich M. A clinical study of edentulous closing spaces in the mandible. *Angle Orthod* 1979;49:277–283.
25. Hom B, Turley P. The effects of space closure on the mandibular first molar area in adults. *Am J Orthod* 1984;85:475–489.
26. ADA Council on Scientific Affairs. Dental endosseous implants: An update. *J Am Dent Assoc* 2004;135:92–97.
27. Kokich V. Comprehensive management of implant anchorage in the multidisciplinary patient. In: Hiiguchi K, ed. *Orthodontic application of osseointegrated implants*. Chicago: Quintessence, 2000:21–32.
28. Block M, Hoffman D. A new device for absolute anchorage for orthodontics. *Am J Orthod Dentofac Orthop* 1995;107:251–258.
29. Kluemper GT, Spalding PM. Realities of craniofacial growth modification. *Atlas Oral Maxillofac Surg Clin North Am* 2001;9:23–51.
30. Armbruster PC, Block MS. Onplant-supported orthodontic anchorage. *Atlas Oral Maxillofac Surg Clin North Am* 2001;9:53–74.
31. Gray JB, Smith R. Transitional implants for orthodontic anchorage. *J Clin Orthod* 2000;34:659–666.
32. Keles A, Erverdi N, Sezen S. Bodily distalization of molars with absolute anchorage. *Angle Orthod* 2003;73:471–482.
33. Giancotti A, Greco M, Docimo R, Arcuri C. Extraction treatment using a palatal implant for anchorage. *Aust Orthod J* 2003;19:87–90.
34. Celenza F. Implant-enhanced tooth movement: Indirect absolute anchorage. *Int J Periodontics Restor Dent* 2003;23:533–541.
35. Ohmae M, Saito S, Morohashi T, et al. A clinical and histological evaluation of titanium mini-implants as anchors for orthodontic intrusion in the beagle dog. *Am J Orthod Dentofac Orthop* 2001;119:489–497.
36. Kyung SH, Choi JH, Park YC. Mini-screw anchorage used to protract lower second molars into first molar extraction sites. *J Clin Orthod* 2003;37:575–579.
37. Cheng SJ, Tseng IY, Lee JJ, Kok SH. A prospective study of the risk factors associated with failure of mini-implants used for orthodontic anchorage. *Int J Oral Maxillofac Implants* 2004;19:100–106.
38. Chung KR, Kim YS, Linton JL, Lee YJ. The miniplate with tube for skeletal anchorage. *J Clin Orthod* 2002;36:407–412.
39. Sherwood KH, Burch J, Thompson W. Intrusion of supererupted molars with titanium miniplate anchorage. *Angle Orthod* 2003;73:597–601.
40. Sugawara J, Daimaruya T, Umemori M, et al. Distal movement of mandibular molars in adult patients with the skeletal anchorage system. *Am J Orthod Dentofac Orthop* 2004;125:130–138.
41. Smalley W. Implants for orthodontic tooth movement: Determining implant location and orientation. *J Esthet Dent* 1995;7:62–72.
42. Smalley WM, Blanco A. Implants for tooth movement: A fabrication and placement technique for provisional restorations. *J Esthet Dent* 1995;7:150–154.
43. Roberts WE, Smith R, Zilberman Y, et al. Osseous adaptation to continuous loading of rigid endosseous implants. *Am J Orthod* 1984;86:95–111.
44. Tarnow DP, Emtiaz S, Classi A. Immediate loading of threaded implants at stage I surgery in edentulous arches: Ten consecutive case reports with 1 to 5-year data. *Int J Oral Maxillofac Implants* 1997;12:319–324.
45. Piatelli A, Corigliano M, Scarano A, Costigliola G, Paolantonio M. Immediate loading of titanium plasma-sprayed implants: An histologic analysis in monkeys. *J Periodontol* 1998;69:321–327.
46. Duyck J, Ronold HJ, Van Oosterwyck H, Naert I, Vander Sloten J, Ellingsen JE. The influence of static and dynamic loading on marginal bone reactions around osseointegrated implants: An animal experimental study. *Clin Oral Implants Res* 2001;12:207–218.
47. Turley P, Shapiro P, Moffett B. The loading of bioglass coated aluminum oxide implants to produce sutural expansion of the maxillary complex in the pigtail monkey. *Arch Oral Biol* 1980;25:459–464.

