

# Maxillary Lateral Incisor Implants: Planning With the Aid of Orthodontics

Vincent G. Kokich, DDS, MSD\*

Implants are commonly used to replace congenitally missing lateral incisors in adolescent orthodontic patients. However, these restorations are often challenging for the orthodontist, surgeon, and restorative dentist. In some patients the space across the alveolar crest is too narrow to permit the surgeon to place the implant. Occasionally the root apices of the adjacent central incisor and canine are in close proximity. In other cases the ridge thickness could be inadequate and require augmentation. When the orthodontist opens the space, the papilla heights are adversely affected. Some adolescent patients have altered passive eruption after orthodontic treatment, which affects the level of the gingival margins. Finally, questions commonly arise regarding the appropriate age for implant placement in these young patients. If not addressed, these issues could compromise the aesthetics of the implant restoration. This article will use several clinical examples to discuss each of these 6 potential problems and provide guidelines for their solutions.

© 2004 American Association of Oral and Maxillofacial Surgeons  
*J Oral Maxillofac Surg* 62:48-56, 2004, Suppl 2

Implants have become a common method for restoring missing teeth. After all, if an individual is missing teeth, but has no restorations or wear of their existing teeth, today it would be inappropriate to remove enamel and dentin to place crowns on adjacent teeth to facilitate construction of a 3-unit bridge. Implants are a much more conservative approach. This is especially true in the adolescent orthodontic patient who is congenitally missing 1 or 2 maxillary lateral incisors. If the treatment plan calls for opening of the edentulous spaces, implants would be an ideal alternative for replacing the missing teeth. Research has shown that the success rate of implants is very high.<sup>1</sup> However, maxillary lateral incisor implants are challenging aesthetically. The amount of space is often small, the alveolar ridge may be deficient, the papillae are occasionally short, the adjacent roots could be too close, the gingival levels may be uneven, and the patient could be too young. Any of these issues could compromise the aesthetic outcome of even the finest surgical implant placement. Orthodontics can assist the surgeon and restorative dentist to improve

the aesthetics of maxillary lateral incisor implants. This article will discuss 6 important issues that are necessary for developing aesthetic implants in the orthodontic patient who is congenitally missing his or her maxillary lateral incisors.

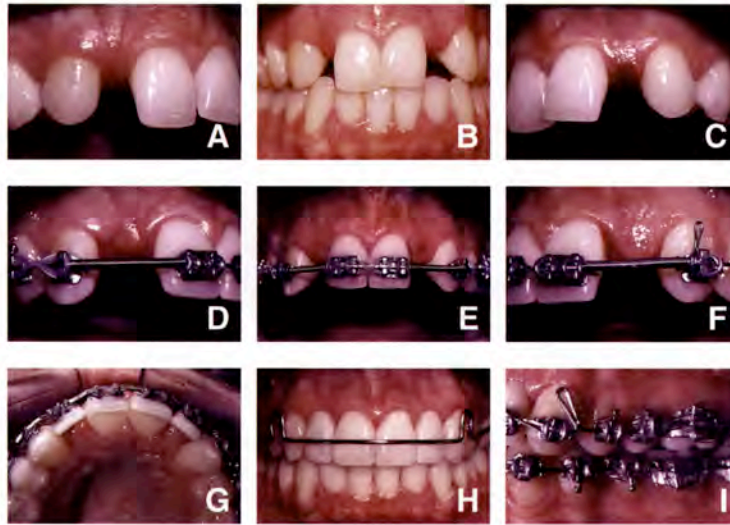
## Adequate Implant Space

If a patient were congenitally missing 1 maxillary lateral incisor, the amount of space for the implant and crown would be determined by the contralateral lateral incisor. However, in some patients the existing lateral incisor may be peg-shaped. In other situations, both lateral incisors are congenitally absent. In the latter instance, what determines the amount of space for the implant and crown? The amount of space is determined by 2 factors: aesthetics and occlusion.

An aesthetic relationship exists between the size of the maxillary central and lateral incisors. The size relationship has been called the "golden proportion."<sup>2</sup> Ideally, the maxillary lateral incisor should be about two thirds the width of the central incisor.<sup>3</sup> Because most central incisors are about 9 mm wide, the width of the lateral incisor space should be no less than 6 mm. Today, the narrowest implants are approximately 3.2 mm in diameter. If the edentulous space were 6 mm wide, approximately 1.4 mm would exist between the implant and the adjacent roots. Previous studies have documented that narrower distances between the implant and the adjacent root are more likely to show a reduction in bone height over time.<sup>4,5</sup> Therefore, at least 1 mm between implant and adjacent root is desirable.

\*Professor, Department of Orthodontics, School of Dentistry, University of Washington, Seattle, WA.

Address correspondence and reprint requests to Dr Kokich: Department of Orthodontics, School of Dentistry, University of Washington, Seattle, WA 98195; e-mail: vggkokich@u.washington.edu  
© 2004 American Association of Oral and Maxillofacial Surgeons  
0278-2391/04/62090204\$30.00/0  
doi:10.1016/j.joms.2004.05.210



**FIGURE 1.** This patient had received orthodontic treatment to create space for lateral incisor implants. For financial reasons, implant placement had been delayed. The patient can now afford implants, but the amount of space is 3 mm on the right and 4 mm on the left (A, B, C). Orthodontic treatment was reinitiated with the goal of creating more space for implants. However, the interproximal surfaces of the canines and central incisors were already flat (A, B). Therefore, enamel was removed from the mesial and distal surfaces of the maxillary first and second premolars to create more space (D, E, F). The amount of space has been increased to 6 mm on each side. Plastic teeth on the archwire (G) and on her retainer (H) are now more proportional to the central incisors and the occlusion still interdigitates properly (I).

Vincent G. Kokich. *Maxillary Lateral Incisor Implants. J Oral Maxillofac Surg 2004.*

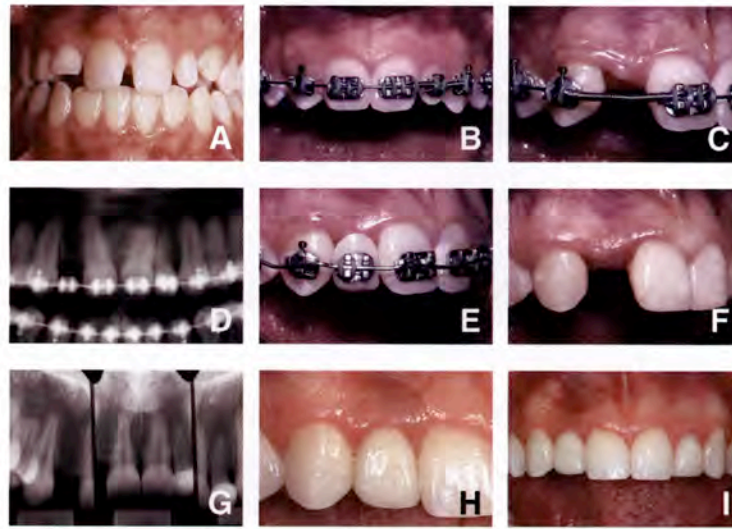
However, in some situations the orthodontist may create less than the ideal width for a lateral incisor implant and crown because of the patient's occlusal relationships (Fig 1). The orthodontist should assess the posterior intercuspation as well as the appropriate amount of overbite and overjet. If the correct occlusion has been achieved, and the space for the implant crown is too narrow (Fig 1), the orthodontist should remove interproximal enamel from the central incisors and canines to provide additional width for the lateral incisor implant. In some cases, if the interproximal surfaces of the canines and central incisors are already flat, the orthodontist must remove enamel interproximally from the premolars. The maxillary premolars generally have tapered crowns with sufficient thickness of enamel so they can be reduced without penetrating the dentin interproximally. By reducing the widths of adjacent anterior or posterior teeth, the orthodontist can create sufficient space for lateral incisor implants.

### Space Between the Roots

Another area where space is an important issue is between the apices of the roots of the central incisor

and canine. Generally, if space has been created for an implant by moving the central and canine crowns apart, the roots of these teeth may have tipped and moved into closer proximity (Fig 2). In the latter situation, there may be inadequate space to fit the implant between the apices of the central incisor and canine roots. During finishing, the orthodontist must move the apices of these roots apart to provide adequate space for the surgeon to position the implant between the roots of these teeth. First, the orthodontist must take a progress panoramic or periapical radiograph (Fig 2). This will show the orthodontist which roots must be relocated. The tooth movement can be accomplished either by repositioning the brackets on the teeth or by making appropriate bends in the orthodontic archwires. Either method will work, but the process takes time. It could require an extra 4 or 5 months to accomplish this type of root movement.

Many former orthodontic patients treated in the 1970s and 1980s who were missing maxillary lateral incisors may have been restored with Maryland or resin-bonded bridges. In these patients, it was not necessary to move the root apices apart. So, many resin-bonded bridge patients will have roots in close



**FIGURE 2.** This patient was congenitally missing the maxillary right lateral incisor (A). After the maxillary arch had been aligned (B), no space was present for an implant. A coil spring (C) was used to open space. However, as the crowns moved apart (C), the roots of the canine and central incisor moved closer together (D). Therefore, the orthodontist placed tip-back bends in the archwire (E) to maintain the space for the crown (F) and move the roots apart to create space for an implant (G). With sufficient space the restorative dentist can create ideal papillary aesthetics (H) adjacent to the implant crown that was stable after 5 years (I).

Vincent G. Kokich. *Maxillary Lateral Incisor Implants*. *J Oral Maxillofac Surg* 2004.

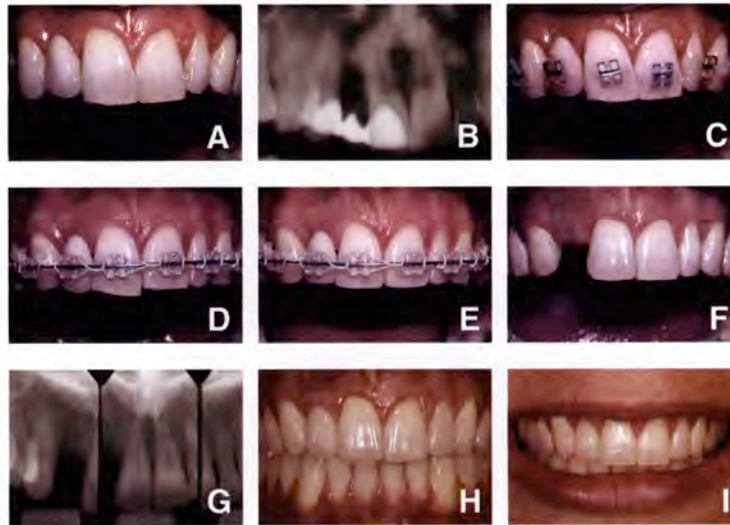proximity (Fig 3). Because resin-bonded bridges have an average life of only 8 to 10 years before they require replacement,<sup>6,7</sup> patients often will request replacement with implants. If the root apices are in close proximity, these patients will require orthodontics to correct their root angulation. However, the length of treatment is usually short, requiring only 4 to 6 months to correct the root angulation, if the occlusion was established properly (Fig 3).

There could be another reason for root proximity after orthodontics. If a patient's orthodontic treatment was completed at a young age, the patient could have significant facial growth remaining. As the maxilla and mandible grow, teeth erupt in response to the increase in vertical facial dimension. If the canine and central incisor roots were placed in an ideal position for implants at the end of orthodontics, the apices could migrate back toward one another in a patient who has significant vertical facial growth, compensatory eruption, and inadequate stabilization of the edentulous space. If patients are immature at the end of orthodontics and will have significant facial growth, it may be appropriate to place a bonded rather than a removable retainer in the lateral incisor edentulous space to prevent reapproximation of the central incisor and canine roots.

### Implant Site Development

When the maxillary lateral incisor is congenitally absent, the permanent canine usually erupts adjacent to the central incisor (Fig 4). This is an ideal situation. As the canine is pushed distally to open space for the maxillary lateral incisor implant and crown, the root movement creates adequate alveolar ridge width mesial to the canine through stretching of the periodontal ligament (Fig 4). This process is called "orthodontic site development." This process can be accomplished in any part of the alveolar ridge, where a tooth will be moved before implant placement. But what happens to the buccolingual width of this bone over time?

That question was answered in a study that evaluated the long-term width of the alveolar ridge after space had been opened for missing maxillary lateral incisors in adolescent orthodontic patients.<sup>8</sup> The sample consisted of 20 patients who were congenitally missing 1 or 2 maxillary lateral incisors. In all cases spaces were created for resin-bonded bridges. Dental casts were available at the end of orthodontic treatment and an average of 4 years after appliance removal. In addition, tomograms of the edentulous ridge were made at the 4-year recall. Maxillary dental



**FIGURE 3.** This patient was congenitally missing the maxillary right lateral incisor and had previous orthodontic therapy to open space for a resin-bonded bridge (A). The bridge is 13 years old, and the patient now prefers a lateral incisor implant and crown. However, the canine and central incisor root apices are too close to permit implant placement (B). Brackets were placed on the tipped teeth (C), the bridge was sectioned, the central incisor crown was uprighted (D) and the incisal edge was equilibrated (E). Treatment lasted approximately 6 months. After bracket removal (F), the relatively minor tooth movement had created sufficient space between the roots (G), so the surgeon could place an implant, and the dentist could restore the implant with normal aesthetics (H, I).

Vincent G. Kokich. *Maxillary Lateral Incisor Implants. J Oral Maxillofac Surg 2004.*

casts also were sectioned across the edentulous ridge. Comparison of posttreatment and long-term measurements of the dental casts and tomographs showed the amount of change that occurred across these edentulous ridges with time. The amount of bone loss in this sample was less than 1% over 4 years. Previous studies have shown that if maxillary anterior teeth are extracted, the alveolar ridge will narrow by 34% over a 5-year period.<sup>9</sup> However, if the edentulous alveolar ridge has been created by orthodontic separation of 2 teeth, little resorptive change will occur over time.

Based on this information, the orthodontist should allow the permanent canines to erupt mesially when maxillary lateral incisors are congenitally absent. As the canines are moved distally, adequate alveolar ridge width will be established for future implants. Over time, this ridge will not resorb as readily as a ridge resorbs after tooth extraction.

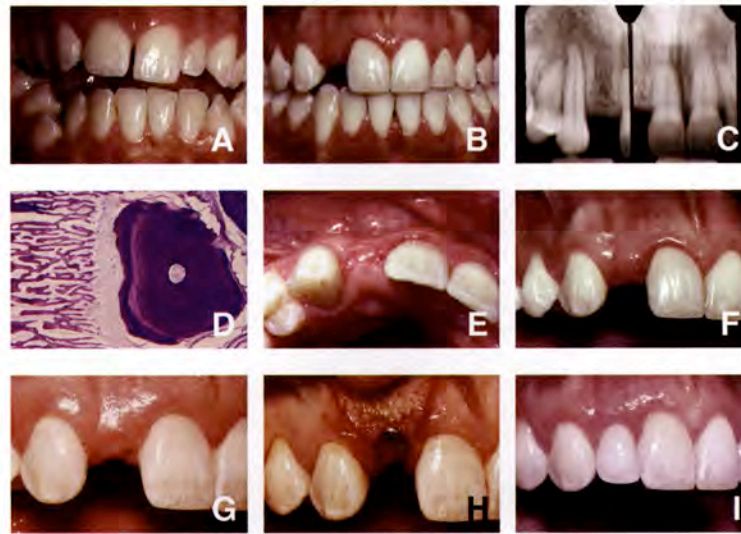
There are several positive outcomes of having an excellent ridge for placing the implant. First, if the ridge width and height are ideal, a bone graft will not be necessary. In these cases, it is not necessary to flap the area a second time to uncover the implant after it has integrated. The implant can be indexed before the flap is reapproximated. This will allow the surgeon to

use a tissue punch to uncover the implant. In addition, the restorative dentist can have the provisional crown ready to place on the implant on the day of uncovering. This distinct advantage affects the appearance of the soft tissues around the implant and leads to a more aesthetic implant restoration.

### Correcting Loss of a Papilla During Space Opening

When the canine erupts adjacent to the maxillary central incisor, there is 1 papilla between these teeth. However, when space is opened for the missing lateral incisor, there must be 2 papillae created (ie, 1 papilla on the distal of the central incisor and another on the mesial of the canine). How does that happen? The answer to this question depends on the age of the patient and the direction of the tooth movement.

If the patient is young and has sufficient growth potential, the formation of a papilla after orthodontic treatment is more predictable (Fig 5). However, if the patient is an adult (Fig 6), there will be no subsequent eruption of teeth after orthodontics. Lack of tooth eruption jeopardizes the formation of papillae after orthodontic space opening.



**FIGURE 4.** This patient was congenitally missing the maxillary right lateral incisor (A). During orthodontics space was opened for an implant (B). The post-treatment periapical radiograph (C) showed the thickened lamina dura on the mesial of the canine and distal of the central incisor roots. A photomicrograph of a root moving toward the right (D) shows how the stretched periodontal membrane facilitates deposition of alveolar bone as the edentulous space is created. Orthodontic site development has created the alveolar ridge (E, F). Four years later (G), the ridge thickness has not narrowed. If an alveolar ridge has adequate width, the implant can be positioned properly (H), which enhances the aesthetic restoration of the implant (I).

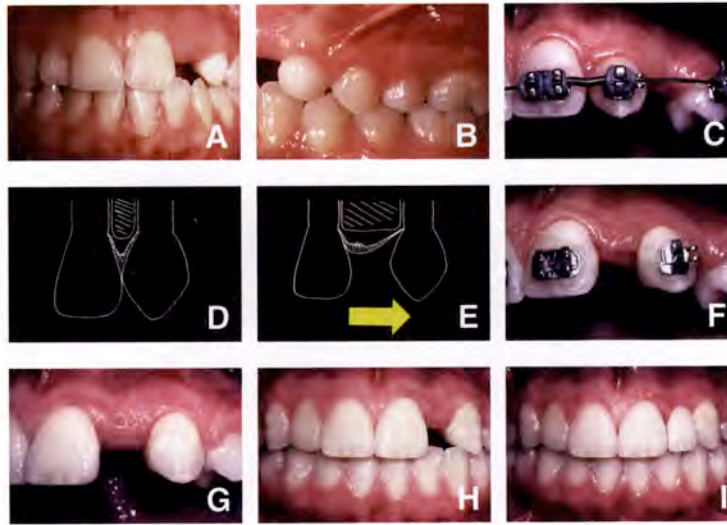
Vincent G. Kokich. *Maxillary Lateral Incisor Implants. J Oral Maxillofac Surg 2004.*

The direction of tooth movement directly influences the development of papillae after orthodontic space opening. As 2 teeth move apart, the interproximal papilla will remain adjacent to the tooth that is not moving. If both teeth move apart equally, the papilla will end up somewhere in the middle of the edentulous space. However, if the canine erupts mesially during facial growth and is pushed distally during orthodontics, the papilla will remain on the distal of the central incisor (Fig 5). As the canine is pushed distally, the mesial gingival sulcus is stretched open, creating a red patch. This is called Atherton's Patch,<sup>10</sup> and the color is red because it is lined with nonkeratinized sulcular epithelium. Over time, in a growing individual, this vertical defect will gradually disappear because of subsequent tooth eruption and redevelopment of a probeable gingival sulcus (Fig 5).

However, in adults, little or no tooth eruption occurs after orthodontic treatment. Therefore, if Atherton's Patch is created after orthodontic treatment, it will not fill in and, at the time of implant placement, it will seem that the orthodontics has somehow destroyed the papilla (Fig 6). Actually, this consequence is inevitable any time 2 teeth are pushed apart in a nongrowing patient. If Atherton's Patch occurs on the mesial of the maxillary canine, the aesthetic compro-

mise is less visible, because it affects a papilla that is positioned farther distally. However, if the orthodontic treatment involves moving the central incisor mesially in an adult patient, then Atherton's Patch will appear on the distal of the central incisor (Fig 6). This will not improve in an adult implant patient, and will compromise the aesthetic appearance after implant placement and restoration unless the appropriate surgical technique is selected.

In this situation, when the labial flap is elevated to place the implant, the mesial extension of the flap should extend to the mesial of the adjacent central incisor. This will allow the surgeon to undermine the flap, and advance it coronally. When the implant is placed, a 2 mm healing cap is placed on the implant, and the flap is advanced over the healing cap. This draws the tissue coronally to recreate the papilla on the distal of the central incisor. Before the flap is advanced, the implant is indexed, so the surgeon and restorative dentist can use a "punch" uncovering technique to uncover the implant after integration. Although there may be other methods of recreating a papilla, this technique predictably creates a papilla in an adult implant patient when Atherton's Patch causes an aesthetic compromise after orthodontic space opening.



**FIGURE 5.** This patient was congenitally missing the maxillary left lateral incisor. The maxillary midline had not shifted (A), and the posterior occlusion was satisfactory (B). A coil spring was used to open space for the implant (C). As the space opened, the papilla remained adjacent to the tooth that did not move (D, E, F). This phenomenon created a depression in the soft tissue at the mesial of the tooth that was disappearing (F). This depression is called the *Atherton's Patch*. Because this patient was young, growing, and erupting her teeth, the *Atherton's Patch* disappeared over time (G, H). When her retainer was placed (I), the papilla levels were even. If the papilla remains on the distal of the central incisor, it is easier to achieve a more aesthetic result.

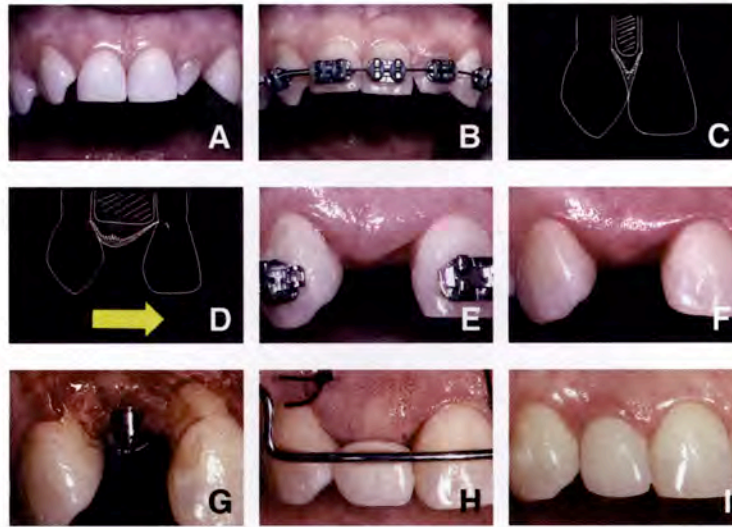
Vincent G. Kokich. *Maxillary Lateral Incisor Implants*. *J Oral Maxillofac Surg* 2004.

### Gingival Surgery for Altered Passive Eruption

At the end of orthodontic treatment, most adolescent patients are between the ages of 14 and 16 years. As a result, their gingival margins may or may not be at an adult level relative to the cemento-enamel junctions of their anterior teeth. If an orthodontic patient is congenitally missing a maxillary lateral incisor, and the adjacent central incisor gingival margin is at its adult level, the surgeon can then use the central incisor as a guide for establishing the vertical position of the lateral incisor implant (Fig 7). However, if the central incisor gingival margin is not at its adult level, the surgeon must adjust for this discrepancy to avoid future problems with gingival margin discrepancies. This problem of gingival margin discrepancy is often called *altered passive eruption*. This description refers to the patient whose bone levels over the central incisors are about 2 mm from the cemento-enamel junctions, the cemento-enamel junctions are at the bottom of the gingival sulci, but the gingival margins are 3 to 4 mm coronal to the cemento-enamel junctions. If the patient has a normal or thick gingival type, it could take several years for the gingival margins to migrate apically to establish a normal 1 mm sulcus.

If these patients are missing their lateral incisors, and will have implants to replace these teeth, altered passive eruption must be corrected before implant placement. In most implant systems, the future gingival margin of the lateral incisor crown determines the vertical position of the head of the implant (eg, the platform of the implant is placed 2 or 3 mm apical to the estimated gingival margin of the implant crown). However, the gingival margin of a lateral incisor must be correctly positioned vertically relative to the adjacent central incisor and canine gingival margins. If the sulcular depth over the central incisor is 1 mm and the cemento-enamel junction is located at the bottom of the gingival sulcus, then this relationship is normal, and will not change significantly over time. Therefore, the surgeon can use the gingival margins of the central incisors as a guide for determining the correct positioning of the platform of the lateral incisor implant (Fig 7).

However, if the patient has altered passive eruption of the maxillary anterior teeth after orthodontic treatment, and the patient has completed facial growth, then the surgeon must first correct the gingival levels with gingivectomy before implant placement (Fig 8). This procedure will insure that the eventual gingival



**FIGURE 6.** This patient was congenitally missing the maxillary right lateral incisor [A]. A coil spring was placed between the right canine and central incisor [B] to create space for the implant. However, her midline had shifted to the right. As space opened, the central incisor moved mesially, so the papilla remained on the mesial of the canine [C, D], and Atherton's Patch was created on the distal of the central incisor [E]. After 1 year [F], this gingival depression did not disappear because teeth are not erupting actively in adults. To eliminate the depression, the surgeon extended the flap mesial to the crown of the central incisor [G], placed a 2 mm healing abutment on the implant [G], indexed the implant, and advanced the flap over the top of the healing abutment [H]. By indexing the implant, it could be uncovered using a punch technique, which also facilitated restoration and re-establishment of the papilla on the distal of the central incisor [I].

Vincent G. Kokich. *Maxillary Lateral Incisor Implants. J Oral Maxillofac Surg* 2004.

margin over the maxillary lateral incisor implant will be at its correct level relative to the adjacent anterior teeth not only after restoration of the implant, but also long-term after implant restoration.

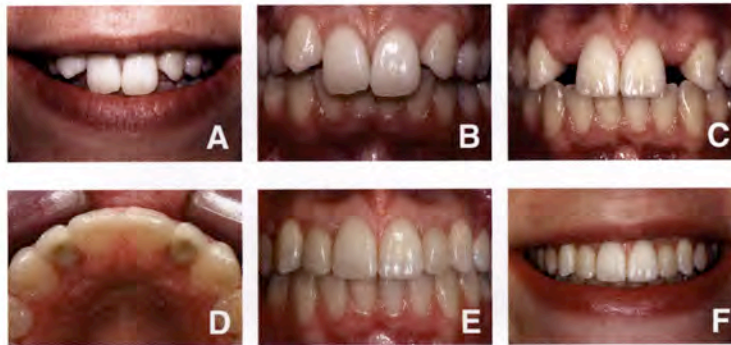#### Determining the Age of Implant Placement

Most orthodontic patients are approximately 14 to 16 years of age at the end of orthodontic treatment. If a male adolescent completes his orthodontic treatment at 15 years of age, and a maxillary lateral incisor is congenitally absent, at what age can the implant be placed? If the implant were placed and restored too early, relative to the patient's tooth eruption, the reaction of the implant will be similar to that of an ankylosed tooth. The adjacent teeth may erupt, and a discrepancy will be created between the gingival margins of the implant and the natural teeth. In a patient with a high lip line, this could be aesthetically unacceptable. For these reasons patients must complete the majority of their tooth eruption before the placement of an implant.

Teeth erupt in response to growth. The question that the orthodontist must answer is whether or not

the patient has completed the majority of his or her facial growth. A hand-wrist radiograph is inappropriate for assessing facial growth, because it is not specific enough for each patient. The best method of evaluating the completion of facial growth is by superimposing sequential cephalometric radiographs.<sup>11</sup> Most boys do not complete their facial growth until the late teenage years. A 14- or 15-year-old boy may not have gone through his adolescent growth spurt. It is advisable to wait until an adolescent male has completed growth in height. At that point, a cephalometric radiograph should be taken. Another radiograph should be taken at least 6 months to a year later. If these radiographs are superimposed, and there are no changes in vertical facial height (nasion to menton), this indicates that most of the facial growth has been completed. If an implant were placed at that time, significant eruption of adjacent teeth would not be expected.

In some girls, the growth of the face is often completed by 15 to 16 years of age. Therefore, it may be possible to place implants for congenitally missing lateral incisors earlier in girls without the risk of eruption of adjacent teeth. However, sequential ceph-



**FIGURE 7.** This patient was congenitally missing the maxillary right and left lateral incisors (A, B). Space was opened orthodontically for 2 lateral incisor implants. At the end of orthodontics (C), the gingival contour over the central incisors was scalloped, the sulcus depth was 1 mm and the width to length proportions of the central incisor crowns was ideal. Because the vertical positioning of the head of the implant is based on the eventual gingival margins of the lateral incisor crowns, the gingival margins over the central incisors and canines must be stable. If so, when the implants are restored (D, E), the relative gingival levels of the natural teeth and implants will be harmonious and appear natural (F).

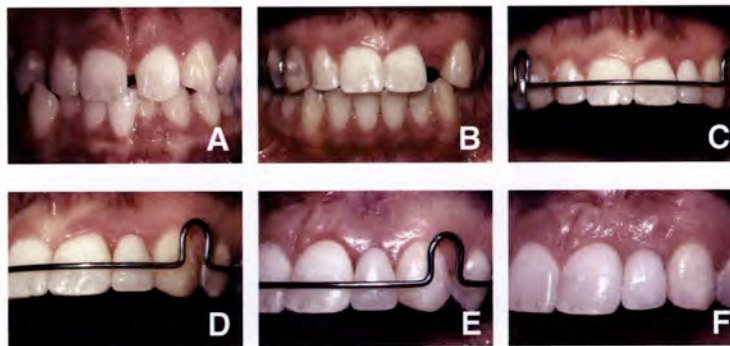
*Vincent G. Kokich. Maxillary Lateral Incisor Implants. J Oral Maxillofac Surg 2004.*

alometric radiographs should be compared to verify that vertical facial growth has ceased (Fig 9).

When does growth cease in adolescents? A study was performed to determine the answer to that question.<sup>12</sup> The sample consisted of 150 males and 150 females who had completed orthodontic treatment. Then, lateral cephalometric radiographs were taken 10 years later on this sample. The ages of the sample allowed the cross-sectional data to be evaluated longitudinally. After this statistical analysis, the average age at which facial growth stops in females is about 17 years and in males it is about 21 years of age. However, these ages are only averages. This informa-

tion does not apply to any specific patient. The surgeon must evaluate superimposed cephalometric radiographs taken at least 1 year apart to verify that facial growth is complete.

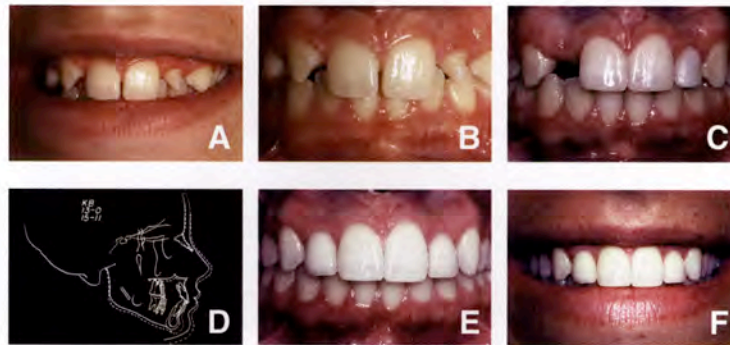
This article has discussed 6 guidelines for managing adolescent orthodontic patients who are missing their maxillary lateral incisors and will require implants to replace these teeth. The space for the crown and implant; the space between the apices of the roots of the central incisor and canine; the possibility of implant site development; the effect of space opening on the integrity of the adjacent papillae; the impact of altered passive eruption; and the method for determining the age



**FIGURE 8.** This patient was congenitally missing the maxillary left lateral incisor (A), and space was opened for a lateral incisor implant (B). The gingival contour over the right and left central incisors was flat (B). The gingival margins of the central incisors were positioned coronal to the right lateral incisor (C). The gingival margin of the lateral incisor implant should be level with the right lateral incisor, but then it would be apical to the gingival margin of the central incisor (D). Excisional crown lengthening of the central incisors was performed before implant placement (E), so the eventual gingival margin of the implant crown (F) would be positioned properly relative to the central incisor crowns.

*Vincent G. Kokich. Maxillary Lateral Incisor Implants. J Oral Maxillofac Surg 2004.*





**FIGURE 9.** This patient was congenitally missing the maxillary right lateral incisor (A, B). During orthodontics, space was opened for a lateral incisor implant (C). However, the patient's mandible grew significantly during orthodontic treatment (D). Successive x-rays of the head taken annually showed that the patient continued to grow for 2 more years, so the implant could not be placed and restored until she was 18 years of age (E). A smiling photograph of the patient 2 years after implant restoration shows that the vertical position of the implant relative to the adjacent teeth has been stable.

Vincent G. Kokich. *Maxillary Lateral Incisor Implants*. *J Oral Maxillofac Surg* 2004.

of implant placement have been discussed in detail. The intent of this article has been to emphasize the importance of interdisciplinary decision-making when planning implants in young adolescent patients who are congenitally missing their maxillary lateral incisors.

#### Acknowledgment

The author wishes to acknowledge the contributions from the other members of the team who helped to treat the patients illustrated in this article. Dr David Mathews performed all of the implant surgeries. The implants were restored by Drs Katherine Crabill, David Hansen, Frank Spear, and Robert Winter.

#### References

1. American Dental Association Council on Scientific Affairs: Dental endosseous implants: An update. *J Am Dent Assoc* 135:92, 2004
2. Lombardi R: The principles of visual perception and their application to dental esthetics. *J Prosthet Dent* 29:358, 1973
3. Rufenacht C: Structural esthetic rules. *in* Rugenacht C (ed): *Fundamentals of Esthetics*. Chicago, IL, Quintessence Publishing, 1992, pp 67-134
4. Esposito M, Ekkestube A, Grondahl K: Radiological evaluation of marginal bone loss at tooth surfaces facing single-tooth implants. *Clin Oral Implant Res* 4:151, 1993
5. Thilander B, Odman J, Grondahl K, et al: Osseointegrated implants in adolescents. An alternative in replacing missing teeth? *Eur J Orthod* 16:84, 1994
6. Creugers N, Kayser A, Van't Hof M: Seven and one-half year survival study of resin-bonded bridges. *J Dent Res* 71:1822, 1992
7. Boyer D, Williams V, Thayer K, et al: Analysis of debond rates of resin-bonded bridges. *J Dent Res* 72:1244, 1993
8. Spear F, Mathews D, Kokich V: Interdisciplinary management of single-tooth implants. *Semin Orthod* 3:45, 1997
9. Carlson G: Changes in contour of the maxillary alveolar process under immediate dentures. *Acta Odont Scand* 25:1, 1967
10. Atherton J: Gingival response to orthodontic tooth movement. *Am J Orthod* 58:179, 1970
11. Kokich V: Orthodontic-restorative management of the adolescent patient. *in* McNamara JA Jr (ed): *Orthodontics and Dentofacial Orthopedics*. Ann Arbor, MI, Needham Press, 2001, pp 425-452
12. Fudalej P: Determining the cessation of facial growth to facilitate implant placement. Master's Thesis. University of Washington, Department of Orthodontics. Seattle, WA, 1998