

Excellence in Finishing: Modifications for the Perio-Restorative Patient

Vincent G. Kokich, DDS, MSD

Orthodontic finishing is a continual challenge for the orthodontist. In some situations, it seems that the teeth simply "fall together" into their correct relationship with little effort on the part of the clinician. However, in other patients, it takes considerable effort and skill to achieve an excellent occlusal result after appliance removal. Furthermore, the increase in adult patients has brought a new challenge to the orthodontist. How should the teeth be positioned if the patient will require minor or major restoration of the teeth after orthodontic treatment? How should the clinician finish the occlusion if the patient has had significant periodontal bone loss before orthodontic therapy? How can the esthetics of a debilitated adult dentition be improved to resemble the nonworn, nonrestored, nonperiodontally involved adolescent dentition? These questions will be addressed in this article that identifies the occlusal, periodontal, and esthetic parameters for orthodontic finishing in the adolescent dentition, and provides useful guidelines for finishing in the adult perio-restorative patient. (Semin Orthod 2003;9: 184-203.) © 2003 Elsevier Inc. All rights reserved.

In the past, orthodontists primarily treated children and adolescents. Although orthodontic "finishing" in these young patients is still a challenge, it is always easier to achieve an excellent result in a patient with all their natural teeth, no restorations, and a young resilient periodontium. Today, however, orthodontists are treating more adults. In some practices, 30 to 40% of the patients are over 25 years of age. Although adults are wonderful patients, they often have underlying periodontal defects, worn/abraded teeth, broken down restorations, missing teeth, uneven spacing, and other periodontal and restorative problems that compromise the "look" of the "well-finished" result. Should we apply the same finishing guidelines or rules to both the dentulous adolescent and the compromised adult patient? Probably not. This article will identify the common occlusal,

periodontal, and esthetic finishing factors for the healthy dentulous patient and explain how these are modified to achieve an excellent finished orthodontic result in the patient with periodontal and restorative complications.

Occlusal Factors

Alignment

Proper alignment of the teeth should be a fundamental objective of any orthodontic treatment plan. However, how does the clinician know when the teeth are properly aligned? What landmarks on the teeth are useful for determining correct intratooth positioning? In an article published by Casco and coworkers,¹ the American Board of Orthodontics (ABO) established guidelines and objective parameters for assessing anterior and posterior dental alignment. In the mandibular anterior sextant, the labioincisal edges of the mandibular incisors and canines are used to establish proper alignment. This surface was chosen since it is the functioning surface of the mandibular anterior teeth, and second because of esthetics. If the labioincisal edges are aligned properly, the teeth look the best esthetically. In

From the Department of Orthodontics, University of Washington, Seattle, WA.

Address correspondence to Dr. Vincent G. Kokich, Department of Orthodontics, University of Washington, Seattle, WA 98194.

© 2003 Elsevier Inc. All rights reserved.

1073-8746/03/0903-0000\$30.00/0

doi:10.1016/s0003-1073(03)00033-1

the maxillary anterior region, the lingual surfaces of the maxillary incisors and canines are used to assess proper alignment. This surface was chosen because it is the functioning surface of the maxillary anterior teeth, and if these surfaces are aligned properly, the maxillary incisors appear to be in their proper esthetic relationship.

In the mandibular posterior sextants, the buccal cusps of the mandibular premolars and molars are used to determine proper tooth position. The cusps should be aligned within whatever arch form the clinician is using. This anatomic landmark was chosen since it represents the functioning surfaces of the mandibular posterior teeth and is easy to visualize intraorally. In the maxillary posterior sextants, the central grooves of the maxillary premolars and molars are used to assess proper alignment. These grooves should lie within the same alignment, depending on the arch form that the clinician is using. This maxillary anatomic landmark was chosen since it represents the functioning surfaces of the maxillary posterior teeth, and is relatively easy to observe intraorally.

These guidelines must be modified slightly when the orthodontist alters the occlusal scheme. One example is when two maxillary premolars are extracted and the patient is finished in an Angle class II molar relationship posteriorly. In this situation, the maxillary first molar actually functions against the mandibular second premolar and not the mandibular first molar. To establish proper contact of the mandibular second premolar buccal cusp with the mesial marginal ridge or mesial fossa of the maxillary first molar, the first molar must be rotated lingually at the mesial surface. This slight modification will facilitate better posterior tooth contact.

Another situation when the posterior alignment must be altered slightly is when mandibular premolars are extracted and the patient's occlusion is finished in an Angle class III occlusion. In this situation, the maxillary second premolar is functioning with the central fossa of the mandibular first molar. Therefore, the maxillary second premolar must be moved slightly buccally, so it will occlude properly with the mandibular first molar. In general, when the occlusal scheme is altered, the mandibular arch is not altered. Compensations in posterior alignment

are typically made in maxillary premolar and molar positions.

In the adult restorative patient, orthodontic alignment is made more complicated when the patient has multiple edentulous spaces. In these situations the type of restoration, ie, bridges or implants, will dictate the tooth position that the orthodontist should achieve. To properly plan for correct tooth positioning, the orthodontist must construct a diagnostic wax-up on adult patients who have multiple edentulous spaces.² Working synergistically with the restorative dentist, the orthodontist will be aware of the restorative requirements and be able to alter tooth alignment to facilitate postorthodontic restorative dentistry.

Marginal Ridges

The marginal ridges are used to assess the proper vertical relationships of the maxillary and mandibular posterior teeth.¹ In the non-worn, nonrestored, nonperiodontally involved adolescent dentition, the marginal ridges are good guides for proper vertical relationships. First of all, if the marginal ridges of adjacent posterior teeth are positioned at the same level, then the cusps of those teeth are also at the same level. Furthermore, if the cusps are at the same level, then the fossae of these teeth are positioned at the same level. Therefore, when the teeth come into occlusal contact, they should occlude with the opposite arch. Most importantly, if the marginal ridges are at the same relative level, then the cemento-enamel junctions are at the same relative level. In this situation, the bone levels between adjacent teeth will be flat, and this produces a much healthier periodontal situation for the patient. So marginal ridges are a good indicator of relative posterior vertical positioning.

In the adult patient with periodontal problems, tooth abrasion, and/or existing restorations, the marginal ridges are not a good guide for posterior vertical tooth position. In these situations, the orthodontist should rely on the bone levels between the teeth to determine the correct vertical position of adjacent teeth.³ This is especially true in the periodontally compromised patient who may have bone loss on one surface that produces a hemiseptal defect be-

tween two teeth (Fig 1). If the patient will have orthodontic treatment to correct the malocclusion, it is advantageous to erupt the tooth with the bone loss during the orthodontics. This will level the bone and reduce the pocket depth and

eliminate the hemiseptal defect. This often requires compensatory occlusal reduction of the affected tooth, so it does not create a prematurity with the opposing arch. However, this is usually not significant, and in many cases the

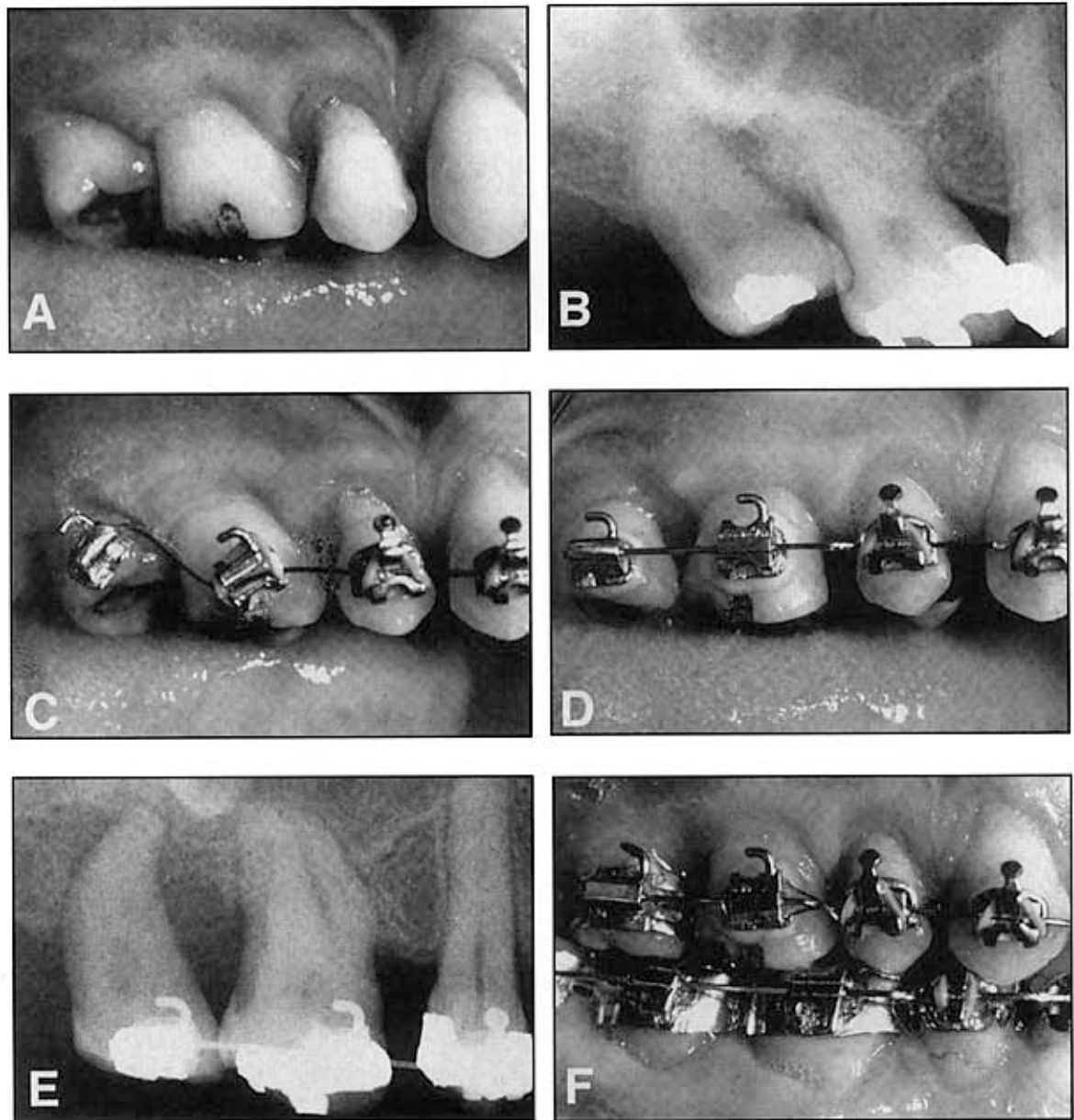


Figure 1. This patient is missing the maxillary right second molar and second premolar (A). As a result, the third molar and first molar have tipped mesially (B). However, the occlusal surface of the first molar is abraded and level with the occlusal plane. Therefore, to upright the tipped teeth, the brackets on the molars must be placed perpendicular to the long axis of the tooth, and not parallel with the abraded occlusal surface (C). As the teeth upright, the marginal ridges and occlusal surfaces are equilibrated (D). The radiograph is used to determine when the posterior teeth are in their correct inclination (E). By placing the brackets in their proper relationship relative to the roots and equilibrating the crowns, the correct occlusal contacts may be established (F).

occlusal reduction involves reshaping of a previous restoration.

Posterior Inclination

The buccolingual inclination of the posterior teeth is assessed by evaluating the relationship between the buccal and lingual cusps of the maxillary and mandibular premolars and molars. This relationship has been called the curve of Wilson. It has been described elsewhere as a gentle curvature with the lingual cusps being positioned slightly more apical than the buccal cusps. In 1999, Casco and co-directors¹ of the ABO defined the limits of the relationships between the buccal and lingual cusps. According to their definition, the lingual cusp should be at the same level or within a millimeter of the same level as the mandibular buccal cusps. If this relationship exists, the occlusal tables of posterior teeth are relatively flat, which permits a much better opportunity for the orthodontist to achieve better contact of the maxillary lingual cusps with the fossae of the mandibular posterior teeth. As the lingual cusps move farther away from the buccal cusps, the occlusal table becomes canted, and occlusal contacts are more difficult to achieve.

In the maxillary posterior region, the palatal cusps of the first and second molars are generally slightly longer and extend slightly more occlusally than the buccal cusps. According to their 1999 article,¹ the ABO regards this as a normal relationship. However if the maxillary palatal cusps extend beyond one millimeter, it becomes increasingly more difficult to achieve proper occlusal contact between maxillary and mandibular posterior teeth without producing cross arch balancing interferences in lateral mandibular excursions.

In the restorative patient, the buccolingual inclination of posterior teeth may affect the restorative dentist's ability to restore the posterior teeth. This is especially true in the patient who has a missing mandibular first molar, where the mandibular second molar has tipped mesially into the edentulous site. In this situation, if the orthodontist will be uprighting the tipped second molar for future bridge replacement, the buccolingual position of the second molar is critical. When teeth are uprighted on round archwires, there is a tendency to cause the lin-

gual cusps of the mandibular molars to move apically relative to the buccal cusps. If this occurs, and is not corrected by the orthodontist, the crown preparation of the second molar will have to be modified to draw with the second premolar abutment. If the additional reduction of the second molar is extensive, it could drastically reduce the retention of the bridge abutments. In these situations, it is better to leave the occlusal table of posterior bridge abutments in a flat relationship buccolingually, so the preparation of adjacent teeth for bridge abutments will produce the maximum retention and draw for the eventual bridge.

Anterior Inclination

The overall inclination of the maxillary anterior teeth is best evaluated with a lateral cephalometric radiograph. Accepted norms and ranges of variability have been established in previous studies. However, another aspect of anterior inclination relates to the relative inclination of the maxillary and mandibular incisors. The maxillary and mandibular central and lateral incisors should be in the same relative plane compared with one another. Occasionally they are in different planes, and this can cause relapse of incisor irregularity after removal of orthodontic appliances. During finishing, it is possible to determine if this alteration in inclination exists, by evaluating four criteria.

If one suspects this problem, the first criterion to evaluate is the incisal edges of the anterior teeth. If a discrepancy exists in anterior inclination, the incisal edges of the anterior teeth will not be in the same plane. Even inseting or offsetting the incisors relative to one another will not correct the problem. A second criterion to evaluate is the clinical crown length of contralateral teeth. Without incisal wear, trauma, or restorations, the clinical crown length of contralateral teeth should be the same length. However, if contralateral teeth are different lengths, the cause could be relative discrepancies in the inclination of contralateral incisors. As incisor root apices are inclined more lingually, the labial bone level could be positioned nearer the cemento-enamel junction on that tooth. If this occurs, then the gingival margin will be positioned more incisal as well.

The third criterion to evaluate is root promi-

nence. If one incisor is inclined differently than an adjacent incisor, the root will be less prominent. This may be discovered easily by palpating the root prominences of the anterior teeth. A depression in the alveolus will indicate the tooth root that is inclined improperly. The fourth and final criterion is best evaluated from an occlusal perspective. When the incisors are viewed from an occlusal perspective, the cingulum of an improperly inclined incisor is more prominent or more visible.

The correction for improper root inclination may be accomplished in different ways. If the clinician is using a rectangular arch wire, the torque of the arch wire can be modified to produce a change in the root angulation. Other methods for altering tooth inclination include auxiliary springs and attachments that can be applied with a round arch wire. The time necessary to make a change in incisor root inclination depends on two factors. First is the difference in root inclination, and the second is the length of the root that must be moved. The greater the discrepancy, and the longer the root, the farther it must move, and the longer time it will take to accomplish the movement.

Improper root inclination can also affect the restorative patient. A good example of this problem is the patient who is congenitally missing both maxillary lateral incisors, and has a maxillary arch length excess of about five millimeters. If the patient has no crowding in the mandibular arch, an Angle Class I occlusion, and an acceptable lateral facial profile, the treatment plan could involve opening space for two lateral incisor replacements. In this situation, the maxillary anterior dental arch must be expanded by about 6 to 7 mm to create sufficient space for implants or pontics for the missing lateral incisors. However, if the clinician does not manage the relative inclination of the anterior teeth carefully, then several of the options for replacing the missing lateral incisors may not be possible.⁴

First, if the canines and central incisors are proclined significantly relative to one another, then a conventional bridge will be difficult to accomplish. A conventional bridge must have "draw and retention," after the teeth have been prepared. If the teeth are proclined relative to one another, then the teeth must be reduced excessively, to establish "draw" between abutments. If the teeth must be reduced signifi-

cantly, then retention of the bridge will be compromised. In addition, if the abutments are significantly inclined, and must be drastically reduced to permit the preparations to draw, then the pulps of the teeth could be exposed during the preparation process. This problem could require root canal therapy.

If a resin-bonded bridge is chosen as the restorative option for the patient who is missing both maxillary lateral incisors, significant inclination of the maxillary centrals or canines will reduce the retention of a resin-bonded bridge, and result in frequent debonding of the metal framework. The best direction of force on an anterior abutment for a resin-bonded bridge is parallel to the inclination of the tooth, thus producing a shear force on the resin-bonded metal connector.⁴ This requires that the abutments for the resin-bonded bridge be oriented vertically within the alveolus and perpendicular to the force of occlusion. This will produce a shear rather than a tensile force during mastication. So, if maxillary anterior teeth are proclined excessively relative to one another, retention of a resin-bonded bridge will not be predictable.

Another option for replacing missing maxillary lateral incisors is implants. However, implants require sufficient space between the roots. This requirement is usually possible if the maxillary central and lateral incisors are in the same relative inclination. In this situation, root apices will diverge sufficiently from one another permitting space for the implant between the roots. However, if the crowns of the maxillary central and canine are proclined relative to one another, then the apices of the roots of these teeth actually tend to approximate one another. This tendency is called the "wagon-wheel effect," and could prevent the placement of implants if the inclination problem is severe enough, or if the roots are long enough.

If a patient were missing maxillary lateral incisors, and space must be opened for replacements due to profile and existing occlusion, and the tendency for improper root inclination is unavoidable, then the only restoration that may be possible in this situation is a pin-ledge cantilever bridge, restoring the maxillary canine with a bonded or pinned restoration, with a cantilevered lateral incisor pontic.

Overbite

Overbite is defined as the distance from the incisal edges of the maxillary central incisors to the incisal edges of the mandibular central incisors. The purpose of overbite is to permit the anterior teeth to function or incise food in protrusive jaw position, while the posterior teeth are out of occlusal contact. Therefore, the amount of overbite necessary to accomplish the task of discluding the posterior teeth is actually determined by the length of the cusps of the premolars and canines.

Some premolars have shallow cuspal anatomy, and therefore the overbite required to disclude this type of tooth anatomy would be small, perhaps one to two millimeters. However, some patients have long cusps on the maxillary and mandibular premolars and canines. In this situation the anterior overbite must be greater, perhaps 3 to 4 mm, to disclude the posterior teeth. If the overbite is not deep enough, then the patient would only contact the posterior teeth in protrusive jaw position, making it impossible to incise food.

The amount of overbite has some effect on anterior restorative dentistry, especially the placement of a resin-bonded anterior bridge. Previous studies^{5,6} have shown that retention of an anterior resin-bonded bridge is partially determined by the size of the bonded metal connector on the lingual surfaces of the maxillary canine and central incisor. If the patient requires an anterior resin-bonded bridge, and the anterior overbite is needlessly finished deeper than necessary to disclude the posterior teeth in protrusive jaw position, then less surface area on the lingual of the maxillary anterior teeth will be covered by the metal connector. In this situation, the resin-bonded bridge will have a greater tendency for bond failure.

Overjet

Anterior overjet is defined as the distance between the labial incisal edges of the maxillary incisors and canines and the lingual surfaces of the maxillary incisors and canines. It has been stated by the American Board of Orthodontics¹ that anterior overjet should be zero, or in other words, the maxillary and mandibular anterior teeth should contact, when the posterior teeth

are brought into occlusion. Presumably, if the anterior teeth were in contact in occlusion, then their vertical position would be more stable. However, this is only theory and has not been proven.

Occasionally an orthodontic patient may require a full crown on one or both of the maxillary central incisors, or a three-unit conventional bridge to replace a missing central incisor (Fig 2). If adjacent teeth are not restored, there will be a difference in the labiolingual thickness of the restored and the nonrestored incisors. In these situations, the orthodontist should leave about two-thirds to three-quarters of a millimeter of overjet during orthodontic finishing.⁷ When the dentist restores the teeth, the increased thickness of the crowns and/or bridge will fill-in the anterior overjet and establish contact with the mandibular incisors. In this way, the labial surfaces of the restored and nonrestored teeth will be related properly to one another. However, there will be overjet remaining on the nonrestored incisor. This space is eliminated by etching the lingual surface of this tooth and adding composite to increase the labiolingual thickness of the tooth and establish contact with the mandibular incisors.

Another situation where overjet must be produced during orthodontic finishing is in the patient who has significant tooth abrasion or erosion of the labial surfaces of the mandibular incisors or lingual surfaces of the maxillary anterior teeth (Fig 3). As teeth wear, they usually erupt to maintain contact with the opposing arch. If abraded or eroded teeth are finished in occlusion with the teeth in contact, there will be no space for the dentist to restore the abraded or eroded surfaces. In these situations, the method of creating the space often involves intrusion of the eroded or abraded incisors to create the overjet. The restoration of these teeth usually requires two steps. After tooth intrusion, a bonded composite restoration is placed on the abraded surface to re-establish contact with the opposing arch. Then, after the tooth position has been stabilized during orthodontic retention, the final restoration will replace the temporary composite.

Occlusal Contact

In the posterior sextants, the adequacy of tooth interdigitation is assessed by evaluating the con-

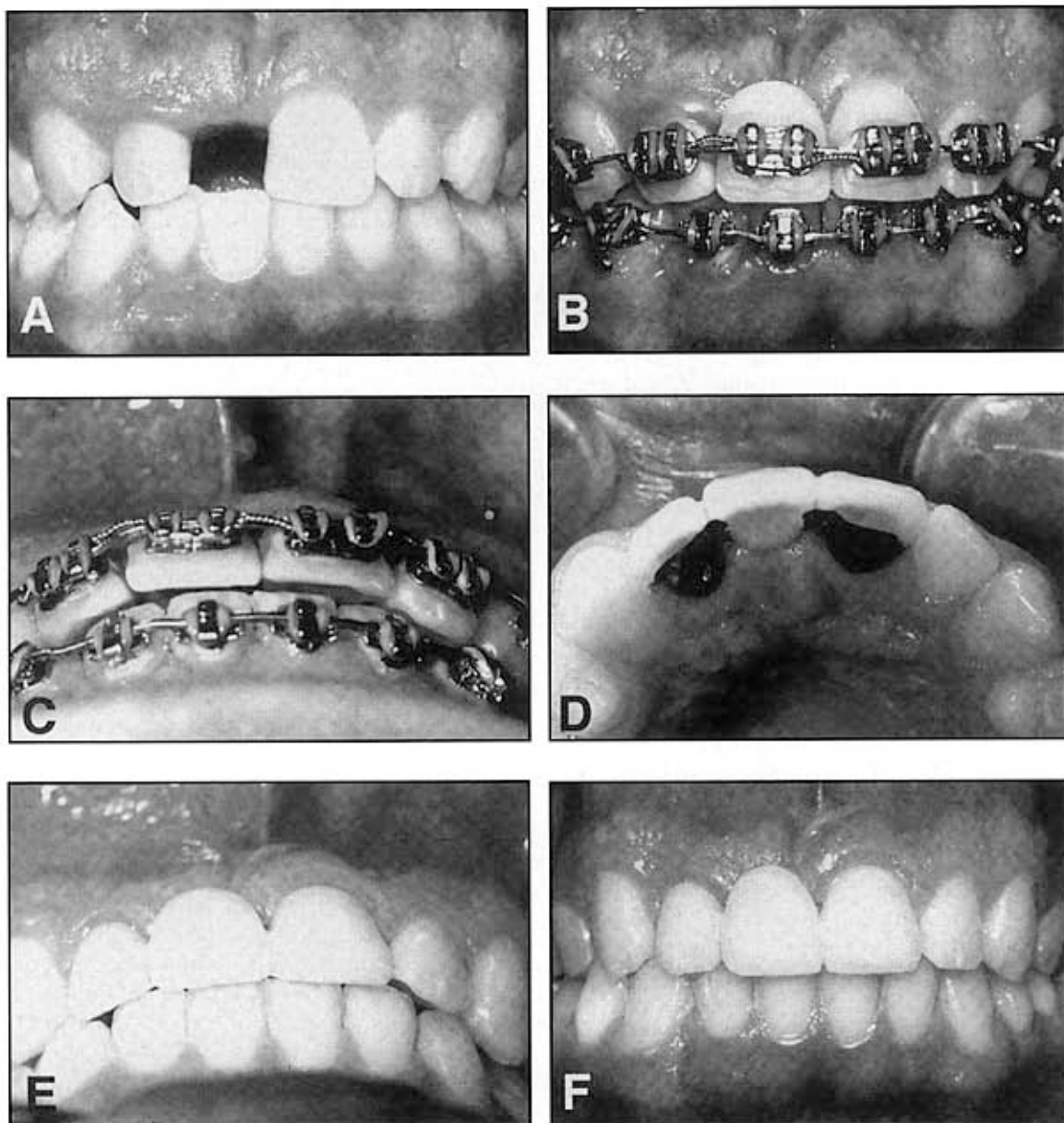


Figure 2. This patient avulsed the maxillary right central incisor in an accident (A). The left central and right lateral have also had root canal therapy and have major incisal fractures requiring eventual crowns. The choice for restoration of the edentulous space will be a three-unit bridge from left central to right lateral incisor. During orthodontic finishing (B, C), it is important to leave one-half to two-thirds of a millimeter of overjet. This will permit the restorative dentist to maintain the correct labial relationship of the bridge with the nonrestored maxillary left lateral incisor (D). The increased thickness of the crowns and pontic are placed lingually, so they contact with the mandibular arch (E). The space between the maxillary lateral incisor and the mandibular incisors is filled-in with composite, so all teeth contact in occlusion (F).

tact relationship between the cusps and fossae of the molars and premolars. The buccal cusps of the mandibular premolars and molars should contact the fossae or marginal ridges of the maxillary molars and premolars.¹ In addition, the

lingual cusps of the maxillary premolars and molars should be in contact with the marginal ridges or fossae of the mandibular premolars and molars.¹ The exceptions are the lingual cusps of the maxillary first premolars, which may

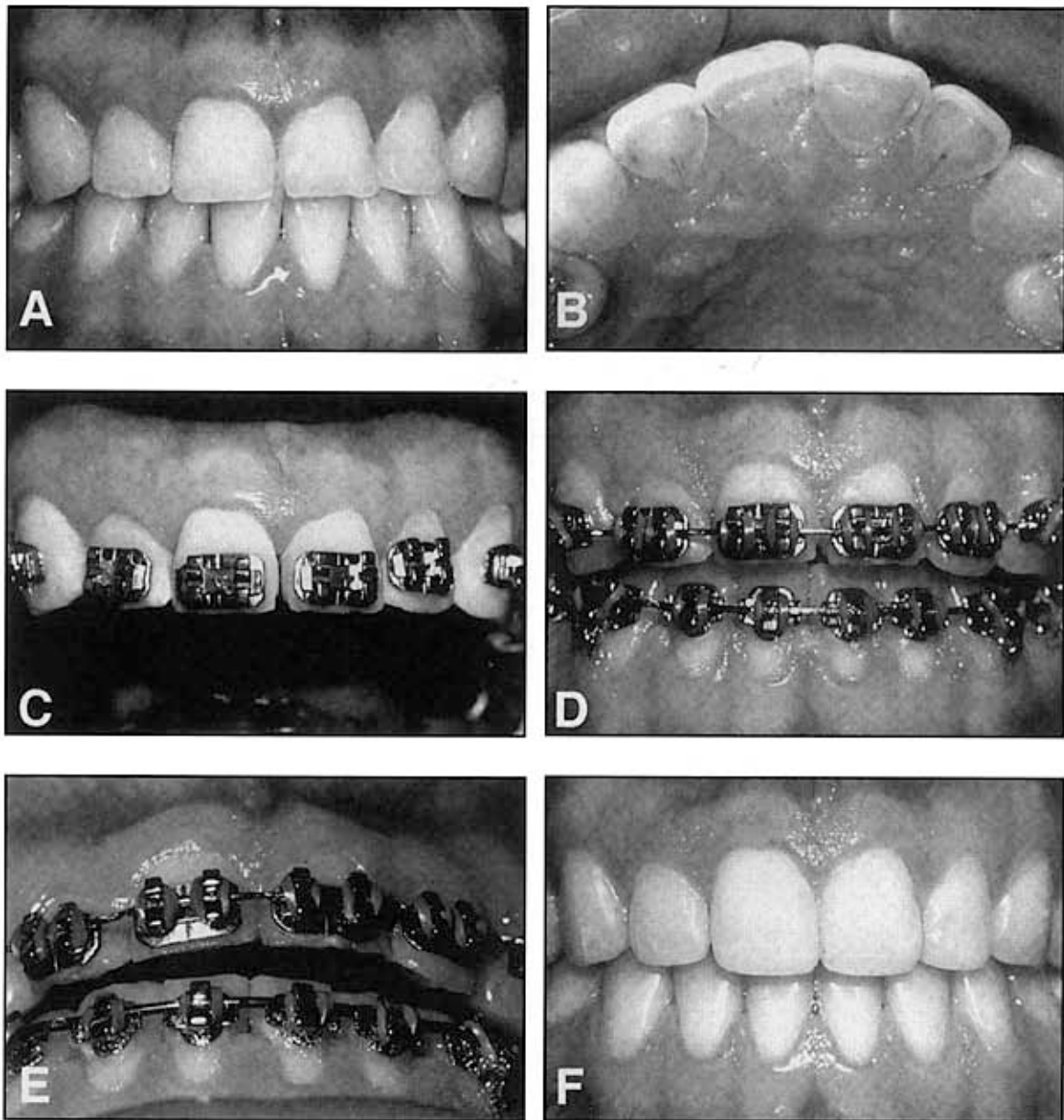


Figure 3. This patient is a bulimic. She has experienced severe erosion of the lingual surfaces of the maxillary incisors, resulting in overeruption of the maxillary incisors (A, B). The restorative dentist needs overjet to restore the eroded lingual surfaces. In these situations, it is possible to create the overjet by placing the brackets nearer the maxillary incisal edges (C), and intruding the central and lateral incisors (D). After intrusion (E), there is sufficient space to restore the lingual surfaces without removing any further tooth structure (F).

not establish contact with the mandibular first premolar because of the lack of an adequate occlusal table. In addition, the distolingual cusps of the maxillary first and second molars may not contact the mandibular teeth if the cusps are diminutive in size.

However, in situations where posterior teeth

have worn significantly and will be restored with full crowns after orthodontic treatment (Fig 4), it may not be advantageous to establish contact at the end of orthodontic treatment. If contact is established and the tooth has worn significantly, it will still have to be reduced another 2 to 3 mm as the restorative dentist creates space for the

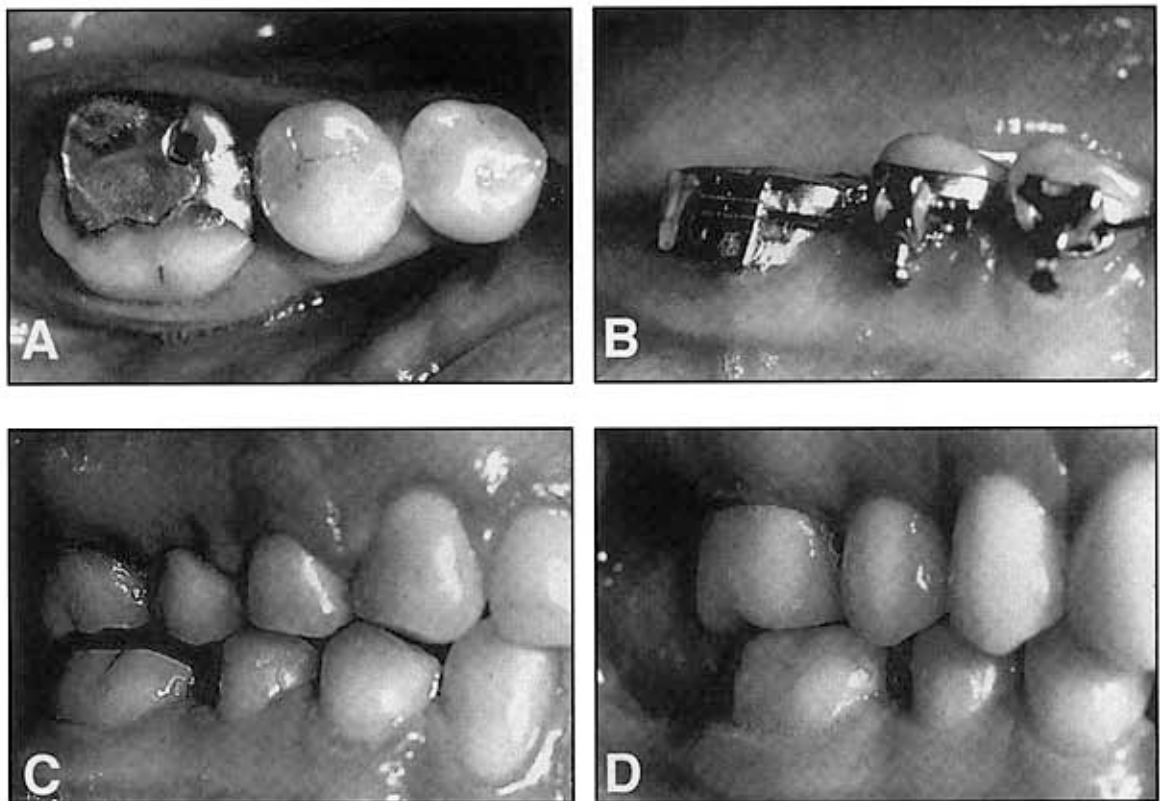


Figure 4. The mandibular right first molar has a large occlusal restoration, and the occlusal surface has abraded significantly (A). However, the tooth is in occlusal contact with the maxillary teeth. This tooth will eventually require a porcelain or gold crown after orthodontic therapy. If the occlusal contact is maintained, the dentist will have to reduce the occlusal surface further to create space for gold and/or porcelain, and the tooth would require crown lengthening. However, in this case, the molar was intruded about 2 mm (B, C). When the final restoration was placed, the dentist only prepared the proximal surfaces, which enhanced the retention of the final crown (D).

gold or porcelain of the final crown. If the tooth is reduced farther, there may not be sufficient preparation length to achieve adequate retention of the final restoration. These teeth could require periodontal crown lengthening to overcome this dilemma. However, the orthodontist could ameliorate the problem during the orthodontic treatment by intruding the abraded and overerupted tooth, thus creating an open contact between this tooth and the opposing arch. This eliminates the need for the restorative dentist to reduce the occlusal surface of the abraded tooth, which will result in adequate length of the axial walls of the tooth preparation, and enhance the retention of the restoration. After the abraded molar has been intruded, then it must be held in that position with a provisional crown or composite build-up of the occlusal surface, before final restoration.

Periodontal Factors

Root Angulation

During finishing, orthodontists typically use a panoramic radiograph to determine if the roots of the teeth are oriented properly relative to adjacent roots. In theory, if the roots of adjacent teeth are perpendicular to the occlusal plane, and parallel with one another, then there will be sufficient bone between the roots of teeth. In this way, if the patient should develop periodontal disease at some later time, it is assumed that more interproximal bone will provide greater resistance to periodontal bone loss. However, some important aspects of root angulation must be discussed. First of all, is a panoramic radiograph an accurate depiction of the root angulations of adjacent teeth? Researchers have evalu-

ated this question⁸⁻¹² and conclude that there are distortions produced with a panoramic radiograph, especially in the maxillary and mandibular canine/first premolar regions, where the archform curves. However, recognizing these minor inadequacies, the panoramic radiograph is probably a reasonable screening tool in general. In specific situations, it is beneficial to take supplemental periapical radiographs to accurately assess root angulations and root proximity.

A second aspect that requires discussion is whether close root proximity will actually cause detrimental long-term effects. This question was investigated, and the authors^{13,14} concluded that close root proximity did not produce detrimental effects in their sample. These authors cautioned that their sample was relatively young, and was not a sample of patients that were susceptible to periodontal disease. Whether or not close root proximity enhances interproximal bone destruction in a sample of periodontal patients is not known.

However, close root proximity after orthodontic treatment will cause problems in certain restorative patients. If the roots of anterior teeth are in close proximity, and the patient will have full crowns or veneers placed after orthodontic therapy, it may be difficult for the dentist to obtain an adequate impression of the gingival margins of adjacent tooth preparations. It may be difficult for the restorative dentist to pack impression cord into the sulcus if the adjacent tooth root is in close contact in the cervical region of the tooth preparation.

Another restorative situation where root angulation is important is in the single-tooth implant patient. When a patient is congenitally missing the maxillary lateral incisor and the eventual restoration will involve the placement of a single-tooth implant (Fig 5), it is important that the orthodontist create sufficient space between the roots of the central incisor and ipsilateral canine. This type of tooth movement may require several months of adjustment to establish adequate space for the implant.

Bone Level

In adolescent patients, orthodontists should not be concerned with evaluating the bone levels between adjacent teeth. First of all, adolescents

generally do not have periodontal disease that could result in bone destruction around adjacent teeth. Therefore, the orthodontist should align the incisal edges of nonworn, nonrestored anterior teeth and the marginal ridges of nonworn, nonrestored posterior teeth, and in this way the cemento-enamel junctions and interproximal bone will be at the appropriate level.

In adult patients with prior periodontal disease and interproximal bone loss, the incisal edges or marginal ridges of the teeth are not reasonable guides for vertical positioning of adjacent teeth.³ If the patient has horizontal bone loss in the maxillary or mandibular anterior regions (Fig 6), it is best to align the bone levels rather than adjacent teeth. In these situations, the orthodontist must equilibrate the incisal edges as the bone is leveled to establish the correct incisal edge position, occlusion, and crown-to-root relationships.

Esthetic Factors

Crown Width

Most orthodontic patients have maxillary central and lateral incisors that have symmetric dimensions, both in width and length. However, occasionally, one or both lateral incisors are narrower than normal and could require restoration after orthodontic therapy. Where should the malformed lateral incisor be positioned to achieve the best esthetic result? The position often depends on the shape of the tooth.

Malformed laterals generally have two different shapes. Some are cone-shaped, and others resemble the shape of a normal lateral incisor, but are significantly narrower, thinner, and shorter. If a lateral incisor is only slightly narrower than normal, and the problem is bilateral, the orthodontist may decide not to provide space to restore the tooth during orthodontic treatment. If the width discrepancy is only slight, the influence on the anterior occlusion, and the impact on esthetics may be indistinguishable.¹⁵ However, if the malformation is unilateral, or if the width discrepancy is significant, esthetics and occlusion could be adversely affected if the malformed tooth or teeth are ignored.¹⁶⁻¹⁸ Before the advent of composite bonding, restorative treatment of malformed maxillary lateral

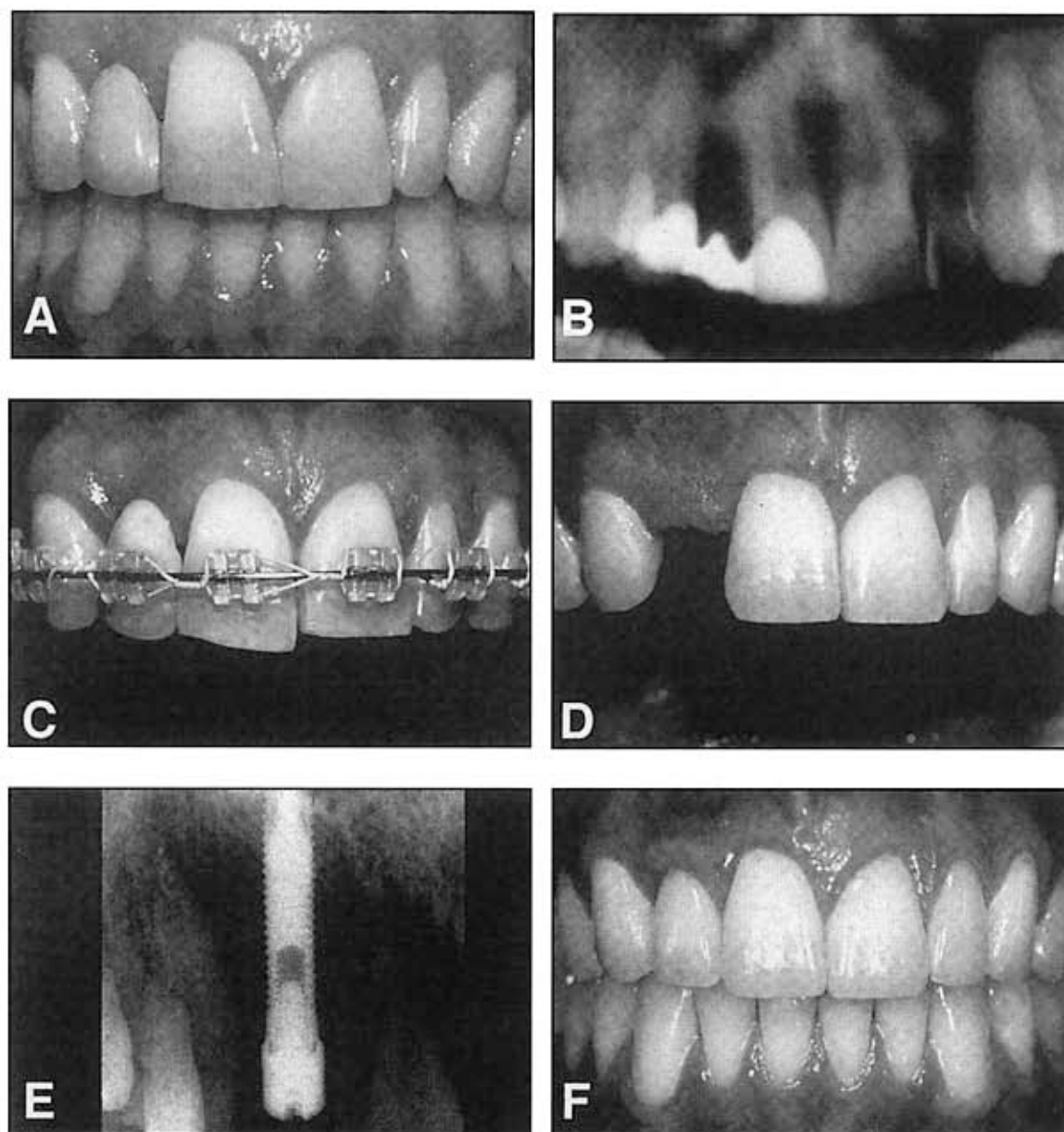


Figure 5. This 28-year-old patient had orthodontic therapy at 15 years of age to open space for a resin-bonded bridge to replace her congenitally missing maxillary right lateral incisor (A). Now she wants the space restored with an implant. However the original orthodontics did not align the roots properly, and insufficient space exists for the implant (B). Therefore, she required a second phase of orthodontics (C) to upright the roots (D), so the implant could be placed (E), and the missing tooth could be restored properly (F).

incisors was much more challenging, and required a full-crown to enlarge the size of the malformed tooth. However, in an adolescent orthodontic patient with a large pulp chamber, the risk of irreversibly damaging the pulp is substantial if a full-crown were attempted. Bonding has permitted much more conservative res-

toration without extensive preparation of the lateral incisor. Either composite or porcelain veneer restorations, or complete composite or porcelain crowns may be bonded to the enamel with minimal tooth reduction. However, the orthodontist must position the malformed tooth in the proper position to facilitate ideal restoration.

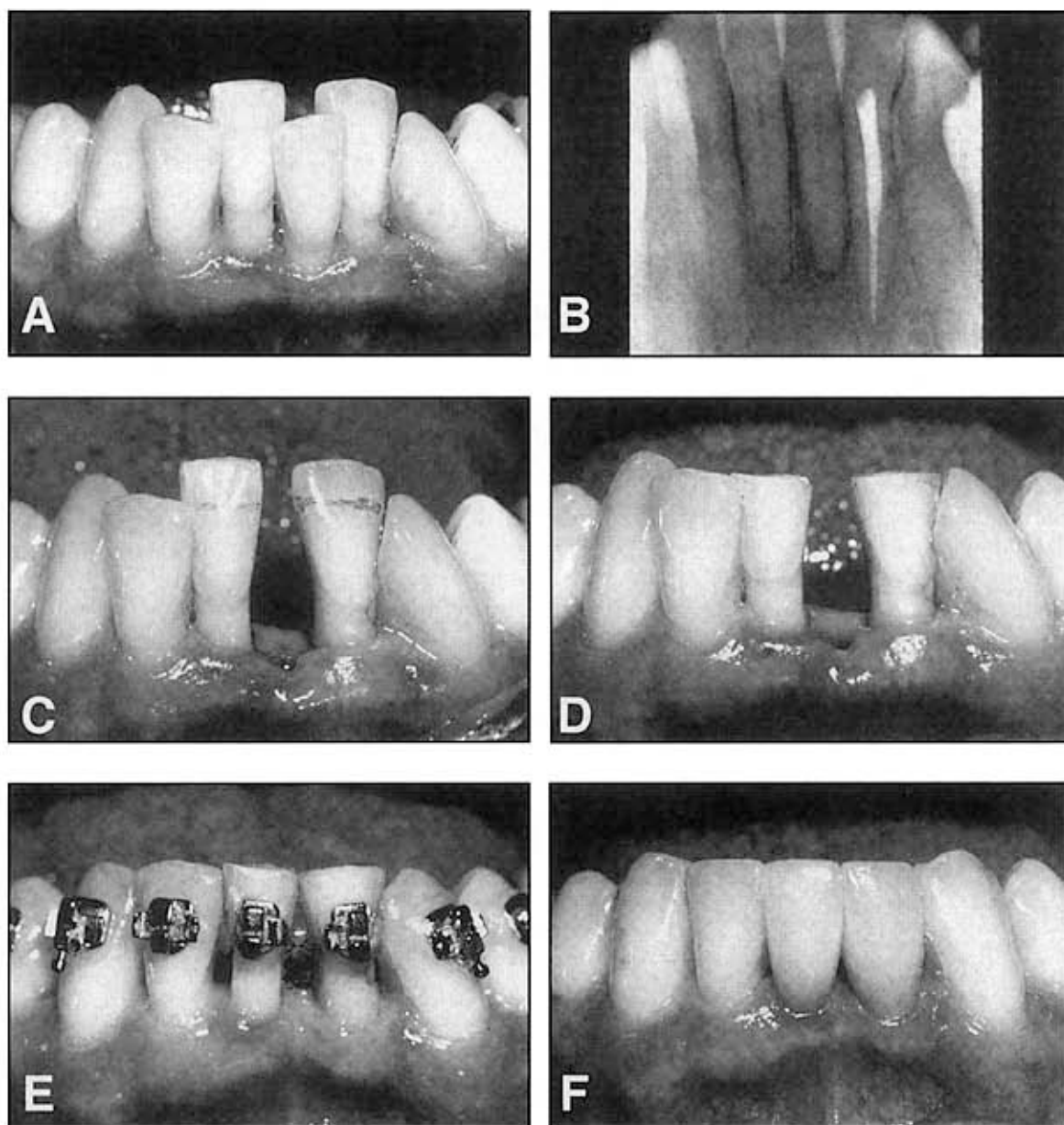


Figure 6. This 63-year-old school teacher wants her crowded mandibular anterior teeth aligned (A). However, she has lost significant bone around the incisors (B). If the incisal edges of the teeth were used as a guide to position the teeth orthodontically, this would perpetuate a poor crown to root ratio and result in very mobile teeth. In this situation, it is best to maintain the level of the bone and equilibrate the incisal edges (C, D). By reducing the length of the teeth, the mobility is reduced, and the teeth are easily aligned (E) and restored (F).

If the malformed lateral incisor is merely narrower, thinner, and shorter than the contralateral incisor, the final restoration will probably be a composite or porcelain veneer. In this situation, the orthodontist must position the tooth precisely before restoration. If sufficient space exists, a composite restoration may be placed

before orthodontic treatment. However, in most situations, there is insufficient space to restore the malformed lateral incisors. Therefore, orthodontics is often necessary to create space to build-up malformed lateral incisors.^{7,10}

The orthodontic mechanics to open space mesial and distal to the lateral incisor are rela-

tively simple (Fig 7). Compressed coil springs are placed between the central incisor, lateral incisor and canine, to push the central and canine away from the lateral incisor. Space will be generated in a few weeks. As space is created, four questions must be answered. First, how much space is required to restore the lateral incisor? If the patient is congenitally missing the opposite lateral incisor, a diagnostic wax-up should be constructed. This will determine the correct size for the restoration of the peg-shaped lateral incisor. If the patient has an existing lateral incisor of normal width on the opposite side, it is appropriate to create the same amount of space. Occasionally, it is advantageous to create extra space temporarily. This will allow the restorative dentist to contour and polish the interproximal surfaces of the temporary composite restoration, so that it matches the width of the opposite lateral. Any residual space may be closed after the restoration has been placed.

When creating space orthodontically, a second question arises. Where should the maxillary lateral incisor be positioned mesiodistally relative to the central incisor and canine? If the lateral incisor is positioned too close to the canine, the mesial surface of the lateral must be overcontoured to achieve the appropriate crown width. The result could be unaesthetic. The emergence profile or contour of the mesial surfaces of lateral and central incisors is relatively flat. The distal surfaces of central and lateral incisors are more contoured or convex. Therefore, the peg-shaped lateral incisor should be positioned nearer the central incisor than the canine during orthodontic treatment (Fig 7).

Where should a lateral incisor be positioned buccolingually: toward the labial, in the center of the ridge, or toward the lingual? The answer to this question depends on the type of permanent restoration that will eventually be constructed for the tooth. In most cases, during

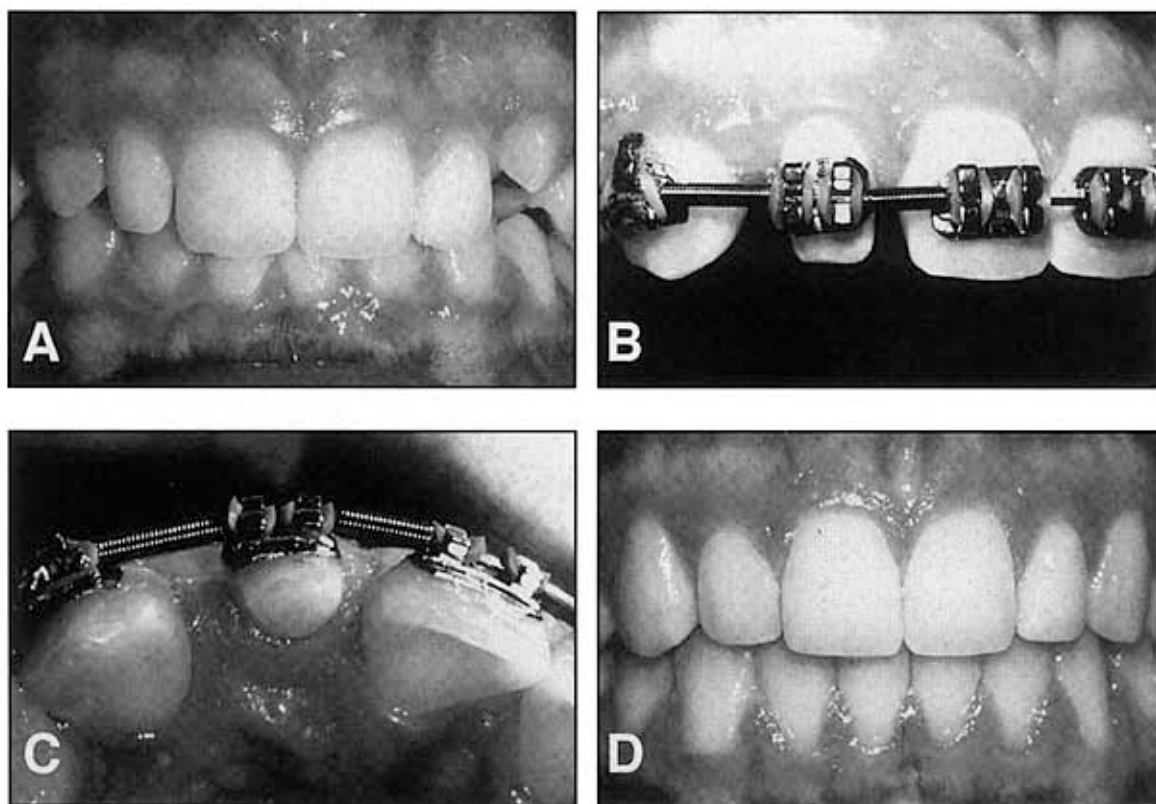


Figure 7. The maxillary right lateral incisor is 2 1/2 mm narrower than the left lateral incisor (A). During orthodontic therapy, extra space is opened between the central incisor and canine (B) so the tooth can be properly restored. The lateral is positioned nearer the central (C) and toward the lingual (C), while the gingival margin is aligned with the contralateral lateral incisor, so the final restoration will be inconspicuous (D).

orthodontic treatment, a temporary composite build-up is placed on a peg-shaped lateral incisor. However, eventually, this tooth may be restored with either a porcelain veneer or a porcelain crown. If the eventual restoration will be a porcelain crown, the lateral incisor should be positioned in the center of the ridge buccolingually, leaving 0.50 to 0.75 mm of overjet. This will avoid additional tooth preparation of the lingual of the lateral and permit space for gold and/or porcelain in the final restoration. However, if the final restoration will be a porcelain veneer, then the peg-shaped lateral should be positioned lingually to contact the mandibular incisors in centric occlusion (Fig 7). This will allow sufficient space on the labial to construct both the temporary composite build-up and the eventual porcelain veneer.

Finally, where should the lateral incisor be positioned incisogingivally? This relationship is determined by the relative positions of the gingival margins. Most peg-shaped lateral incisors are not only narrower mesiodistally and buccolingually, they are also shorter than normal lateral incisors incisogingivally. If the incisal edge is aligned with the opposite lateral incisor, the crown could be too short. Therefore, the gingival margins of the peg-shaped lateral should be aligned with the contralateral lateral incisor. The restorative dentist will restore proper length, width, and thickness of the tooth, when the temporary composite build-up and final restoration are constructed (Fig 7).

Gingival Levels

The relationship of the gingival margins of the six maxillary anterior teeth plays an important role in the esthetic appearance of the crowns.²⁰⁻²⁵ Four characteristics contribute to ideal gingival form. First, the gingival margins of the two central incisors should be at the same level. Second, the gingival margins of the central incisors should be positioned more apically than the lateral incisors and should be at the same level as the canines. Third, the contour of the labial gingival margins should mimic the cementoenamel junctions of the teeth. Last, there should be a papilla between each tooth, and the height of the tip of the papilla is usually halfway

between the incisal edge and the labial gingival height of contour over the center of each anterior tooth. Therefore the gingival papilla occupies half of the interproximal contact, and the adjacent teeth form the other half of the contact.

However, some patients may have gingival margin discrepancies between adjacent teeth. These discrepancies could be caused by abrasion of the incisal edges or delayed migration of the gingival margins. When gingival margin discrepancies are present, the clinician must determine the proper solution for the problem: orthodontic movement to reposition the gingival margins or surgical correction of gingival margin discrepancies.

To make the correct decision, it is necessary to evaluate four criteria. First of all, the relationship between the gingival margin of the maxillary central incisors and the patient's lip line should be assessed when the patient smiles. If a gingival margin discrepancy is present, but the patient's lip does not move upward to expose the discrepancy, it does not require correction. If a gingival margin discrepancy is apparent, the next step is to evaluate the labial sulcular depth over the two central incisors (Fig 8). If the shorter tooth has a deeper sulcus, excisional gingivectomy may be appropriate to move the gingival margin of the shorter tooth apically.²⁶⁻³¹ However, if the sulcular depths of the short and long incisors are equivalent, gingival surgery will not help.

The next step is to evaluate the relationship between the shortest central incisor and the adjacent lateral incisors. If the shortest central is still longer than the lateral incisors, the other possibility is to extrude the longer central incisor and equilibrate the incisal edge. This will move the gingival margin coronally and eliminate the gingival margin discrepancy. However, if the shortest central were shorter than the laterals, this technique would produce an unaesthetic relationship between the gingival margins of the central and lateral incisors.

The fourth step is to determine if the incisal edges have been abraded. This is best appreciated by evaluating the teeth from an incisal perspective. If one incisal edge is thicker labiolingually than the adjacent tooth, this may indicate that it has been abraded, and the tooth has overerupted. In this situation, the best method

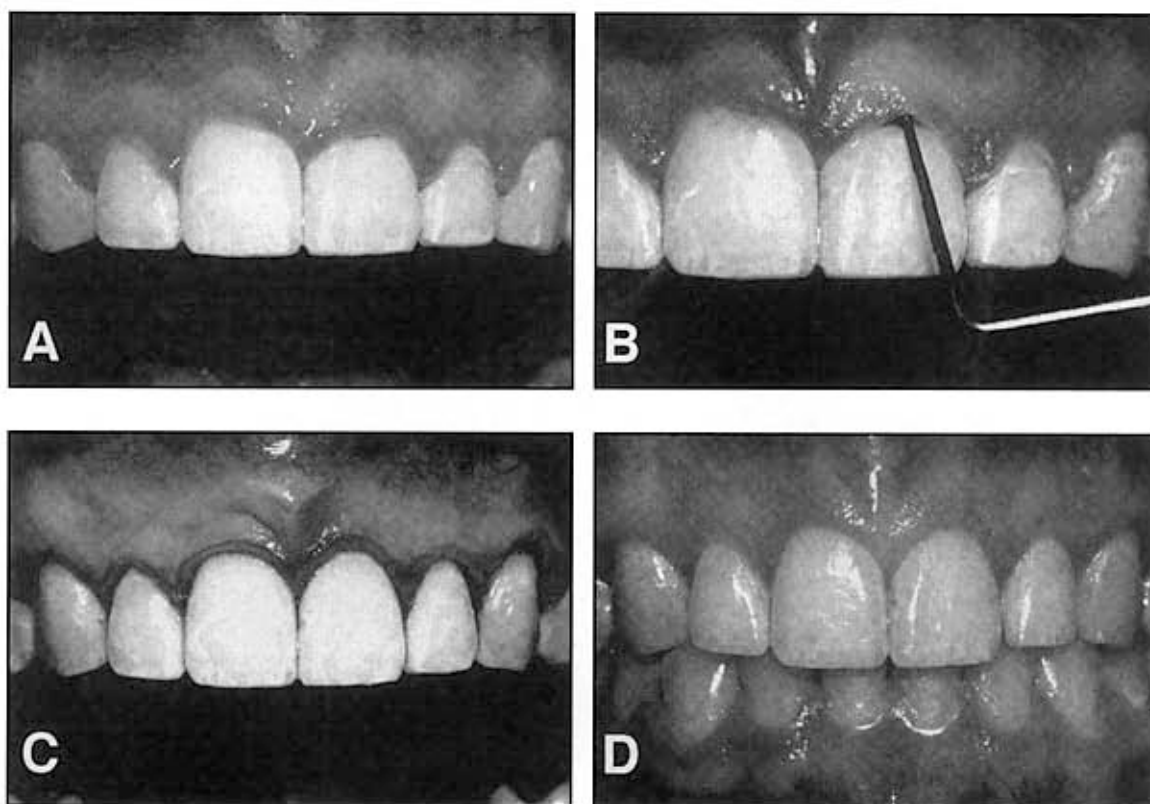


Figure 8. The gingival margins between the right and left central incisors are uneven (A). The sulcular depth labial to the left central is deeper than the right central incisor, and the cemento-enamel junction is located at the depth of the sulci over both teeth (B). The correct treatment for this unesthetic situation is excisional gingivectomy (C), which results in correct gingival margin relationships after the surgery (D).

of correcting the gingival margin discrepancy is to intrude the short central incisor (Fig 9). This method will move the gingival margin apically, and permit restoration of the incisal edges.²⁰⁻²⁵ The intrusion should be accomplished at least six months before appliance removal. This will allow reorientation of the principal fibers of the periodontium and avoid re-extrusion of the central incisor(s) after appliance removal.

Occasionally, patients will have destructive dental habits such as a protrusive bruxing habit that could result in significant wear of the maxillary and mandibular incisors and compensatory overeruption of these teeth. When the restorative dentist contemplates restoration of these abraded teeth, it is often impossible because of the lack of crown length to achieve adequate retention and resistance form for the crown preparations. Two options are available. One would be extensive crown lengthening by elevating a flap, removing sufficient bone, and

apically positioning of the flap to expose adequate tooth length for crown preparation. However, this type of procedure is contraindicated in the patient with short tapered roots, because it could adversely affect the final root to crown ratio, and it could potentially open up black triangles or open gingival embrasures between the anterior teeth.

The other option for improving the restorability of these short abraded teeth is to orthodontically intrude the teeth and move the gingival margins apically (Fig 10). It is possible for the orthodontist to intrude up to four maxillary incisors by using the posterior teeth as anchorage during the intrusion process. This process is accomplished by placing the orthodontic brackets as close to the incisal edges of the maxillary incisors as possible. The brackets are placed in their normal position on the canines and remaining posterior teeth. The patient's posterior occlusion will resist the eruption of the posterior

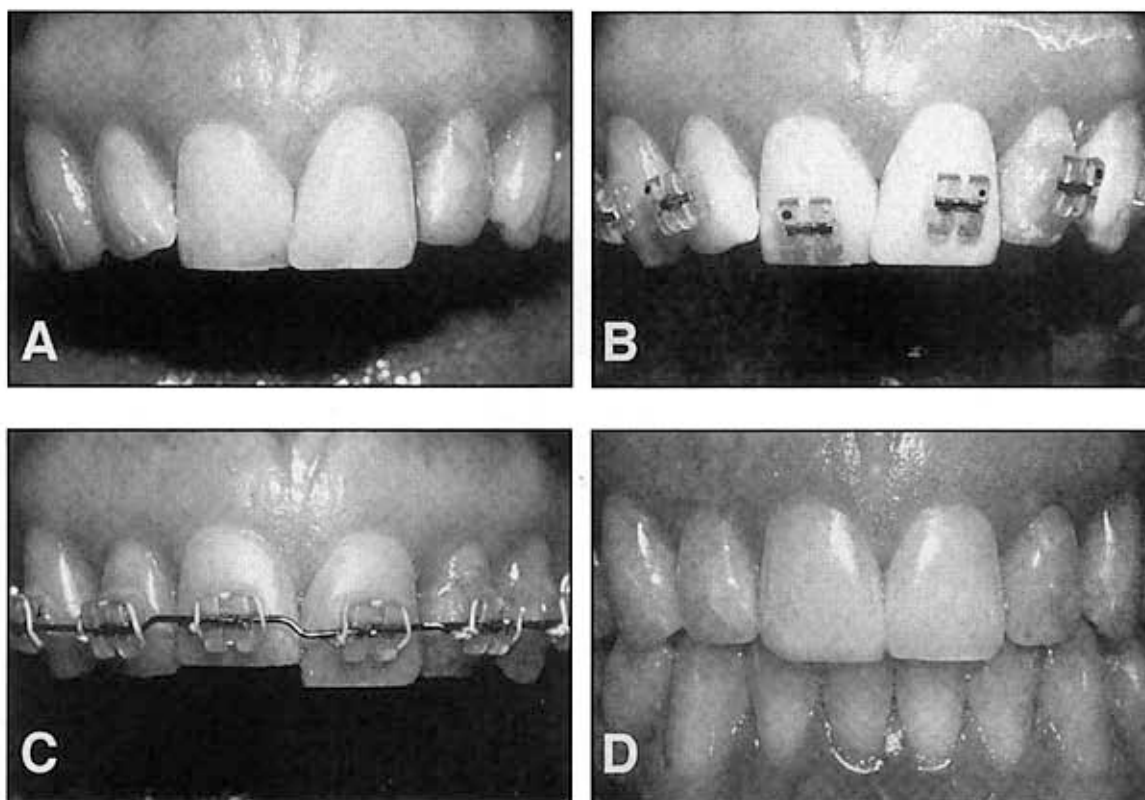


Figure 9. The gingival margins between the right and left central incisors are uneven (A). However, the sulcular depths over both central incisors are one millimeter, and the cemento-enamel junction is located at the bottom of the sulci. The right central is abraded and the dentin is visible at the incisal edge. The correct treatment plan is to position the bracket more incisally on the right central incisor (B) to intrude the abraded tooth (C) so it can be restored to its correct length matching the contralateral incisor (D).

teeth, and the incisors will gradually intrude and move the gingival margins and the crowns apically. This creates the restorative space necessary to temporarily restore the incisal edges of these teeth, and then to eventually place the final crowns on the teeth.

When abraded teeth are intruded significantly, it is necessary to hold these teeth for at least six months in the intruded position with the orthodontic brackets and/or archwires, or some sort of bonded retainer. The principal fibers of the periodontium must accommodate to the new intruded position,³² and this process could take a minimum of 6 months in most adult patients. Orthodontic intrusion of severely abraded and overerupted teeth is usually a distinct advantage over periodontal crown lengthening unless the patient has extremely long and broad roots, or has had extensive horizontal periodontal bone loss.

Gingival Form

The presence of a papilla between the maxillary central incisors is a key esthetic factor in any individual.^{15,22} Occasionally, adults will have open gingival embrasures or black triangles between their central incisors. These unsightly areas are often difficult to resolve with periodontal therapy. However, orthodontic treatment can correct many of these open gingival embrasures, even in some adult periodontal patients. This space is usually due to one of three causes: tooth shape, root angulation, or periodontal bone loss.¹⁵

The interproximal contact between the maxillary central incisors consists of two parts. One portion is the tooth contact and the other portion is the papilla. The ratio of papilla to contact is one to one. In other words, half the space is occupied by papilla and half is formed by the tooth contact.³³ If the patient has an open embrasure, the first aspect

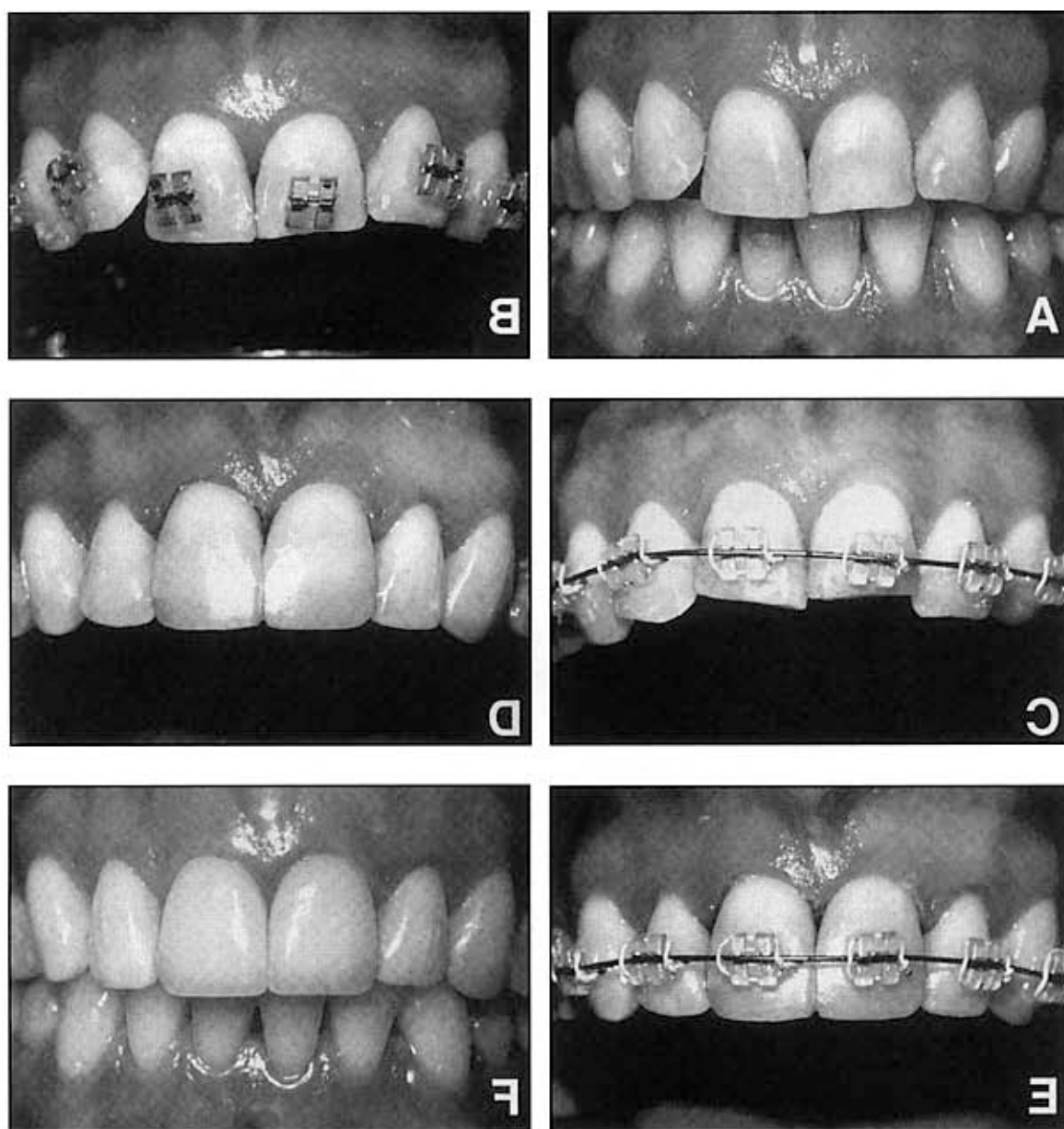


Figure 10. This patient has abraded both maxillary central incisors, and the teeth have overerupted (A). Although one solution is to perform an apically positioned flap to increase the crown length before restoration, this procedure would expose the cementum and reduce crowns. The other solution is to place the brackets incisally on the centrals (B), invade these teeth (C), and temporarily restore (D) and stabilize (E) these teeth, until they can be restored eventually with conservative porcelain veneers (F).

level is positioned apically. adjacent teeth, when the interproximal bone alveolar bone loss. Another possibility is to erupt more esthetic papilla between two teeth despite This type of movement can help to create a the interproximal gingiva and move it incisally. ing open contacts, the orthodontist can reduce

that the clinician should evaluate is whether the problem is due to the papilla or the tooth contact. If the papilla is the problem, then the cause is usually a lack of bone support due to an underlying periodontal problem.

In some situations, a deficient papilla can be accentuated with orthodontic treatment. By clos-

Most open embrasures between the central incisors are due to problems with tooth contact. The first step in the diagnosis of this problem is to evaluate a periapical radiograph of the central incisors. If the root angulation is divergent (Fig 11), then the brackets should be repositioned so the root position can be corrected. In these

situations, the incisal edges may be uneven and require restoration with either composite or porcelain restorations (Fig 11). If the periapical radiograph shows that the roots are in their correct relationship, then the open gingival embrasure is due to triangular tooth shape.

If the shape of the tooth is the problem, two

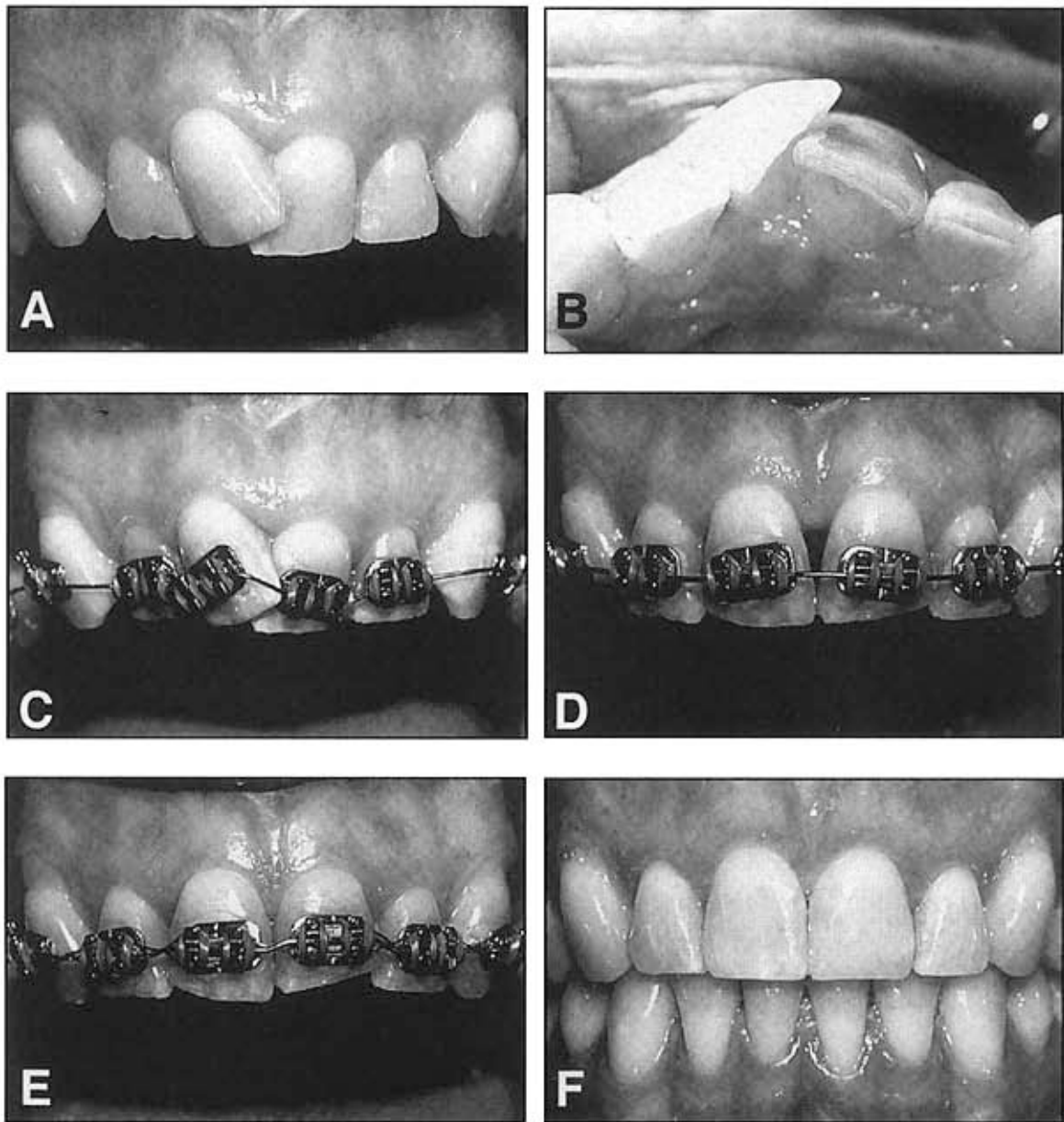


Figure 11. This patient has overlapped (A) and abraded maxillary central incisors (B). When these teeth are bracketed for orthodontic alignment, it is important to place the brackets perpendicular to the long axis of the root (C) rather than parallel to the abraded incisal edges. In this way, the roots will be uprighted, gradually eliminating the open gingival embrasure (D, E), and providing the correct papilla-contact relationship after orthodontics (F).

solutions are possible. One possibility is to restore the open gingival embrasure. The other option is to reshape the tooth, by flattening the incisal contact and closing the space (Fig 12). This will result in lengthening of the contact until it meets the papilla. In addition, if the

embrasure space is large, closing the space will squeeze the papilla between the central incisors. This will help to create a one to one relationship between the contact and papilla, and restore uniformity to the heights between the midline and adjacent papillae.

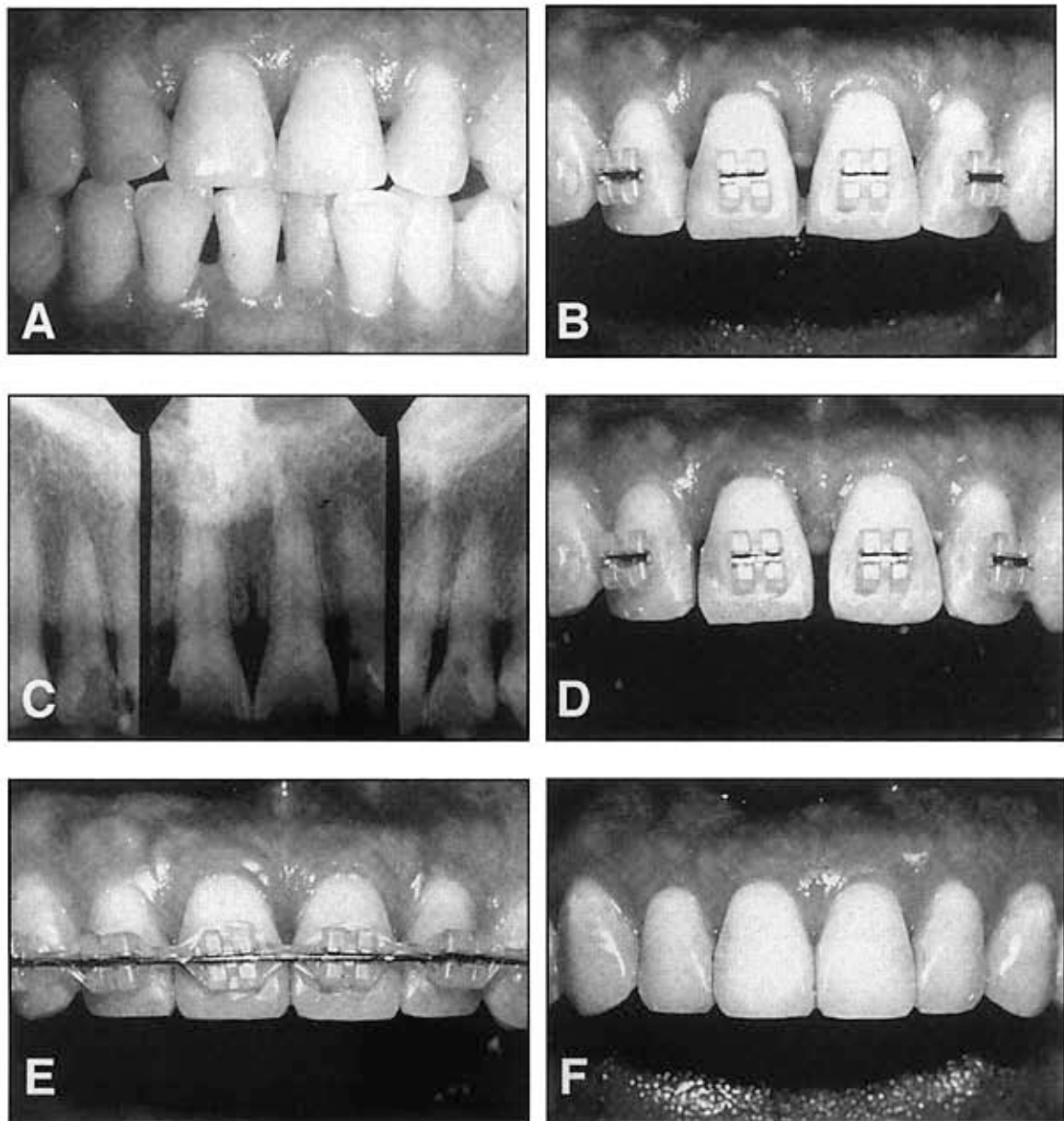


Figure 12. When an open gingival embrasure is caused by tooth shape (A, B, C), the correct solution is either to reshape the tooth or restore the open gingival embrasure. Estimating the eventual width to length proportion of the tooth will provide the clinician with the appropriate solution. In this situation, reshaping of both central incisors (D) and closure of the space (E) eliminated the open gingival embrasure and produced a correct papilla-contact relationship (F).

Conclusions

This article has hopefully accomplished two objectives. The first was to identify which parameters are important for the clinician to evaluate during the finishing phase of orthodontic therapy to produce an acceptable occlusal, periodontal, and esthetic result. The second objective was to explain how the usual finishing parameters must be adjusted to accommodate for an adolescent patient who will require restorative treatment after orthodontic therapy, or the adult orthodontic patient who will require combined periodontal and restorative treatment after the completion of orthodontics.

References

- Casko J, Vaden J, Kokich V, et al. American Board of Orthodontics objective grading system for dental casts and panoramic radiographs. *Am J Orthod Dentofacial Orthop* 2000;114:530-532.
- Kokich V. Anterior dental esthetics: An orthodontic perspective: Mediolateral relationships. *J Esthet Dent* 1993;5:200-207.
- Kokich VG. The role of orthodontics as an adjunct to periodontal therapy, in Newman MG, Carranza FA, Takei H (eds): *Carranza's Clinical Periodontology*, 9th Edition. Philadelphia, PA: Saunders Inc., 2002, chapter 53, pp 704-718.
- Kokich, VG. Orthodontic-restorative management of the adolescent patient, in McNamara JA (ed): *Orthodontic and Dentofacial Orthopedics*. Ann Arbor, MI: Needham Press, 2001, pp 423-452.
- Creugers N. Seven year survival study of resin-bonded bridges. *J Dent Res* 1992;71:1822-1825.
- Boyer D. Analysis of debond rates of resin-bonded bridges. *J Dent Res* 1993;72:1244-1248.
- Kokich V, Spear F. Guidelines for managing the orthodontic-restorative patient. *Semin Orthod* 1997;3:3-20.
- Lucchesi MV, Wood RE, Nortje CJ. Suitability of the panoramic radio-graph for assessment of mesiodistal angulation of teeth in the buccal segments of the mandible. *Am J Orthod Dentofacial Orthop* 1988;94:303-310.
- Stramotas S, Geenty JP, Dardendeliler MA, et al. The reliability of crown-root ratio, linear, and angular measurements of panoramic radiographs. *Cin Orthod Res* 2000;3:182-191.
- McKee IW, Blover KE, Williamson PC, et al. The effect of vertical and horizontal head positioning in panoramic radiography on mesiodistal tooth antulations. *Angle Orthod* 2001;71:442-451.
- McKee IW, Williamson PC, Lam EW, et al. The accuracy of 4 panoramic units in the projection of mesiodistal tooth angulations. *Am J Orthod Dentofacial Orthop* 2002;121:166-175.
- Stramotas S, Geenty JP, Petocz P, Dardendeliler MA. Accuracy of linear and angular measurements on panoramic radiographs taken at various positions in vitro. *Europ J Orthod* 2002;24:43-52.
- Artun J, Osterberg SK, Kokich VG. Long-term effect of thin interdental alveolar bone on periodontal health after orthodontic treatment. *J Periodontol* 1986;57:341-346.
- Artun J, Kokich VG, Osterberg SK. Long-term effect of root proximity on periodontal health after orthodontic treatment. *Am J Orthod Dentofacial Orthop* 1987;91:125-130.
- Kokich VO, Kiyak A, Shapiro PA. Comparing the perception of dentists and lay people to altered dental esthetics. *J Esthet Dent* 1999;11:311-324.
- Lombardi R. The principles of visual perception and their clinical application to denture esthetics. *J Prosthet Dent* 1973;29:358.
- Ricketts R. The biologic significance of the divine proportion and Fibonacci series. *Am J Orthod* 1982;81:351-370.
- Chiche G, Pinault A. Replacement of deficient crowns. In Pinault A, Chiche G (eds): *Esthetics of Fixed Prosthodontics*. Chicago, IL: Quintessence, 1994, pp 53-73.
- Kokich VG, Spear FM, Kokich VO. Maximizing anterior esthetics: an interdisciplinary approach, in McNamara JA, Kelly KA (eds): *Frontiers of Dental and Facial Esthetics Craniofacial Growth Series*. Ann Arbor, MI: Center for Human Growth and Development, University of Michigan, 2001, pp 1-18.
- Kokich V, Nappen D, Shapiro P. Gingival contour and clinical crown length: Their effects on the esthetic appearance of maxillary anterior teeth. *Am J Orthod* 1984;86:899-904.
- Kokich V. Enhancing restorative, esthetic and periodontal results with orthodontic therapy, in Schluger S, Youdelis R, Page R, et al (eds): *Periodontal Therapy*. Philadelphia, PA: Lea and Febiger, 1990, pp 433-460.
- Kokich V. Anterior dental esthetics: an orthodontic perspective. I. Crown length. *J Esthet Dent* 1993;5:19-23.
- Chiche G, Kokich V, Caudill R. Diagnosis and treatment planning of esthetic problems, in Pinault A, Chiche G (eds): *Esthetics in Fixed Prosthodontics*. Chicago, IL: Quintessence, 1994, pp 33-52.
- Kokich V. Esthetics: The orthodontic-periodontic-restorative connection. *Semin Orthod* 1996;2:21-30.
- Kokich V. Esthetics and vertical tooth position: The orthodontic possibilities. *Compendium Cont Ed Dent* 1997;18:1225-1231.
- Orban B. Indications, technique and postoperative management of gingivectomy in the treatment of periodontal disease. *J Periodontol* 1941;12:88-91.
- Goldman H. The development of physiologic gingival contour by gingivoplasty. *Oral Surg* 1950;3:879.
- Ramfjord S. Gingivectomy—its place in periodontal therapy. *J Periodontol* 1952;23:30-35.
- Prichard J. Gingivectomy, gingivoplasty, and osseous surgery. *J Periodontol* 1961;32: 257-262.
- Gargiulo A, Wenz F, Orban B. Dimensions and relation at the dentogingival junction in humans. *J Periodontol* 1961;32:261-267.
- Maynard J, Wilson R. Physiologic dimension of the periodontium fundamental to successful restorative dentistry. *J Periodontol* 1979;50:170-174.
- Reitan K. Tissue rearrangement during retention of orthodontically rotated teeth. *Angle Orthod* 1959;29: 105-113.
- Kurth J, Kokich VG. Open gingival embrasures after orthodontic treatment in adults: Prevalence and etiology. *Am J Orthod Dentofacial Orthop* 2001;120:116-123.