

2 | Comprehensive Management of Implant Anchorage in the Multidisciplinary Patient

Vincent G. Kokich, DDS, MSD

In recent years, dental implants have become an accepted method of replacing missing teeth. Today millions of implants are placed annually to rehabilitate and reestablish patients' occlusions. However, in many of these individuals, the teeth may be in less than ideal position to accept the integration of single implants or groups of implants with the remaining teeth. Many of these patients could benefit from orthodontics to reposition malposed teeth to enhance the overall occlusal scheme. However, if significant numbers of teeth are missing, the orthodontist is at a disadvantage because of a lack of anchorage to effect the desired tooth movement. Past studies have shown that implants can be used as anchors for both orthopedic and orthodontic movement.¹⁻⁵ However, some studies describing the use of implants for orthodontic anchorage do not recommend utilizing the implant as a restorative abutment after the orthodontic movement.⁶ Although nonroot-form onplants and implants can be placed in nonalveolar bone, used for anchorage,^{7,8} and then removed, this type of implant anchorage is not useful in patients having many missing teeth and multiple edentulous spaces. In this type of dental patient, an interdisciplinary approach of placing the implant prior to orthodontics, using it as an orthodontic anchor, and then using the same implant as a restorative abutment may be a more appropriate and cost-effective solution. This chapter will discuss the interdisciplinary management of implants that are used for orthodontic anchorage and as restorative abutments. The chapter will also describe the indications for implant anchorage, methods of locating the appropriate implant position, timing of orthodontic loading, types of provisional restorations appropriate for attaching orthodontic brackets, and the effects of orthodontic loading on the integrity of osseointegration and final restoration.

Indications for Implant Anchorage

Although several situations can be found where implants can be used for both orthodontic and restorative anchorage, this section will identify four generic possibilities that include many different situations. One possibility would be to use the implant as an anchor to facilitate intra-arch intrusion of a tooth or teeth that have supraerupted. This situation is often seen in patients with missing teeth in one arch, leaving teeth in the opposing arch without an occlusal counterpart (Figs 2-1a and 2-1b). In these situations, teeth tend to supraerupt beyond the plane of occlusion and encroach into the restorative space of the opposite dental arch. If a single tooth erupts 1 to 2 mm beyond the occlusal plane, and teeth are present adjacent to the overerupted tooth, the adjacent teeth will usually provide sufficient anchorage to orthodontically intrude the overerupted tooth. However, if two or more teeth have erupted beyond the occlusal plane, or if the adjacent teeth are missing, there may be insufficient anchorage to intrude the overerupted teeth (Figs 2-1a and 2-1b). In the latter situation, if implants are planned to replace the missing teeth, these implants may be used to intrude the overerupted teeth prior to restoration. In such cases, the implants must be positioned accurately prior to the orthodontics so they can be used as restorative abutments following tooth movement.

A second indication for using implants as both orthodontic and restorative anchorage is to facilitate interarch intrusion of teeth. This situation arises when several teeth in the opposing dental arch have been missing for several years and the edentulous space has not been restored (Fig 2-1c). In this case, three or more teeth may supraerupt into the opposing edentulous space. If a segment of teeth has supraerupted, intra-arch intrusion using adjacent teeth in the same arch is generally not possible without causing eruption of the adjacent teeth. In some of these situations, the only possible method for intruding the overerupted teeth is through segmental orthognathic surgery. However, if implants are planned as restorative replacements for the teeth in the opposing arch, the implants may be used as abutments for orthodontic intru-

sion. In this situation, implants are placed as anchors, and samarium-cobalt magnets are used to provide the intrusive force to the overerupted teeth. After reintrusion of the overerupted segment of teeth, the implants in the opposing arch may be used as restorative abutments to provide occlusal stops and rehabilitate occlusal function.

A third possibility for using an implant as an orthodontic anchor and a restorative abutment is in the patient requiring intra-arch retraction/protraction of adjacent teeth within the same arch. This situation occurs when single or multiple teeth are missing, and the treatment plan requires consolidation of part of the space by moving the teeth in only one direction (Figs 2-1d and 2-1e). Generally, tooth movement is reciprocal. If a tooth is used to provide anchorage for adjacent tooth movement, the anchor will also move—a sometimes undesirable sequela. In addition, there may be no posterior or anterior tooth to provide anchorage for orthodontic movement. In such cases, an implant can provide absolute anchorage for orthodontic movement and later be used as an abutment for a restoration to replace the missing teeth within that dental arch.

The fourth and final indication for the interdisciplinary use of an implant for orthodontic and restorative anchorage is interarch retraction/protraction. This situation occurs when several teeth are missing in both dental arches and the remaining teeth in one or both arches require significant movement. If implants cannot be used for retraction in one arch, they may be placed in the opposite arch, and interarch forces can be used to move teeth in the opposing arch (Fig 2-1f). After the desired tooth movement, the implant may be used as a restorative abutment.

Determining the Appropriate Implant Position

If several permanent teeth are missing but the remaining teeth are appropriately positioned and sufficient space remains for the placement of implants, the surgeon and restorative dentist may construct a placement guide to position the im-

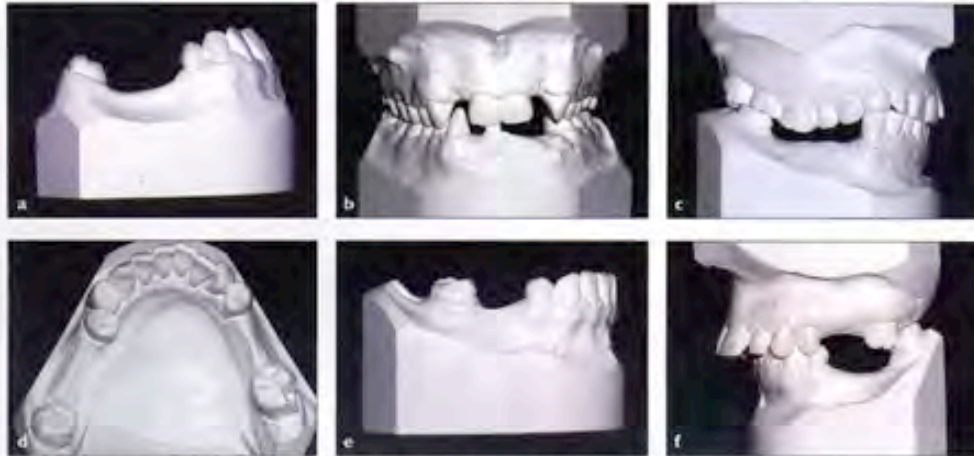


Fig 2-1 The indications for implant anchorage to facilitate orthodontic tooth movement consist of intra-arch intrusion (a, b), where implants are used to intrude adjacent teeth within the same arch; interarch intrusion (c), where implants placed in one arch are used as abutments to intrude the teeth in the opposite arch; intra-arch retraction (d, e), where implants are used to retract (d) or protract (e) adjacent teeth within the same arch; and interarch retraction (f), using implants in one arch to retract teeth in the opposite arch.

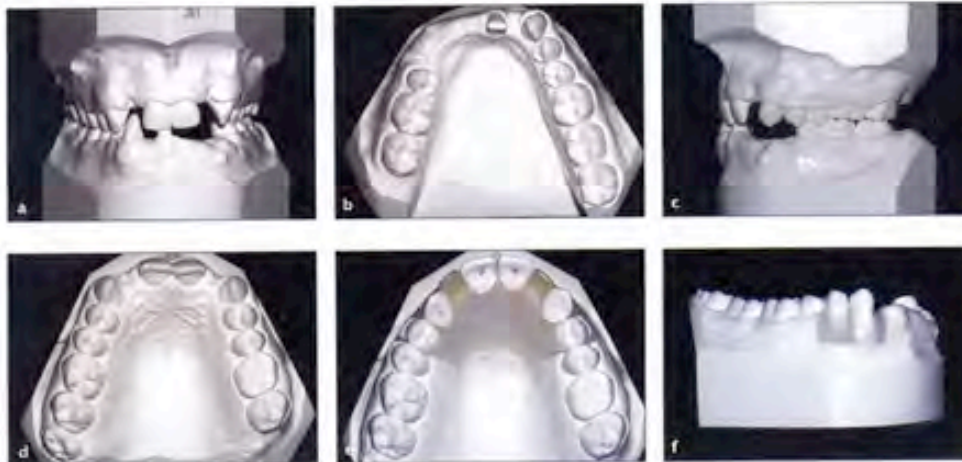
plants properly. However, if the adjacent teeth are not in their proper positions and the implants are to be used to reposition the teeth, the placement guide must be constructed from a simulation of the final tooth positions. This simulation, or diagnostic wax setup, must be constructed correctly so the implants and teeth will be in their proper positions.²⁰

Construction of the diagnostic setup varies, depending on the number of teeth to be moved during orthodontic treatment. In some situations, only a few teeth will be moved (Fig 2-2). In other situations, all teeth will undergo some repositioning (Fig 2-3). In either case, a series of four steps should be followed during the implant construction. The first step is to duplicate the base and tooth portions of the original dental casts (Figs 2-2a to 2-2d, 2-3a, 2-3b, and 2-3d). The second step is to cut the teeth out of the plaster. However, all teeth cannot be cut out initially or the reference will be lost and the setup will not represent the actual outcome of treatment. Only the teeth to be moved during orthodontics should be cut out (Figs 2-2e to 2-2g). A third important step is to always

leave a reference tooth when sectioning the dental casts. If all the teeth are to be repositioned during construction of the setup, then half the maxillary and mandibular arches should be sectioned at the midline on the duplicated casts (Figs 2-3c and 2-3f). The remaining, or contralateral, central incisor will serve as the reference tooth when replacing the plaster teeth in the wax. If only a few teeth are to be moved during the orthodontics, then only those teeth should be sectioned from the duplicated dental casts.

After wax is added to the dental bases, the final step is to reposition the plaster teeth in their bases. It is generally recommended that the nonimplant arch be repositioned first in order to determine how much tooth movement is needed in the arch intended for implants (Figs 2-2h, 2-2i, 2-3d, 2-3g, and 2-3h). After the nonimplant arch is set up, the plaster teeth in the arch containing the implants are positioned in their proper occlusal relationship. The space remaining after simulated orthodontic movement will determine the positions of the implants.

Fig 2-2 Placement of implants for orthodontic anchorage requires precise location of the implant so that it will be appropriate for both the orthodontist and the restorative dentist. If possible, only the teeth that are to be moved during the orthodontic treatment should be sectioned and replaced in the setup. This will allow the remaining teeth to serve as a reference during construction of the placement guide. In this patient, the mandibular right canine and first premolar would be intruded during the orthodontics. However, in order to place implants properly in the mandibular left first premolar and canine and right lateral incisor locations, the anticipated maxillary tooth movement was created in the diagnostic setup. This allowed the placement of plastic teeth in the mandibular incisor region to determine the precise position of the eventual implant abutments for the lower fixed partial denture. A placement guide was fabricated from the plaster cast of the setup and used to locate the implants prior to orthodontic treatment.

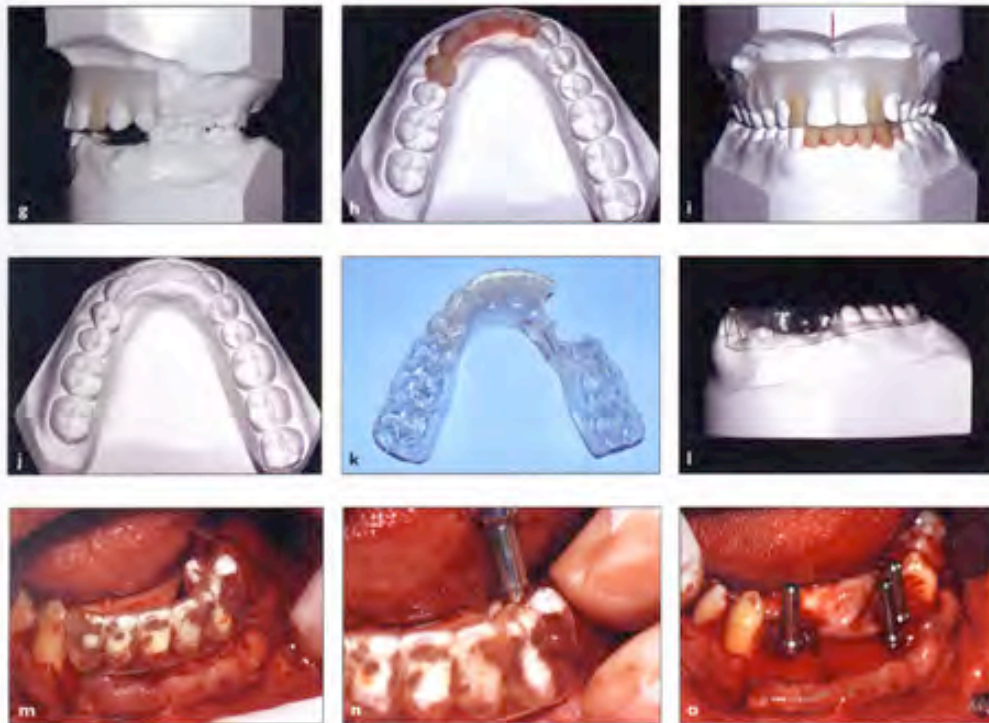


If the implants are to be used eventually as fixed partial denture abutments after orthodontic anchorage, plastic or wax teeth simulating the eventual size of the crowns and pontics must be added to the diagnostic setup (Figs 2-2h, 2-2i, 2-3d, 2-3g, and 2-3h). These prosthetic teeth should be the exact size of the eventual restorations so that they can pinpoint for the surgeon the position of the implants.

The next step is to transfer the information regarding implant position to the original dental cast in order to construct a plastic placement guide. Two different methods can be used to do this. If only a few teeth were repositioned during the setup, then a plaster duplicate of the wax setup can

be made (Fig 2-2j). A plastic stent is then constructed to simulate the positions of the orthodontically moved teeth and the implant teeth (Fig 2-2k). The portion of plastic involving the repositioned teeth can then be removed from the stent so it will fit accurately over the teeth in their original positions (Fig 2-2l). In areas where the eventual pontics or implant crowns create a void, the stent is filled with plastic so the surgeon will have a more accurate guide for precise positioning of the implant in all directions (Figs 2-2m to 2-2o).

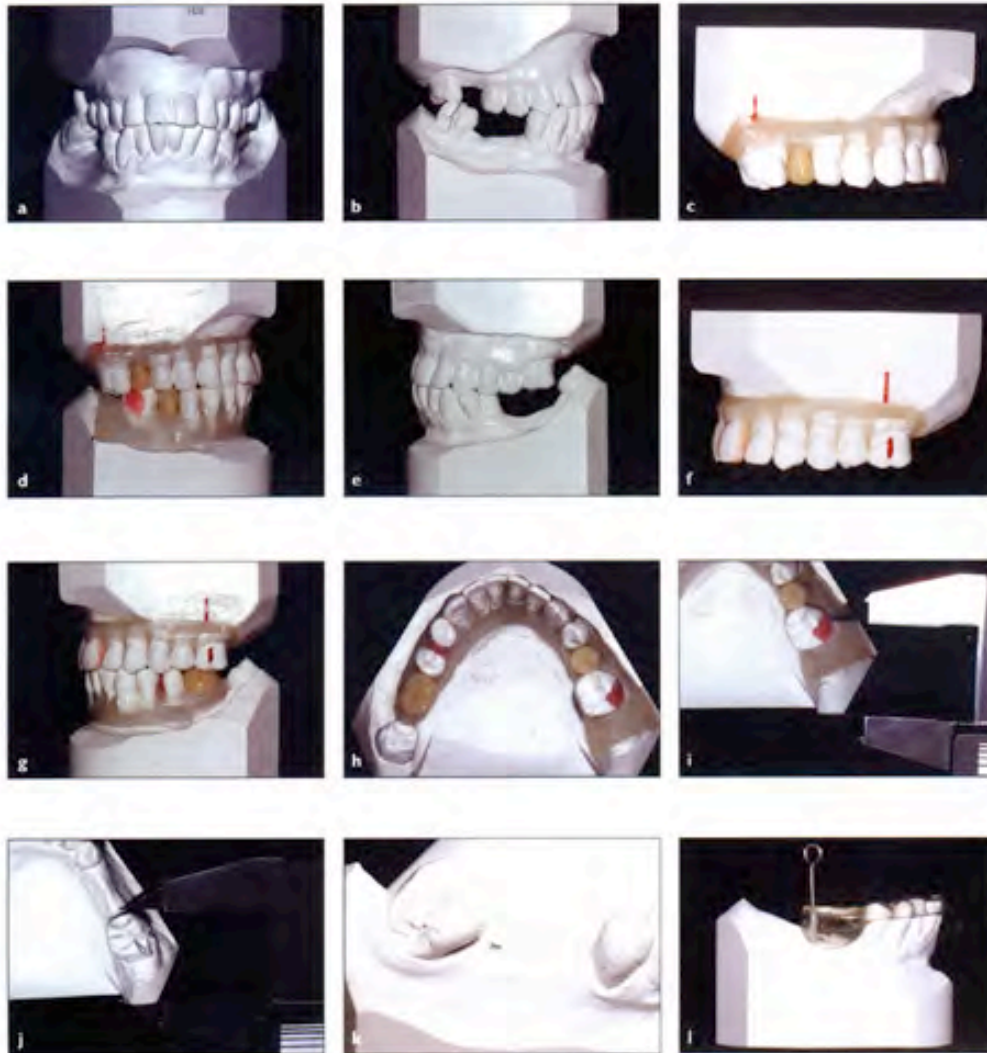
If all the plaster teeth were repositioned during the setup process, then the transfer of information back to the original dental cast must be accomplished using a different method. If the dental



bases were also accurately replicated during the duplication process, the borders of the dental base may be used as a reference for transferring the implant position to the original dental casts. In this situation, a caliper is used to measure the distance from a point on the base of the dental cast to the center of the implant (Fig 2-3i). Then this distance is transferred back to the original plaster cast, using the same reference point on the dental base (Fig 2-3j). A pencil mark is made on the spot where the implant should be positioned (Fig 2-3k). Then the plastic placement guide can be constructed and a hole placed in the guide corresponding to the pencil mark (Fig 2-3l).

The stent is then positioned intraorally to verify its fit over the occlusal surfaces of the teeth. By simulating where the implants will be positioned, it is now possible to determine if sufficient bone is present in those areas (Fig 2-2m). If sufficient bone is not present, then a bone graft can be accomplished prior to implant placement. The setup and stent will help the surgeon identify the exact location and amount of bone grafting necessary to support the implants (Figs 2-2n and 2-2o). The last step is to use the stent to place the implants. It is important to position the stent securely over the occlusal surfaces of the teeth so that the implants will be accurately positioned.

Fig 2-3 If all teeth are to be relocated during the orthodontic treatment, the diagnostic setup to determine the position of the anchorage implants must be constructed in the proper manner. In this situation, the bases of the plaster casts are used as a reference. The setup is constructed one side at a time with the teeth on the opposite side acting as a reference. Generally, the teeth in the arch opposite the implants are set up first. Then the opposing arch is positioned to simulate the desired final tooth position and occlusion. Using the base of the cast as a reference, calipers may be employed to transfer the location of the implants back to the original dental cast. Then the placement guide may be fabricated to position the implant precisely prior to the initiation of orthodontics.



Timing of Orthodontic Loading

Uncovering of the implants and application of orthodontic loading must be timed properly to avoid loss of osseointegration of the implant. The timing of implant loading for single implants is determined by the amount of time required by the bone adjacent to the implant to undergo secondary osteon (remodeling) formation around the implant.¹¹ If multiple implants are placed at the same time, they are often loaded occlusally immediately after placement, using a provisional prosthesis. Even though the bone around the implant has not completely remodeled, the rigidity supplied by cross-arch splinting has been shown to be sufficient to allow for integration to occur around the functioning implants.

However, if single-tooth implants are placed, it is probably disadvantageous to load them immediately. The healing process around an implant goes through several stages. The first process to occur is necrosis of the bone adjacent to the implant. This is due to the trauma and heat that accompany the drilling and tapping process. After resorption of the necrotic bone, osteoid, the organic precursor of bone, is deposited around the implant. Then this organic matrix calcifies with the deposition of calcium and phosphorus salts. However, before the implant is loaded orthodontically, the woven bone should be allowed to undergo remodeling with the development of secondary osteons. Although the exact timing of secondary osteon formation around implants is not known and may vary between individuals, it is probably between 14 and 18 months. Secondary remodeling probably occurs faster in the mandible than in the maxilla. In summary, the orthodontist should wait about 4 to 6 months before loading the implant orthodontically.

Types of Provisional Restorations

After the implant has been uncovered, a provisional restoration must be placed so the orthodontic force can be attached to the implant. The type of provisional restoration varies, depending on the type of orthodontic mechanics. In some situations,

a tooth-shaped plastic restoration is required. However, in other situations, a metal abutment is sufficient to provide the anchorage. In general, if orthodontic brackets are not to be used, a simple metal cap can be placed on top of the implant (Fig 2-4a). This can be used to facilitate attachment of a plastic stage, housing a samarium-cobalt magnet that can be used for interarch intrusion (Fig 2-4b).

In other situations, if the teeth adjacent to the implant are to be moved toward the implant, a provisional plastic restoration is necessary to permit accurate positioning of these teeth during the orthodontic process (Figs 2-4c and 2-4d). In these situations, the size of the provisional crown can be ascertained from the diagnostic setup used to create the placement guide. In some cases, multiple provisional restorations (Figs 2-4e and 2-4f) or a provisional fixed partial denture (Figs 2-4g and 2-4h) may be necessary to provide adequate orthodontic anchorage and ensure proper tooth positioning.

Effect of Implant Loading

The amount of orthodontic force applied to the implant may be considerable. In addition, the direction of force may be different in various situations. If the implant is being used to produce intra-arch intrusion, the force on the implant is to *extrude* it out of the alveolus (Figs 2-5a to 2-5h). If the implant is being used for interarch intrusion using samarium-cobalt magnets, the force on the implant is *intrusive* (Fig 2-6), pushing it farther down into the bone. If the implant is being used for intra-arch retraction/protraction, the force on the implant is *compressive*, pushing it laterally against the alveolus (Fig 2-7). Finally, if the implant is being used to anchor interarch retraction/protraction, the force on the implant will be a *ripping* force (Figs 2-5i to 2-5l). In each of the examples used in this chapter to illustrate the effect of implant anchorage to facilitate orthodontic movement, the radiographic response to implant loading was not destructive to the bone-implant interface. For example, during intra-arch intrusion of overerupted teeth, the force on the implant is extrusive, tending to pull the implant out

2 | Comprehensive Management of Implant Anchorage in the Multidisciplinary Patient

Fig 2-4 After the implants have been uncovered, abutments must be placed on them to facilitate attachment of the orthodontic appliances. The abutments could consist of a metal attachment if brackets are not necessary (a,b); single (c,d) or multiple (e,f) plastic provisional crowns; or a plastic provisional fixed partial denture (g,h).

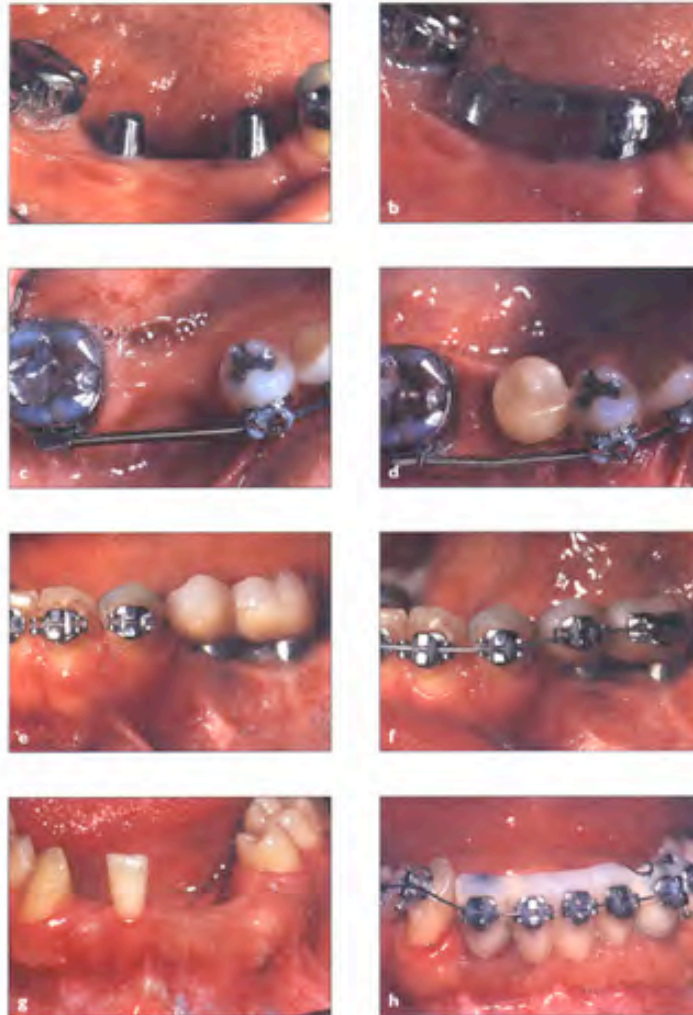


Fig 2-5 When implants are used for *intra-arch* intrusion (a-h) or *interarch* retraction (i-l), they do not move through the bone. The loading of the implants caused no loss of integration.

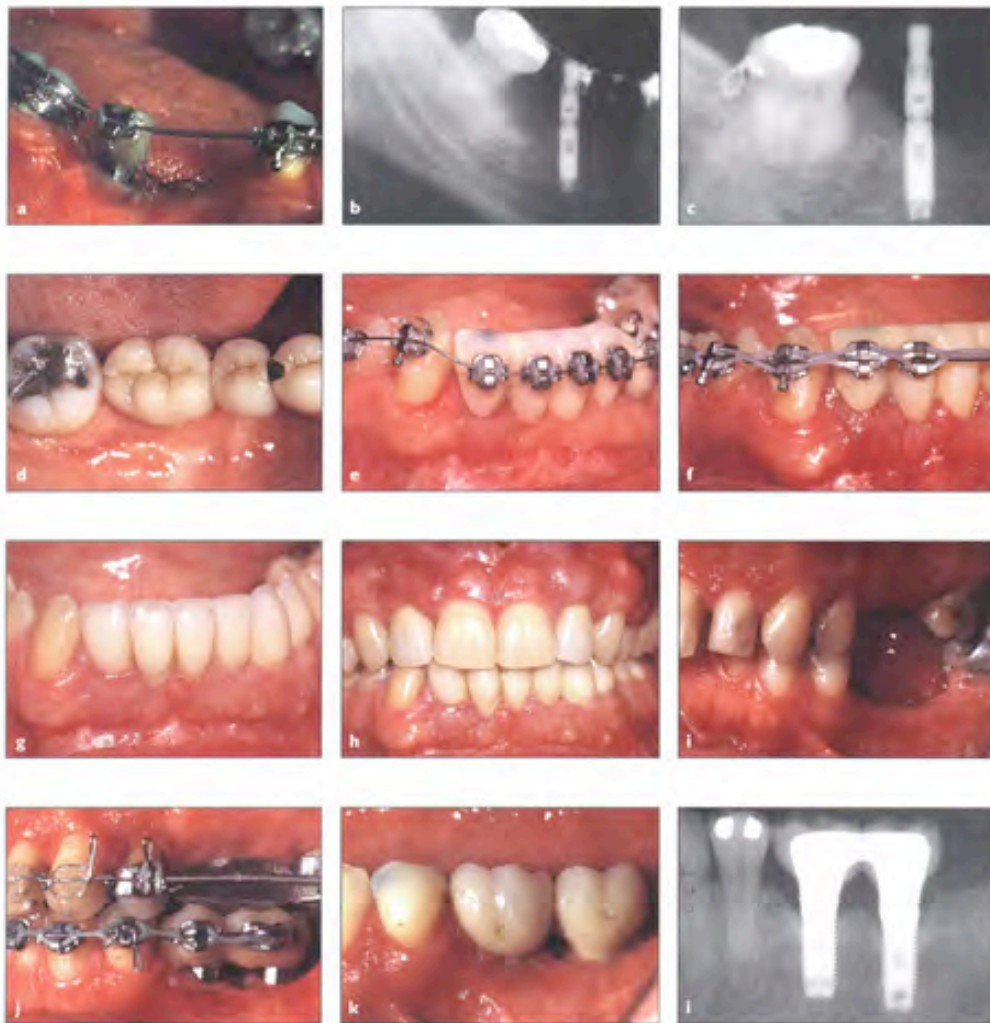
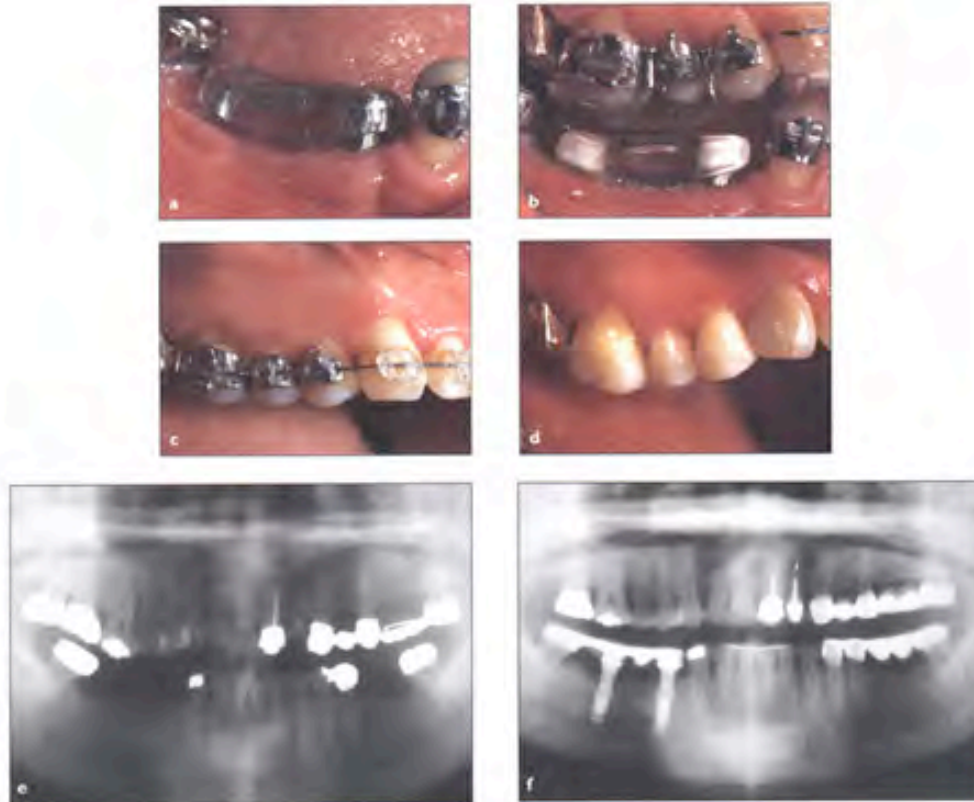

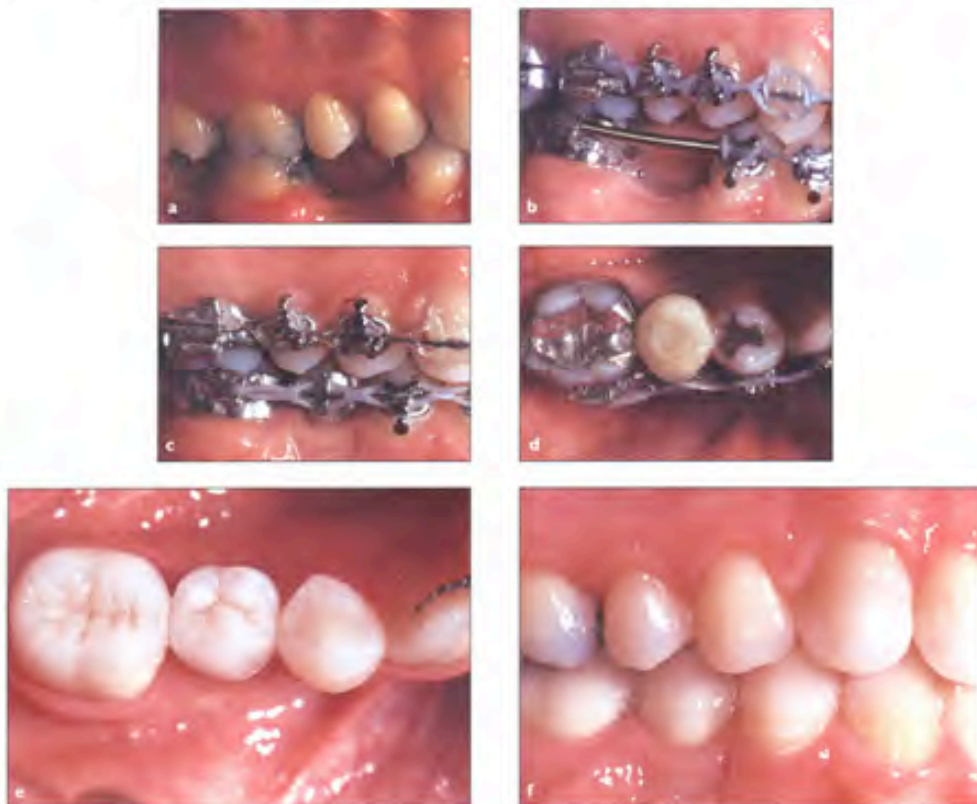Fig 2-6 When implants are used for interarch intrusion, the intrusive force on the implants causes no loss of osteointegration around the implants.



of the bone (Figs 2-5a to 2-5h). However, if the implant has integrated adequately, movement of the implant is nil. A natural tooth has a periodontal membrane that allows for resorption on the pressure side of the alveolus and deposition of new bone on the tension side, resulting in movement of the socket and tooth through the bone. However, when an orthodontic force is placed on an implant, histologic studies have shown that the bone is gen-

erally thicker on the pressure side of the implant and thinner on the opposite side. This thickening of bone deposited on the medullary side of the implant-bone interface is called *buttressing* bone. Although this phenomenon has been reported previously, the biologic mechanism for it is not well understood. Therefore, it appears that loading of the implant actually results in thicker bone and not in dissolution of the bone around the implant.

Fig 2-7 When implants are used for *intra-arch* retraction or protraction, the loading of the implant does not cause disintegration of the bone around the implant. Since the orthodontic forces are continuous and in one direction, the physiologic response is thickening of the bone on the pressure side of the implant.



Earlier articles in the literature have suggested that excessive occlusal loading may cause implants to disintegrate. Why would occlusal loads produce a different response than the favorable reaction observed when implants are loaded orthodontically? Although this difference cannot be conclusively determined in the scope of this chapter, it is believed to be due to two fundamental differences between an occlusal load and an orthodontic load. First, orthodontic loads are generally continuous and not intermittent. Occlusal loads, on the other hand, are intermittent. Second, orthodontic loads are usually

in one direction, whereas occlusal loads are in different directions. If a load on the implant is intermittent and in different directions, the biomechanical message transmitted to the bone surrounding the implant is not consistent. Therefore, no uniform response in the bone is produced. If, however, the force is continuous and in the same direction, as in an orthodontic force, then the biomechanical message to the bone will produce a uniform response at the bone-implant interface. Therefore, orthodontic loads on an implant could be perceived as more physiological than occlusal loads.

Summary

This chapter has shown how orthodontic tooth movement can be enhanced with implant anchorage. The indications for implant anchorage have been elucidated; the method of locating the proper position for placing the implant has been described and illustrated in detail; the timing of uncovering and loading of the implant has been explained; the types of abutments that may be necessary to attach orthodontic appliances has been summarized; and finally, the effect of implant loading on the integrity of the bone-implant interface has been elucidated. Although implant anchorage is generally needed for routine orthodontic treatment of children and adolescents, it may be critically useful for the adult orthodontic patient with missing teeth. When planning orthodontic treatment for these types of patients, the orthodontist, surgeon, and restorative dentist must collaborate and plan the treatment precisely so the implants will not only be in the proper position for the orthodontist but, more important, so they will also be in the correct position for adequate restoration of the patient's dentition after the orthodontic treatment has been completed.

References

1. Turley P, Shapiro P, Moffett B. The loading of bioglass-coated aluminum oxide implants to produce natural expansion of the maxillary complex in the pigtail monkey. *Arch Oral Biol* 1980;25:459-464.
2. Smalley W, Shapiro P, Hohl T, et al. Osseointegrated titanium implants for maxillofacial protraction in monkeys. *Am J Orthod Dentofac Orthop* 1988;94:285-295.
3. Gray J, Stuenkel M, King G, et al. Studies on the efficacy of implants as orthodontic anchorage. *Am J Orthod* 1983;83:311-317.
4. Douglas J, Killinay D. Dental implants used as orthodontic anchorage. *J Oral Implantol* 1988;13:28-38.
5. Kokich V. Managing complex orthodontic problems: The use of implants for anchorage. *Semin Orthod* 1996;2:153-160.
6. Roberts WE, Helm F, Marshall K, et al. Rigid endosseous implants for orthodontic and orthopedic anchorage. *Angle Orthod* 1989;59:247-255.
7. Roberts WE, Marshall K, Mozvay P. Rigid endosseous implant used as anchorage to protract molars and close an atrophic extraction site. *Angle Orthod* 1990;60:135-152.
8. Block M, Hoffman D. A new device for absolute anchorage for orthodontics. *Am J Orthod Dentofac Orthop* 1995;107:251-258.
9. Smalley W. Implants for orthodontic tooth movement: Determining implant location and orientation. *J Esthet Dent* 1995;7:62-72.
10. Smalley W, Blanco A. Implants for tooth movement: A fabrication and placement technique for provisional restorations. *J Esthet Dent* 1995;7:150-154.
11. Roberts WE, Smith R, Zilberman Y, et al. Osseous adaptation to continuous loading of rigid endosseous implants. *Am J Orthod* 1984;86:95-111.