

# Managing the patient with missing or malformed maxillary central incisors

Vincent G. Kokich<sup>a</sup> and Katherine E. Crabill<sup>b</sup>

Seattle and Tacoma, Wash



Occasionally, orthodontists and general dentists encounter a patient who has traumatically avulsed a maxillary central incisor<sup>1</sup> or a patient with a geminated or fused maxillary central incisor that must be removed.<sup>2,3</sup> In either situation, a decision must be made about the eventual restoration of the anterior

edentulous space. Several options exist for replacing a missing maxillary central incisor. If the tooth has been avulsed, the simplest long-term solution is to replant it. However, the success of reimplantation depends on the status of the tooth root,<sup>4</sup> the ability to perform endodontics,<sup>1</sup> and the length of time that the tooth is out of the alveolar socket.<sup>5</sup> If reimplantation is not possible, autotransplantation might be an option.<sup>6</sup> However, the patient must have an arch-length deficiency, so that a premolar from a posterior quadrant can be transplanted to the edentulous site. A third solution is to maintain the edentulous space during childhood and adolescence, and to place a bridge or implant during adulthood. A fourth possible solution is to close the edentulous space and substitute the ipsilateral lateral incisor for the central incisor.<sup>7</sup> The choice of the appropriate solution for the missing maxillary central incisor depends on the specific characteristics of each situation.

## Case 1

This boy, aged 8 years 2 months, had avulsed both maxillary central incisors. Fortunately, the teeth were

retrieved, the roots were intact, and the patient was taken to his pediatric dentist within 1 hour of the traumatic incident. During that time, the teeth were kept in room-temperature water. The dentist reimplanted the teeth and stabilized them with a flexible archwire bonded to the labial surfaces of the adjacent anterior teeth. Unfortunately, the teeth could not be seated completely into the sockets, and the crowns were positioned farther incisally than the adjacent anterior teeth. The mobility of the teeth had diminished after a month, and the splint was removed at that time. Root canal therapy was performed on both central incisors, even though the apices were open. At 11 years 4 months of age, all permanent teeth had erupted, and the patient had a Class II malocclusion with a deep anterior overbite (Fig 1). No dental crowding was present in the mandibular arch. The long-term prognosis for the maxillary central incisors was questionable, but at that time they were maintaining the anterior alveolar bone. A decision was made to extract the maxillary right and left first premolars to facilitate reduction of the anterior overjet. Because the roots of the maxillary central incisors were short, the crown lengths of the central incisors were reduced intentionally during bracket placement. Complete orthodontic appliances were used to align the teeth, reduce the deep overbite, and establish proper occlusion and esthetics.

## Case 2

This boy had avulsed his maxillary left central incisor at 9 years of age. Although the tooth was retrieved, the patient did not see his dentist for about 3 hours. During that time, the avulsed tooth was not kept moist but was transported in an envelope. The root end was nearly closed, and, although the root had dried, the dentist reimplanted the tooth. It was stabilized with a rigid wire for 1 month; then the splint was removed, and the teeth were allowed to erupt. Root end induction with calcium hydroxide was attempted to stimulate closure of the apex. After about 3 years, the remaining anterior teeth had erupted, but the left central incisor was submerged apically and appeared ankylosed (Fig 2). The patient had a Class I uncrowded malocclusion. The

<sup>a</sup>Professor, Department of Orthodontics, School of Dentistry, University of Washington, Seattle.

<sup>b</sup>Private practice, Tacoma, Wash.

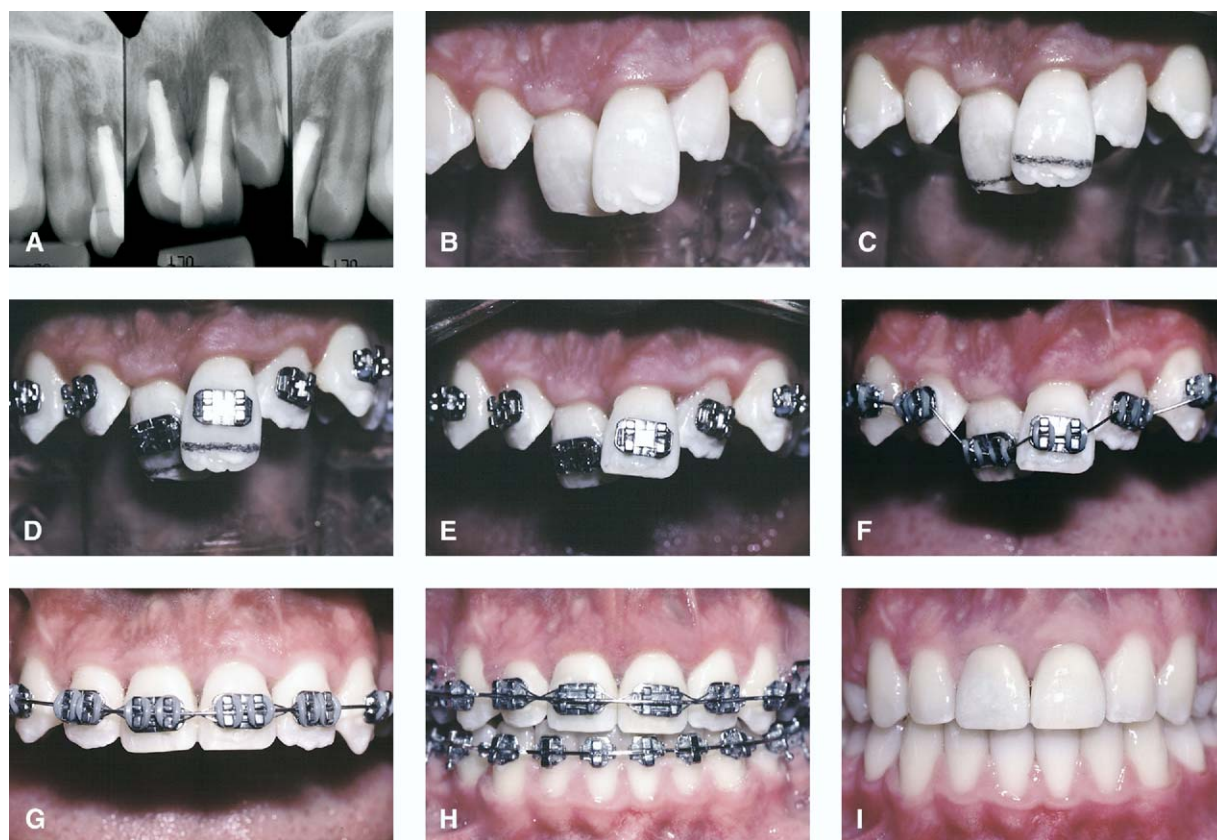
Presented at the Symposium on Early Treatment, January 21-23, 2005; Las Vegas, Nev.

Am J Orthod Dentofacial Orthop 2006;129:S55-63

0889-5406/\$32.00

Copyright © 2006 by the American Association of Orthodontists.

doi:10.1016/j.ajodo.2005.11.007



**Fig 1.** This boy had avulsed his maxillary right and left central incisors at 8 years of age. They were replanted within 1 hour, stabilized with a flexible splint, and root canal therapy was performed (A). Three years later, when all permanent teeth had erupted, the maxillary central incisors had not become ankylosed and were positioned incisal to the posterior occlusal plane (B). Since the crown-to-root ratio was unfavorable and the width-to-length ratio of the central incisor crowns was disproportionate, 2 millimeters of the incisal edge was removed during bracketing (C, D and E). As the maxillary occlusal plane was gradually levelled (F-H), the gingival margin relationship and the esthetic appearance of the anterior teeth was improved. Although the central incisors will probably not survive over this patient's lifetime, the alveolar bone has been maintained and the gingival tissue levels are normal (I), which will enhance either a bridge or implants if the central incisors are eventually lost.

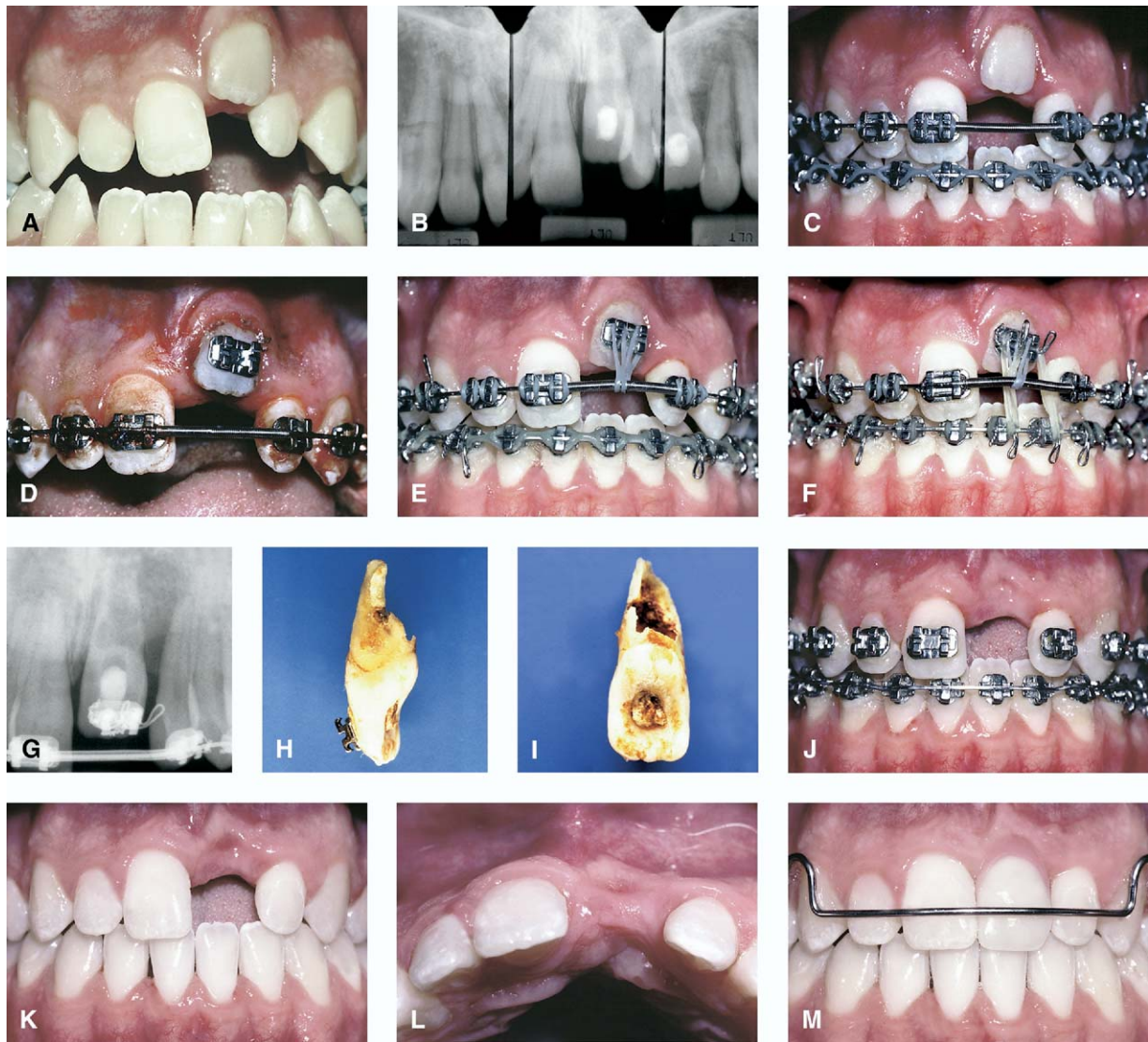
decision was made to align the maxillary and mandibular teeth, close the open bite, open space for the submerged central incisor, and then have it luxated, so it could be erupted. After the first luxation, an extrusive orthodontic force was applied with an elastomeric chain. After 3 months, little progress had been made, and the tooth had lost its mobility. It was luxated a second time, and intra-arch elastomeric traction and interarch use of rubber bands were attempted. However, even though the tooth was mobile, it simply would not erupt. After 6 months of traction with no progress, the tooth was extracted. The root was severely resorbed, and no evidence of a normal periodontium could be found. The edentulous space was maintained

after the orthodontics, but the alveolar ridge had been significantly compromised because of the lack of eruption of the left central incisor, leaving a difficult if not impossible situation to restore in the future.

### Case 3

This girl avulsed her maxillary right central incisor at 7 years 4 months of age (Fig 3). Although the tooth was retrieved, the root was short, not fully developed, and partially fractured during the trauma. Therefore, the option of reimplantation was not possible or reasonable. The option of autotransplantation of a premolar was considered, but the patient did not have a significant arch length discrepancy requiring extraction of

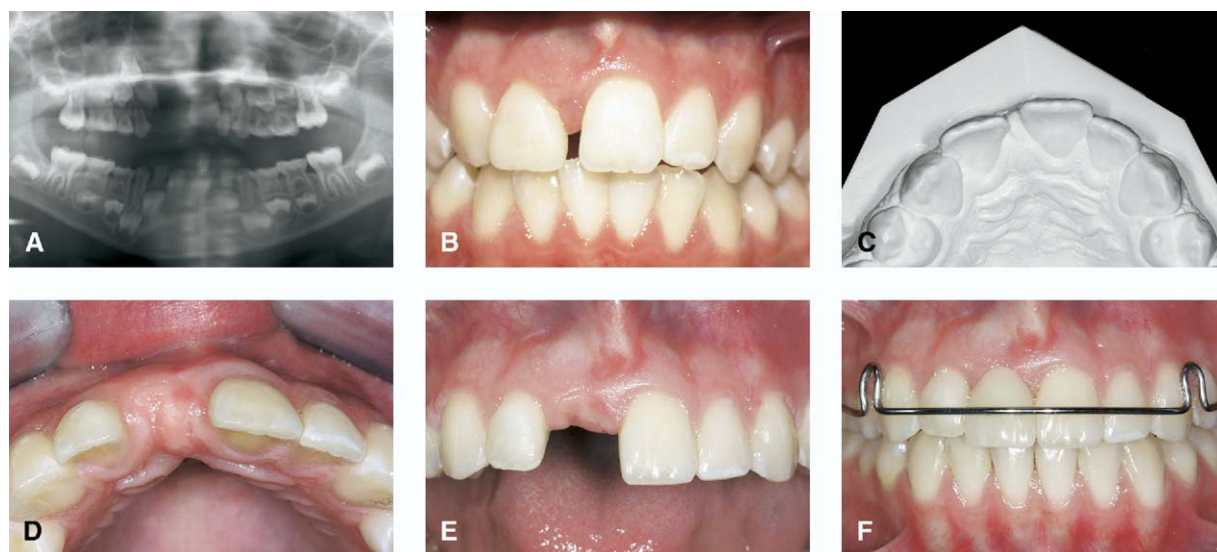




**Fig 2.** This boy had avulsed his maxillary left central incisor at 9 years of age. It was replanted after about 3 hours and rigidly splinted to the adjacent teeth. Unfortunately, the patient was not monitored by the dentist, and after 3 years, the tooth had ankylosed and become submerged apically (A and B). The treatment plan was to align the teeth (C), luxate the ankylosed left central incisor (D), and erupt the tooth incisally (E). After 3 months, the tooth had not responded, so it was luxated again and a stronger eruptive force was used (F). After 6 months a periapical radiograph (G) showed extensive root resorption, and the tooth was extracted. The root had been destroyed gradually by resorption and had no periodontal membrane remaining (H and I). Due to the lack of incisor eruption, the resulting defect in the alveolus was extensive (J-L). Although pink acrylic was added to the tooth on the removable prosthesis (M), this site will be difficult to restore with an implant or fixed restoration due to the tremendous alveolar defect.

teeth. In addition, the roots of the premolars were only about one-third developed; this is not ideal for auto-transplantation. A decision had to be made regarding the anterior edentulous space. A removable prosthesis with a plastic tooth could be used to provide a temporary esthetic replacement. However, without a tooth

developing in this site, the alveolar ridge would be narrow and difficult to restore in the future with either a bridge or an implant. Therefore, nothing was placed in the edentulous site. The space was allowed to close gradually as the right lateral incisor moved mesially and the left central incisor moved across the maxillary



**Fig 3.** This female had avulsed her maxillary right central incisor at 7 years and 4 months of age (A). The tooth root was badly damaged and could not be reimplanted. No space maintenance was provided to allow the right lateral and left central incisor to erupt adjacent to one another (B and C). When all permanent teeth had erupted, a nonextraction treatment plan was selected, and the space for the missing right central incisor was opened (D and E). The alveolar bone thickness in the edentulous site after orthodontics is the result of stretching of the periodontal ligament as the roots were moved apart. A removable retainer with a prosthetic tooth (F) shows that this site will eventually be easy to restore with either an implant or pontic in the future because the alveolar ridge was preserved.

midline. During this time, the maxillary left lateral incisor was temporarily restored with composite to make it wider and less conspicuous.

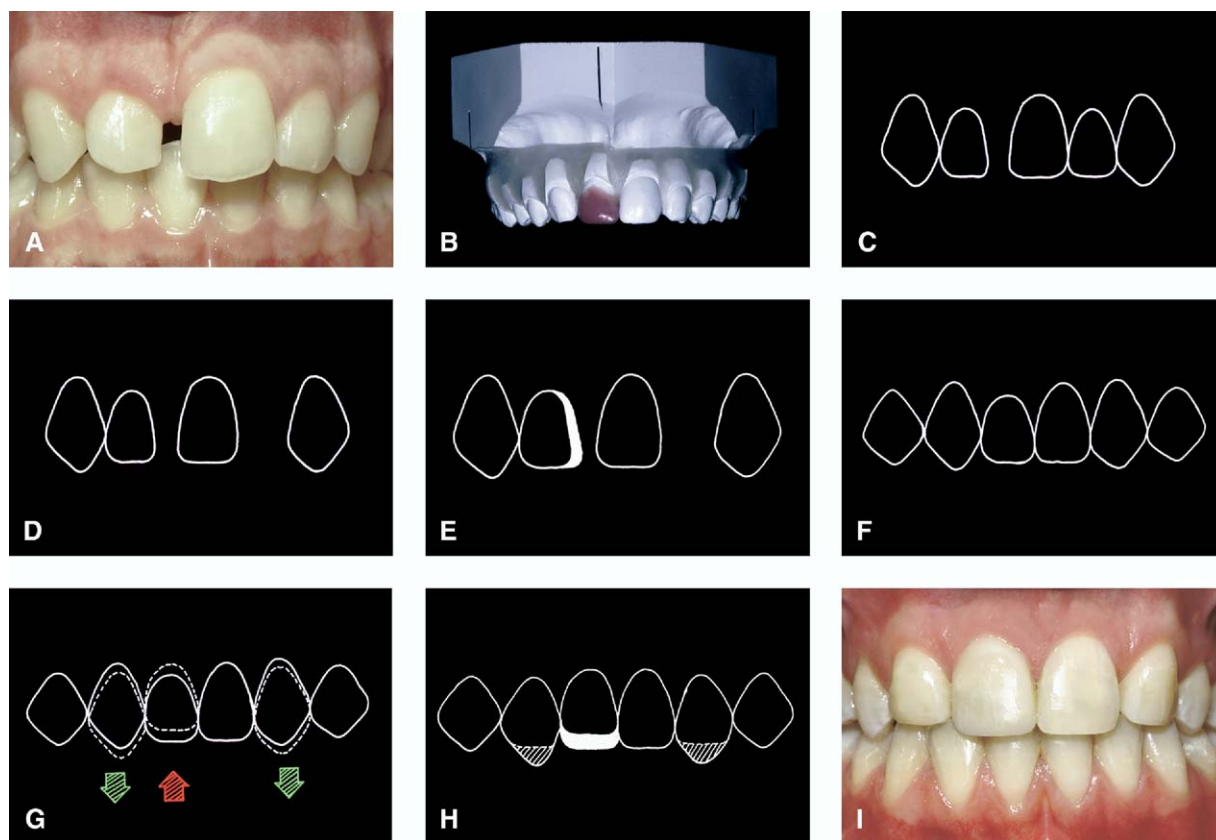
After all permanent teeth had erupted, 2 options were possible for this patient. One involved closing the remaining space and extracting the maxillary left and mandibular right and left first premolars. With this plan, the right lateral incisor could be substituted for a central incisor, and no bridge or implant would be necessary. However, extraction was contraindicated, because the patient had adequate arch length and a good facial profile. Instead, space was opened between the right lateral and left central incisor for a future implant. As the lateral and central were pushed apart, the orthodontic movement developed the necessary ridge thickness for the placement of an implant without the need for a bone graft.

#### Case 4

This girl had avulsed her maxillary right lateral incisor in a horseback-riding accident at about 10 years of age. The tooth could not be found, so there was no possibility of reimplantation. Autotransplantation could have been an option for this patient, by using the maxillary left first premolar as the transplant. However,

this possibility was not suggested to the patient. Although she was given a removable prosthesis, she did not wear it regularly as the remaining teeth began to erupt. As a result, when all teeth were erupted at 14 years of age, the space between the left central and right lateral incisor had closed almost entirely (Fig 4). The patient became concerned about the esthetic appearance of her teeth, and her dentist consulted an orthodontist about treatment options.

The patient had a Class II malocclusion with a reasonably good facial profile and chin projection. She had no crowding in the mandibular arch. A treatment option was to extract 2 maxillary premolars, retract the maxillary anterior teeth, and open a space for an implant or bridge pontic to replace the maxillary right central incisor. Although this was a logical treatment plan, a second option, which would not require recreation of the anterior edentulous space, was proposed. This plan would involve extracting the maxillary left lateral incisor and closing both edentulous spaces, and substituting the right lateral incisor for a central incisor and the canines for lateral incisors. A diagnostic wax setup was constructed to simulate this option. The diagnostic setup confirmed that this option would produce a successful esthetic and functional result, if the remain-



**Fig 4.** This female had avulsed her maxillary right central incisor at 10 years of age and did not wear her removable prosthesis. By 14 years of age, the right central incisor space had closed (A) and the patient was concerned about her appearance. A diagnostic wax setup (B) showed that the maxillary left lateral incisor could be extracted, and the spaces could be closed with the right lateral incisor substituting for the right central incisor and the canines for lateral incisors. The diagrams (C-H) show the steps necessary to make the result look esthetic; the key was to level the gingival margins of the anterior teeth by intruding the right lateral incisor and extruding the right and left canines. The incisal edges were adjusted by restoring the right lateral incisal edge and equilibrating the canines. The final result (I) shows that lateral and canine substitution can be an effective plan for treating a missing maxillary central incisor.

ing anterior teeth could be extruded (canines) and intruded (right lateral incisor) to create gingival levels that would simulate a normal relationship of maxillary anterior teeth.

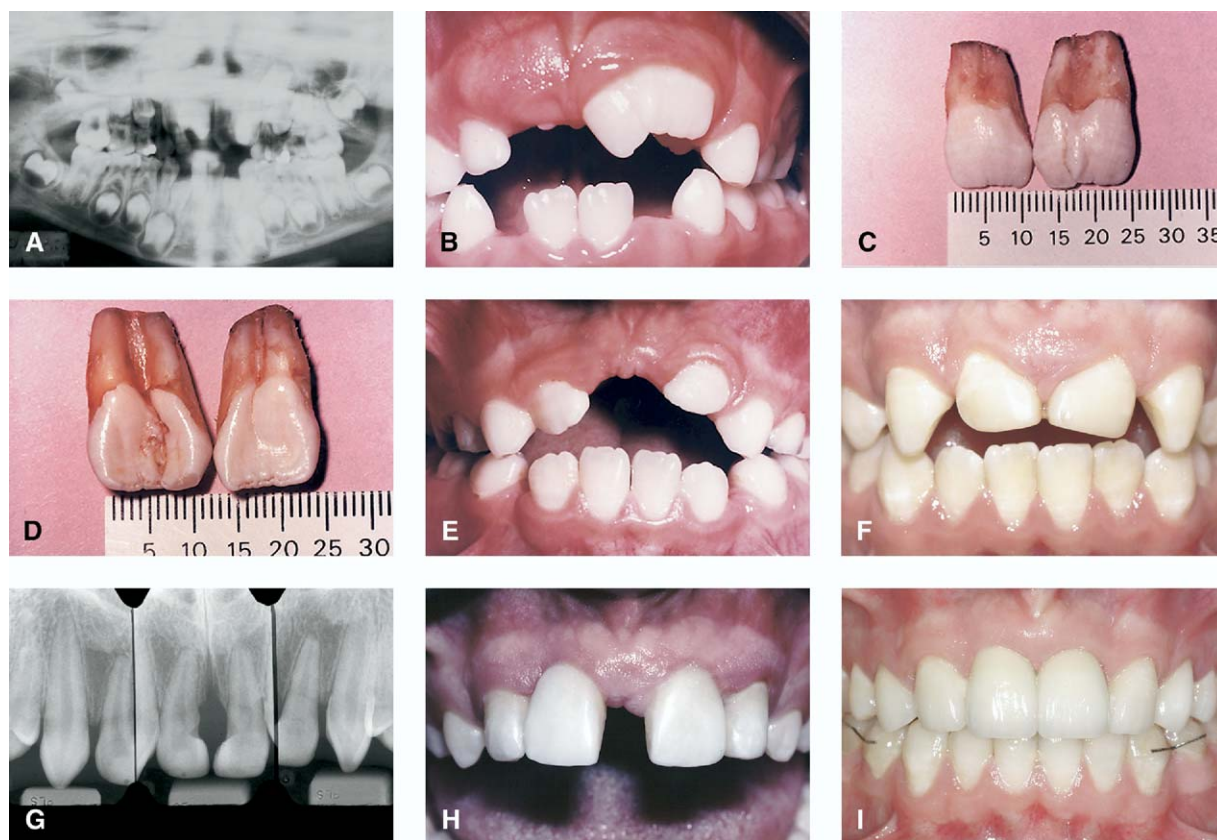
#### Case 5

This boy had 2 macrodontic maxillary central incisors. They were not discovered until the primary central incisors had exfoliated and the left permanent central incisor began to erupt (Fig 5). A panoramic radiograph showed that the left central incisor was also large, and it was estimated that the combined widths of the 2 central incisors would be greater than 25 mm. Normally, maxillary central incisor width averages about 9 mm, so these teeth would be grossly dispro-

portionate. The roots also were wide, so it was not possible to section the teeth and keep part of the root and crown. The parents were advised that the teeth should be extracted immediately to prevent significant tooth malposition during the eruption of the remaining maxillary anterior teeth. Autotransplantation of 2 mandibular first premolars would have been an option to replace the central incisors; however, the degree of root development of the mandibular premolars was less than ideal.

Although a definitive decision regarding the final occlusal scheme for this patient was not determined at the time of extraction of the central incisors, several options were possible. To preserve the bony alveolus during this patient's growth and tooth erup-





**Fig 5.** This male had 2 macrodontic central incisors that were not discovered until the left central had begun to erupt (**A** and **B**). The roots were also large, so the only solution was to extract both teeth at 7 years of age (**C** and **D**). To allow some of the space to close, no prosthesis was worn. By 9 years of age, the lateral incisors had drifted bodily toward the midline and were 8 millimeters apart, compared with 25 millimeters previously. The laterals were temporarily built-up with composite, and the remaining space was closed orthodontically (**F** and **G**). At 17 years of age, the patient was unhappy with his appearance, so the laterals were provisionalized as central incisors, and the canines were provisionalized as laterals (**H**). Two mandibular premolars were extracted to compensate for the 2 missing maxillary central incisors and the spaces were closed. After orthodontics, the laterals and canines restored with porcelain restorations (**I**). This plan was successful at maintaining the alveolar ridge, establishing a satisfactory occlusion, and creating an esthetic final result.

tion, no prosthesis was placed in the maxilla. The maxillary central incisors were allowed to erupt toward each other. After they had erupted, they were temporarily built up with composite to partially reduce the diastema. Finally, when all teeth had erupted, a diagnostic wax setup was constructed to simulate complete closure of the anterior edentulous space, substituting the lateral incisors for central incisors. Two mandibular premolars were extracted to provide a Class I molar relationship at the end of treatment. By intruding the maxillary lateral incisors and placing restorations with appropriate width, length, and shape, the final result was esthetically and functionally acceptable.

## DISCUSSION

This article describes a strategy for treating children who either have avulsed or must lose 1 or 2 maxillary central incisors. The most conservative approach for managing the avulsed central incisor is to reimplant it as soon as possible.<sup>1</sup> However, the clinician must ask 4 questions. First, is the tooth retrievable and undamaged? In some situations, the avulsed tooth cannot be found. In others, the tooth is located, but the root has fractured. Second, is the time interval between avulsion and reimplantation reasonable? A good guideline is 30 minutes,<sup>1,5</sup> or at least less than 1 hour. As the time out of the tooth socket increases, the potential for dessica-

tion of the root and periodontal ligament increases.<sup>5</sup> If the periodontal ligament is irreversibly damaged, ankylosis will result. Third, has the tooth been maintained in a moist environment? Placing the tooth in the patient's saliva, milk, or even room temperature water will help to avoid drying and prolong the life of the periodontal ligament to ensure a successful reimplantation.<sup>1</sup> Fourth, can successful root canal therapy be performed? In some children, the apex of the tooth is open, and root canal therapy could be challenging. In these situations, the tooth can still be reimplanted, but an apexification procedure or root-end induction might be necessary. The orthodontist and the restorative dentist should consult an endodontist, if possible, when making the decision to reimplant the avulsed tooth. The greatest benefit of successful reimplantation of an avulsed tooth is preservation of the alveolar bone. Even if the reimplanted tooth must be extracted later, the improvement in alveolar development will provide better options for restoration of the site later.<sup>8</sup>

If an avulsed tooth is reimplanted, it must be splinted with a flexible wire<sup>1,9</sup> and observed and followed over time to verify that it is erupting along with the adjacent teeth. If the implanted tooth becomes ankylosed, it obviously will not erupt and could create a significant alveolar defect. If the patient is young and has significant growth remaining, the vertical discrepancy is magnified. Annual recall visits to the dentist or orthodontist will allow the clinician to determine whether ankylosis occurs. If the tooth becomes ankylosed, the clinician must determine the patient's age and potential for further facial growth. If the patient is a girl 13 to 14 years of age, there might be little facial growth potential remaining, and maintaining the ankylosed tooth might not create a significant difference in vertical tooth position. However, in a boy 13 to 14 years of age, there still could be significant facial growth, and an ankylosed tooth should be extracted to prevent a vertical alveolar defect. Case 2 shows the problem if an ankylosed central incisor is allowed to remain in the alveolus. If this tooth had been extracted earlier, the significant vertical alveolar defect would not have occurred. Previous research has shown that, when teeth are extracted in growing patients, although alveolar thickness tends to narrow from 25% to 30%, vertical alveolar development of the edentulous ridge maintains pace with the adjacent teeth as they erupt.<sup>10</sup>

Luxation and eruption of ankylosed teeth have been proposed to overcome a vertical discrepancy in tooth position. However, once a tooth has ankylosed, the root undergoes replacement resorption, and the periodontal ligament gradually disappears. Therefore, even though the root can be luxated and appears mobile, it might not

respond to eruption, because of the lack of fibrous ligament around the root and because the interdigitation of the bone and cemental surface prevents rapid eruption of the luxated root.<sup>11</sup> Luxation was attempted twice in case 2, but the tooth would not erupt, even though it was extremely mobile. The photograph of the root after extraction shows the irregular surface of the root and helps explain the difficulty in achieving a positive response to an eruptive orthodontic force. In this patient, perhaps sectioning of the alveolus and distraction osteogenesis would have been a better option for erupting the ankylosed tooth.<sup>12</sup>

If an avulsed tooth cannot be located or is not a good candidate for reimplantation, autotransplantation should be considered.<sup>13-17</sup> Specific criteria should be considered before embarking on this treatment. First, the patient should have an arch-length deficiency that would require extraction of permanent premolars. In this situation, a premolar could be transplanted to the edentulous maxillary incisor site. Second, the root formation of the premolars should be between one-half and two-thirds developed. Previous research has shown that autotransplantation can be performed on short underdeveloped roots or completely developed roots, but the success rates are not as high as when the roots are between one-half and two-thirds developed. Even in an ideal situation, autotransplantation is unpredictable in the hands of an inexperienced surgeon. The technique for extracting and reimplanting an existing root and crown without damaging the tissues surrounding the root is difficult and requires experience and a delicate approach. Surgeons with the most experience and the highest success rates are found in the Scandinavian countries,<sup>15</sup> whereas few cases of autotransplantation are attempted and reported in the United States.

If an avulsed tooth cannot be reimplanted and autotransplantation is not possible, the decision of what to do with the edentulous space becomes the immediate concern of the parent, the child, and the dentist or orthodontist. A typical solution for obturating the edentulous space is to construct a temporary removable prosthesis with a plastic tooth. This will improve esthetics, speech, and function. However, if the child avulses the tooth at a young age, esthetics and function might not be great concerns, and children can usually accommodate their speech and articulation in spite of a missing maxillary central incisor. So, in the young patient, it can be advantageous to place nothing in the edentulous space. This choice will allow the adjacent teeth to erupt together and close the edentulous space. A distinct advantage is that the erupting teeth will drift bodily in a growing child and therefore bring the alveolar bone as well. In an adult with no remaining

vertical facial growth, teeth adjacent to an edentulous space tend to tip together rather than drift bodily. If the edentulous space completely closes by the time the child has erupted all remaining teeth, the clinician has several treatment options. The space can be opened to create space for an implant or bridge pontic, or the maxillary lateral incisor can be substituted for the maxillary central incisor.

When the lateral incisor and contralateral central incisor are pushed apart to create space for a missing central incisor, alveolar bone is created in the developing edentulous space. The thickness of the bone is similar to the width of the roots of the adjacent central and lateral incisors. This process is called orthodontic site development. Research has shown that the buccolingual thickness of the alveolus produced during orthodontic site development does not resorb and become narrower with time.<sup>18</sup> Therefore, the edentulous ridge provides a much better site for either a pontic or an implant. If an edentulous space is maintained during the transition from the mixed to the permanent dentitions, the thickness of the alveolus will be deficient and could require a bone or a soft-tissue graft to enhance the esthetic appearance of an implant or a pontic, respectively. In case 3, the edentulous space from the avulsed right central incisor was allowed to close during childhood and early adolescence. When the space was reopened orthodontically, the thickness of the edentulous ridge was enhanced; this made the placement of an implant in this site much more predictable.

Another option for overcoming a missing maxillary central incisor is to substitute the maxillary lateral incisor for the central in the final occlusal scheme.<sup>7,11</sup> This treatment plan is not always appropriate. For example, in case 3, lateral incisor substitution could have been an option. However, it would have required extraction of 3 additional premolars (maxillary left and mandibular right and left posterior quadrants). Because the patient had no arch-length deficiency, and her facial profile was ideal, tooth extraction was not possible. So the space was opened for a restoration. However, in case 4, the patient had a Class II malocclusion with no crowding in the mandibular arch. Her facial profile was satisfactory, so extraction of 1 additional maxillary tooth on the left side would permit substitution of the lateral incisor. To determine whether this plan would be feasible occlusally, a diagnostic wax setup was constructed.<sup>19</sup> It showed that the occlusion would be satisfactory. To make the job of matching crown lengths and shapes of contralateral teeth easier, the maxillary left lateral was extracted. Because the edentulous space was allowed to close spontaneously after avulsion, the orthodontic mechanics were simplified in this case.

When a lateral incisor is substituted for a missing maxillary central incisor, several important steps will ensure an esthetic result. First, the gingival margins of the maxillary anterior teeth must be positioned properly.<sup>7,19-22</sup> When a lateral is substituted for a central, the canines are substituted for the lateral incisors. In this situation, the orthodontist must disregard the incisal edges of these teeth as a guide for final tooth positioning. During orthodontic treatment, the maxillary canines must be extruded to move their gingival margins incisally to resemble the usual gingival margin position of lateral incisors. The lateral incisor must be intruded significantly so that its gingival margin matches the adjacent central incisor. This type of tooth movement was accomplished in cases 4 and 5, and creates the illusion of normal anterior gingival levels. An additional benefit of intruding the lateral incisor is to facilitate restoration of this tooth into the shape of a central incisor. Because the lateral incisor must be grossly overcontoured, this type of restoration is easier when the clinician has a longer rather than a shorter tooth to restore.<sup>7</sup> Additionally, when a lateral is substituted for a central incisor, the provisional restoration should have a shape on the mesial surface that matches the adjacent central incisor. The emergence profile of a maxillary central incisor is generally flat on the mesial surface. The orthodontist must move the lateral incisor close enough to the central incisor to allow the restorative dentist to contour the restoration properly (cases 4 and 5).

Finally, a maxillary central incisor might be larger than normal because of gemination or fusion of the crowns or roots.<sup>2,3</sup> If the resulting macrodontic tooth has a wide root that cannot be reduced, it is extremely difficult to make the wide tooth look natural. If a macrodontic tooth is left in the dental arch, it will severely compromise the eruption of adjacent teeth. However, if macrodontic teeth are extracted, there will be a large edentulous space, and the thickness of the alveolus in that region could be compromised. In these situations, the macrodontic teeth must be extracted as soon as possible. The orthodontist and the restorative dentist must be aggressive in this situation. If the malformed teeth are removed early as in case 5, the adjacent lateral incisors will drift and erupt bodily toward each other. This improves the esthetics during the transition from the mixed to the permanent dentition. More importantly, this strategy facilitates either space opening or lateral incisor substitution, when it is time to begin orthodontic therapy.

## CONCLUSIONS

This article has presented and discussed the early management and treatment of 5 patients, who were



missing at least 1 maxillary central incisor at early ages. Several solutions were presented. Unfortunately, in these situations, bold decisions must often be made quickly, because the loss of a maxillary central incisor typically occurs accidentally or as the result of intentional extraction of a malformed tooth. This information should give the clinician some helpful guidelines for managing patients with missing maxillary central incisors.

## REFERENCES

1. Trope M. Avulsion and replantation. *Refuat Hapeh Vehashinayim* 2002;19:6-15.
2. Gazit E, Lieberman MA. Macrodontia of maxillary central incisors: case reports. *Quintessence Int* 1991;22:883-7.
3. Hellekant M, Twetman S, Carlsson L. Treatment of a Class II Division 1 malocclusion with macrodontia of the maxillary central incisors. *Am J Orthod Dentofacial Orthop* 2001;119:654-9.
4. Ongkorahadjo A, Kusnoto B. The use of pre-implantation tooth lengths in the treatment of avulsed teeth. *J Clin Pediatr Dent* 2000;24:91-5.
5. Kandemir S, Alpoz E, Caliskan M, Alpoz A. Complete replacement resorption after replantation of maxillary incisors: report of a case. *J Clin Pediatr Dent* 1999;23:343-6.
6. Bowden D, Patel H. Autotransplantation of premolar teeth to replace missing maxillary central incisors. *Br J Orthod* 1990;17:21-8.
7. Kokich V, Nappen D, Shapiro P. Gingival contour and clinical crown length: their effects on the esthetic appearance of maxillary anterior teeth. *Am J Orthod* 1984;86:89-94.
8. Martins W, Westphalen V, Westphalen F. Tooth replantation after traumatic avulsion: a 27-year follow-up. *Dent Traumatol* 2004;20:101-5.
9. Gupta S, Sharma A, Dang N. Suture splint: an alternative for luxation injuries of teeth in pediatric patients—a case report. *J Clin Pediatr Dent* 1997;22:19-21.
10. Ostler MS, Kokich VG. Alveolar ridge changes in patients congenitally missing mandibular second premolars. *J Prosthet Dent* 1994;71:144-9.
11. Kramer P, Horst S, Konig J, Reston E, Ernani C. Rehabilitative treatment after unsuccessful teeth replantation: a case report. *J Clin Pediatr Dent* 2002;26:119-24.
12. Koford T, Wurtz V, Melsen B. Treatment of an ankylosed central incisor with single-tooth osteotomy and a simple distraction device. *Am J Orthod Dentofacial Orthop* 2005;127:72-80.
13. Czochrowska E, Stenvik A, Album B, Zachrisson B. Autotransplantation of premolars to replace maxillary incisors: a comparison with natural incisors. *Am J Orthod Dentofacial Orthop* 2000;118:592-600.
14. Paulsen H, Shi X, Welander U, Huggare J, Scheutz F. Eruption pattern of autotransplanted premolars visualized by radiographic color-coding. *Am J Orthod Dentofacial Orthop* 2001;119:338-45.
15. Czochrowska E, Stenvik A, Zachrisson B. The esthetic outcome of autotransplanted premolars replacing maxillary incisors. *Dent Traumatol* 2002;118:237-45.
16. Czochrowska E, Stenvik A, Bjercke B, Zachrisson B. Outcome of tooth transplantation: survival and success rates 17-41 years posttreatment. *Am J Orthod Dentofacial Orthop* 2002;121:110-9.
17. Zachrisson B, Stenvik A, Haanaes H. Management of missing maxillary anterior teeth with emphasis on autotransplantation. *Am J Orthod Dentofacial Orthop* 2004;126:284-8.
18. Spear F, Mathews D, Kokich VG. Interdisciplinary management of single-tooth implants. *Semin Orthod* 1997;3:45-72.
19. Kokich VG, Kokich VO. Interrelationship of orthodontics with periodontics and restorative dentistry. In: Nanda R, editor. *Biomechanics and esthetic strategies in clinical orthodontics*. St. Louis: Elsevier; 2005.
20. Kokich V. Anterior dental esthetics: an orthodontic perspective I. Crown length. *J Esthet Dent* 1993;5:19-23.
21. Kokich VG, Spear F. Guidelines for managing the orthodontic-restorative patient. *Semin Orthod* 1997;3:3-20.
22. Kokich VG. Esthetics and vertical tooth position: the orthodontic possibilities. *Compendium Cont Ed Dent* 1997;18:1225-31.