

Interdisciplinary Management of Anterior Guidance: A Case Report

A common objective of anterior restorative dentistry is to establish incisal guidance between the maxillary and mandibular anterior teeth to disclude the posterior teeth during protrusive mandibular movement.¹⁻⁴ However, this goal is difficult to achieve in a patient with significant wear or abrasion and excess anterior overjet. How does the restorative dentist provide for immediate incisal guidance when the patient has short, abraded anterior teeth and a 6-mm overjet? This is a common dilemma for the restorative dentist. However, with the possibility of moving the anterior teeth orthodontically, the restorative dentist can achieve better anterior guidance for the patient. Achieving anterior guidance with orthodontics could involve retraction of maxillary incisors, proclination of mandibular incisors, extrusion of either maxillary or mandibular incisors, jaw surgery, or a combination of these alternatives. This case report will describe how anterior guidance was achieved in an adult female using an interdisciplinary approach

DIAGNOSIS AND ETIOLOGY

This 54-year-old woman wanted to improve the esthetics of her smile. She had abraded her maxillary central incisors from a protrusive bruxing habit. As a result of the wear, the teeth had continued to erupt and the gingival margins of the maxillary central incisors were below the gingival levels of the maxillary lateral incisors (Figure 1). In addition, the maxillary central incisors were retroclined lingually. The patient had a relatively deep overbite and a 5-mm overjet. The posterior occlusion was Angle Class I on her right side, but was Class II on her left side (Figure 1). Part of the etiology of the posterior malocclusion was due to a congenitally missing

mandibular left second premolar, which allowed the mandibular midline to shift to the left. With this shift, the mandibular incisors also were positioned slightly lingually.

The patient's gingival health was reasonably good and her oral hygiene was satisfactory. Sulcus depths were in the normal range in most areas, with no bleeding on probing. Her temporomandibular joints were asymptomatic and she only complained of mild muscle aches from the protrusive bruxing habit. Besides missing the mandibular left second premolar, the maxillary left first molar also had been extracted previously due to caries. Sufficient space existed for a replacement tooth in the maxillary left posterior region; however, insufficient space existed for a replacement for the missing mandibular left second premolar (Figure 1). The patient also had mild crowding and overlap of the mandibular incisors. Her goal was to have better smile esthetics.

TREATMENT OBJECTIVES

The restorative objectives for this patient included:

- restoration of the maxillary and mandibular left edentulous spaces;
- restoration of the abraded maxillary incisors;
- improving posterior occlusal contacts;
- establishing adequate incisal guidance;
- correcting the maxillary anterior gingival margin relationships; and
- improving anterior tooth alignment.

Most of these objectives could be managed with conventional restorative techniques, except for the correction of the gingival margin levels and the creation of adequate incisal guidance. In addition, the edentulous space on the

Vincent G. Kokich, DDS, MSD
Professor
Department Of Orthodontics
School of Dentistry
University Of Washington
Seattle, Washington

Frank M. Spear, DDS, MSD
Founder and Director
Seattle Institute for Advanced
Dental Education
Seattle, Washington

Affiliate Assistant Professor
University of Washington
School of Dentistry
Seattle, Washington

Private Practice
Seattle, Washington

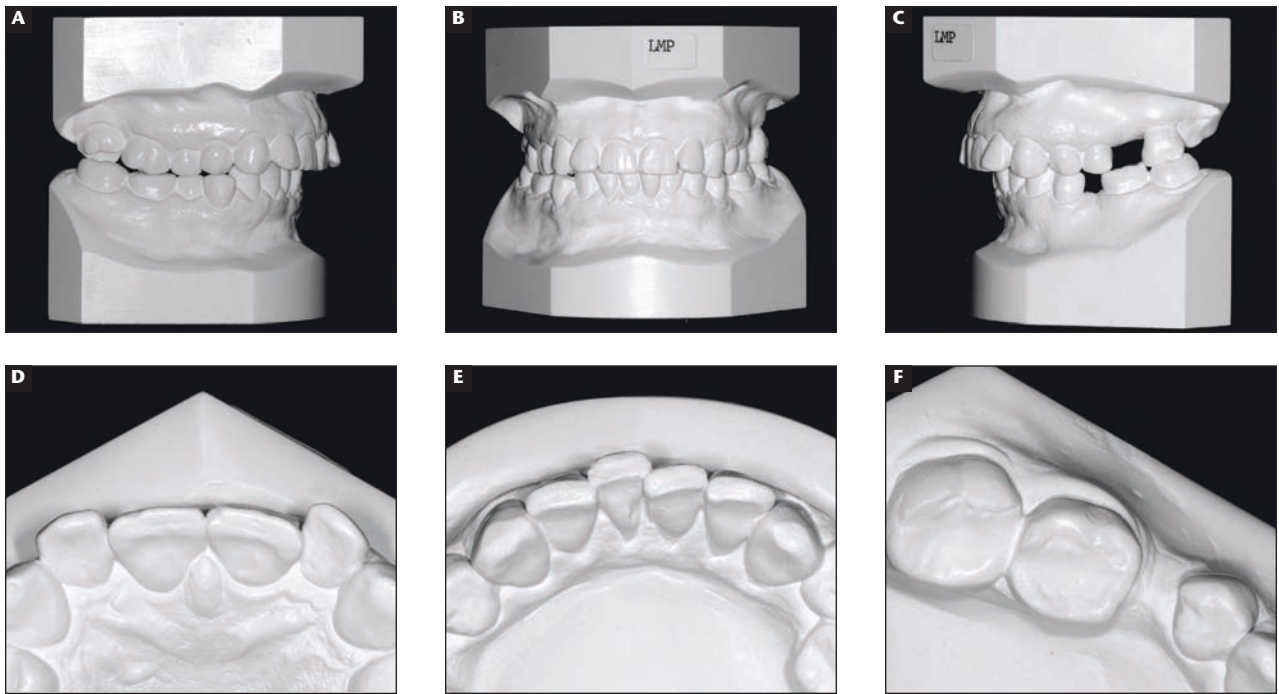


Figure 1A through Figure 1F This 54-year old woman was unhappy with the appearance of her maxillary anterior teeth. She had an Angle Class I relationship on the right side (A), and a Class II relationship on the left side (B), which produced a deviation between the maxillary and mandibular dental midlines (C). Her maxillary incisors were retroclined and abraded (D) and her mandibular incisors were mildly crowded (E). The mandibular left second premolar was congenitally absent and the space had partially closed (F) with shifting of the mandibular midline to the left.

mandibular left side was too narrow for a proper-sized tooth. It was determined that her edentulous spaces would be restored with fixed bridges, because of the existing restorations in the abutment teeth and the lack of bone support for implants in the edentulous sites. To achieve all of the restorative objectives, it was decided that orthodontics should be a part of the treatment plan. The orthodontic objectives for this patient included:

- reduction of the anterior overjet;
- reduction of anterior overbite;
- establishing adequate incisal guidance;
- alignment of the anterior teeth;
- correction of the deviated mandibular midline;
- establishing a Class I canine relationship on the left side;
- opening space for a larger pontic in the mandibular left posterior segment; and
- leveling of the maxillary anterior gingival margins.

TREATMENT ALTERNATIVES

Several orthodontic treatment alternatives could have been employed to

achieve these aforementioned goals or objectives:

1. Extraction of the maxillary right first premolar and mandibular right first premolar and closure of all edentulous spaces. This would have reduced the overjet and established adequate incisal guidance for the restorative dentist. However, the antero-posterior relationship of the maxillary incisors to the upper lip was acceptable (Figure 2). Extraction of the teeth and closure of the extraction spaces would have retracted the maxillary incisors, thereby retracting the patient's upper lip, which would have produced a negative effect on her profile. Therefore, this plan was rejected.
2. A second alternative for establishing anterior guidance and reducing the overjet was to extract the mandibular right second premolar and close the spaces on both sides in the mandibular arch to correct the mandibular dental midline. Then a bilateral sagittal mandibular osteotomy would be performed to lengthen the

mandible and move the mandibular incisors into proper contact with the maxillary incisors. However, this plan was rejected because the patient's chin projection was acceptable before treatment (Figure 2) and did not need to be advanced forward.

3. A third alternative to reduce anterior overjet and establish anterior guidance was to advance and procline the mandibular incisors in a labial direction to provide contact with the maxillary incisors. This would also allow opening of the mandibular left edentulous space to create an adequate-sized pontic. This plan would provide for the best profile result, avoid jaw surgery, and facilitate all of the restorative objectives. To determine if this plan would produce the correct occlusal relationship for the restorative dentist, the orthodontist constructed a diagnostic wax-up simulating the anticipated outcome of treatment (Figure 2). This wax-up provided the dentist, orthodontist, and the patient with the same vision of what could be accomplished. Because the wax-up

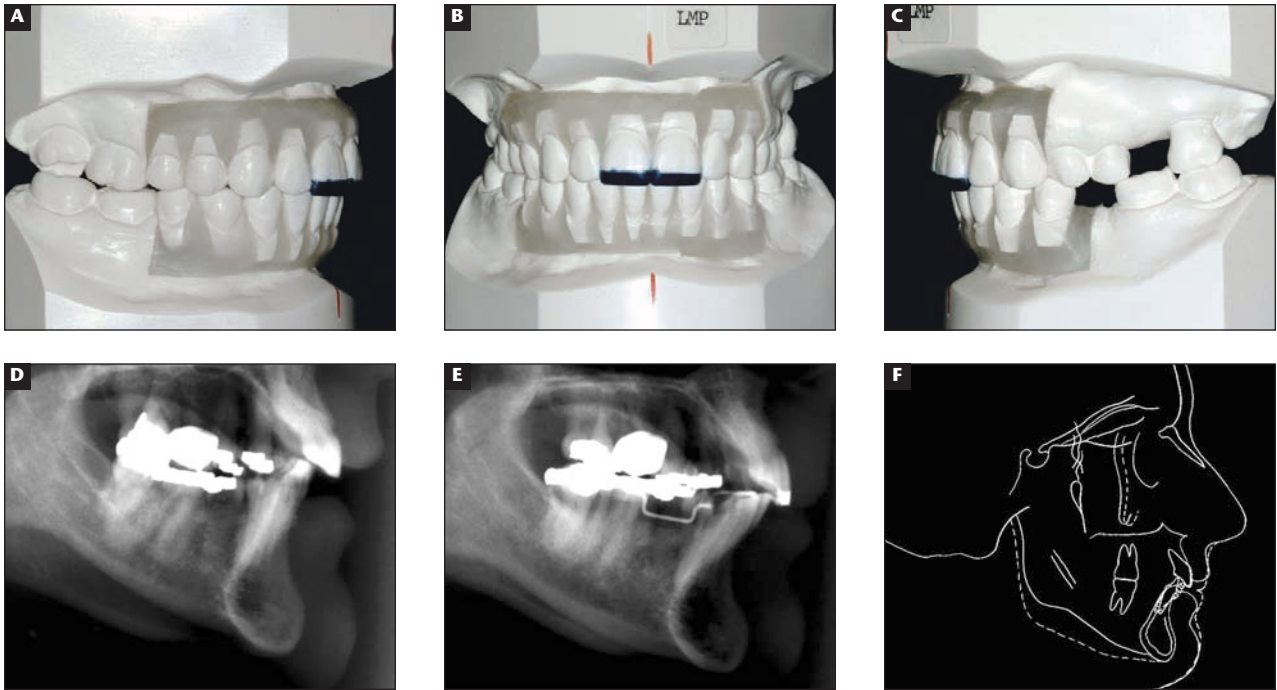


Figure 2A through Figure 2F A diagnostic wax set-up (A, B, C) was constructed to simulate the orthodontic and restorative treatment plans. The mandibular incisors were originally positioned lingual to their desired position (D) relative the chin and lower lip. During orthodontics, the mandibular incisors were proclined nearly 3 mm at the incisal edge (E, F) to gain anterior guidance.

showed that all objectives could be achieved, this orthodontic treatment plan was selected.

TREATMENT PROGRESS

Before orthodontic treatment, some of the patient's questionable restorations were temporarily reinforced to provide adequate strength to withstand 18 months of orthodontics. In addition, she had a thorough root planing and scaling before orthodontic banding and then maintenance appointments for tooth cleaning every 4 months during active orthodontics.

Orthodontic brackets were placed on all teeth in both arches. The brackets on the maxillary central incisors were placed closer to the incisal edges to facilitate intrusion of these teeth to move their gingival margins apically and allow for restoration of their incisal edges (Figure 3). This would recreate the correct width-to-length proportion of these teeth. After alignment of the maxillary arch, the mandibular orthodontic brackets were placed on the teeth and a spring was used to open space between the mandibular left first molar and first premolar. This movement helped to create an Angle Class I

canine relationship on the left side and produced proclination of the mandibular incisors, which helped to establish maxillary and mandibular incisal contact and anterior guidance.

After all of the orthodontic objectives had been accomplished, the patient's brackets were removed and orthodontic retainers were placed in both arches to stabilize the treatment result. After about 6 months of retention, provisional restorations were placed on those teeth that required restoration. The provisional restorations were left in place for an additional 6 months to determine the patient's response to her new occlusal relationship. One year after orthodontic treatment had been completed, the final restorations were placed, including three-unit fixed bridges in the maxillary and mandibular left posterior segments (Figure 3).

TREATMENT RESULTS

This interdisciplinary approach to managing this patient's occlusal, gingival, and esthetic discrepancies allowed the team to achieve all of the restorative and orthodontic objectives that were established before treatment. Her facial profile did not change. Her maxillary anterior dental esthetics has been

improved with the intrusion of the maxillary central incisors and restoration of these previously abraded teeth (Figure 3). The maxillary and mandibular dental midlines are now coincident. The patient has canine-protected occlusion bilaterally with no balancing interferences. The sizes of the pontic spaces for the fixed bridges were improved (Figure 3). And perhaps most important, adequate incisal guidance in protrusive position was established for this patient as a result of the combined orthodontic and restorative treatment plan.

DISCUSSION

Establishing incisal contact in centric occlusion and immediate incisal guidance in protrusive position are typical goals when restoring the maxillary anterior teeth.¹⁻⁴ However, this objective is difficult to achieve when the patient has excessive overjet. Orthodontics and/or orthognathic surgery can be used to reduce excessive overjet and create anterior guidance. As in this patient, there are several options available to correct an excessive overjet. These include retraction of the maxillary incisors, proclination of the mandibular incisors, eruption of either the maxillary or

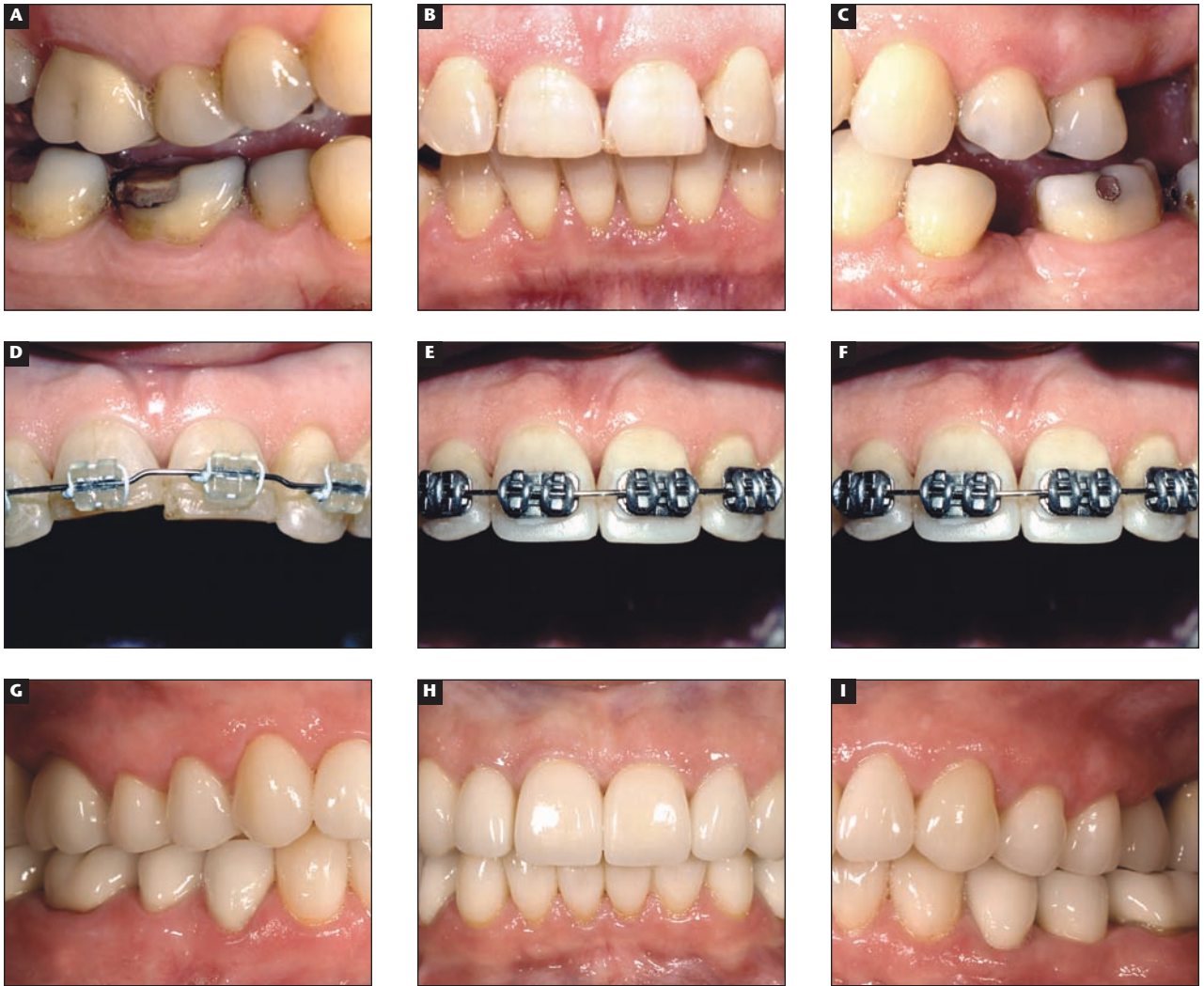


Figure 3A through Figure 3I The patient's initial occlusion showed signs of wear and tooth drifting (A, B, C). To level the gingival margins, the maxillary incisors were intruded (D), provisionalized with composite (E), and retained in that position with brackets and archwires (F) for 6 months. One year after completion of orthodontic therapy, the final porcelain restorations were placed (G, H, I), which established an excellent, well-balanced, and healthy dentition.

mandibular incisors, orthognathic surgery, or a combination of these techniques. The decision of which technique to select depends on the patient's facial profile, the position of the mandible relative to the face, and the upper and lower lip support provided by the maxillary and mandibular incisors. In our patient, her chin prominence was acceptable, which eliminated jaw surgery as an option. Her upper-lip-to-nose relationship was acceptable, which eliminated retraction of the maxillary incisors as an option. The overbite was already deep and needed to be reduced, which eliminated tooth eruption as an option. The remaining option of proclining the mandibular incisors to achieve incisal contact and anterior guidance was the only logical solution.

When mandibular incisors are proclined labially, there are some concerns about stability. Posttreatment evaluation of patients whose teeth have been proclined during orthodontics shows that there is a tendency for these teeth to move lingually if they are not supported by a retainer.⁵ Therefore, in our patient, a bonded mandibular lingual retainer was used to help support the forward position of the mandibular incisors. This retainer will need to be maintained indefinitely to maintain the mandibular incisor position.

Another concern about proclining the mandibular incisors is the possibility of gingival recession labial to the mandibular incisor roots.⁶ Recession did not occur in our patient. What should the clinician look for to determine if

gingival recession is possible or likely during mandibular incisor proclination? The patient's gingival tissue biotype probably plays a role in providing protection against gingival recession. If a patient has a thicker biotype, as was the case in our patient, the risk of recession is probably reduced.⁷ However, with a thin tissue biotype, recession may be more of a risk. Second would be the amount of attached gingiva. If the amount of gingiva labial to the mandibular incisors is only 1 mm and the patient has a 1-mm gingival sulcus, then there is no attached gingiva. This situation could provide little resistance to recession if teeth are proclined. The third point to remember is that recession of the gingiva cannot occur if there is no bony dehiscence labial to a mandibular incisor.⁸

If a dehiscence were present in a patient with inadequate attached gingiva or a thin tissue biotype or both, then proclination of the mandibular incisors is risky without considering a connective tissue graft to reinforce the zone of gingiva labial to the mandibular incisors.

Another important aspect of this patient's treatment was correcting the gingival levels of the maxillary anterior teeth during the orthodontic therapy. Anterior gingival margin discrepancies in adults are typically due to wear or abrasion of the maxillary incisal edges and compensatory eruption of the incisors causing uneven gingival levels and unequal crown length of adjacent teeth. The treatment for this problem could consist of periodontal crown lengthening to level the gingival margins, orthodontic extrusion of the longer central incisor, or intrusion and restoration of the short tooth or teeth.⁹ To diagnose this problem adequately, the clinician must first evaluate the labial sulcular depth of the maxillary incisors. If the sulcular depths are uniformly 1 mm, then the discrepancy in gingival margins may be due to uneven wear or trauma of the incisal edges of the anterior teeth. In these situations, the clinician must decide if the amount of gingival discrepancy will be noticeable. If so, bracketing and alignment of these teeth must be accomplished in a way that improves the esthetics and restorability of the abraded teeth. In these situations, the gingival margins are used as a guide in tooth positioning, not the incisal edges.¹⁰ As the gingival margins are aligned, the discrepancy in the incisal edges becomes more apparent. These incisal discrepancies are restored with composite restorations temporarily, and then

This interdisciplinary approach to managing this patient's ... discrepancies allowed the team to achieve all of the restorative and orthodontic objectives. . .

restored permanently with porcelain veneer or crown restorations after the teeth have stabilized.

If the gingival margin discrepancies are corrected by leveling the gingival margins orthodontically, these tooth positions should be maintained for at least 6 months to avoid relapse. As teeth are intruded, the orientation of the periodontal fibers changes and becomes more oblique.¹¹ It typically takes at least 6 months for these fibers to reorient themselves in a horizontal position and stabilize the tooth. A method of retaining these teeth after final restoration is to have the patient wear a maxillary night-guard while sleeping. This type of retainer will help to prevent further abrasion and also to maintain the vertical relationships of the anterior and posterior teeth.

Another important aspect of this patient's treatment was the opening of space for a suitable-sized pontic in the mandibular left posterior region. This movement was accomplished using a spring to push the adjacent teeth apart. The time necessary to create an additional 3 mm to 4 mm of pontic space depends on the size of the teeth being moved and also the amount of force being used. In our patient, it took about 6 months to open this space about 3 mm. So, the adjacent teeth probably moved about 0.5 mm each month. An advantage to opening this space unilaterally was that it allowed the midline to be corrected as the mandibular incisors were pushed toward the patient's right side.

This treatment plan required interdisciplinary collaboration between orthodontist, restorative dentist, and the patient. To determine what was possible orthodontically and whether or not that would be acceptable to the restorative dentist and patient, a diagnostic wax-up was constructed. This step is absolutely vital in the management of the interdisciplinary patient.¹² However, not many clinicians use wax-ups. This is a big mistake. The diagnostic wax-up is not only the vision of where the team is going, it is the vehicle that gives the patient a better idea of what the team will accomplish. Without a diagnostic wax-up in our case, it would have been difficult to achieve an ideal result. We

encourage teams to construct wax-ups for all restorative patients that are undergoing orthodontic therapy.

CONCLUSION

This case report has shown how orthodontics and restorative dentistry can accomplish treatment results that would not have been possible if either of these disciplines had been applied independently. Establishing anterior guidance, leveling gingival margins, restoring edentulous spaces, and establishing a balanced occlusion were only possible through the combined efforts of both disciplines. Through careful planning using diagnostic wax-ups, the various problems with this patient's teeth could be treated effectively, efficiently, and conservatively.

REFERENCES

1. Ogawa T, Koyano K, Suetsugu T. The influence of anterior guidance and condylar guidance on mandibular protrusive movement. *J Oral Rehabil.* 1997;24:303-309.
2. Buschang PH, Throckmorton GS, Travers KH, Hayasaki H. Incisor and mandibular condylar movements of young adult females during maximum protrusion and lateratrusion of the jaw. *Arch Oral Biol.* 2001;46:39-48.
3. Peck CC, Jurray GM, Johnson CV, Klineberg JJ. Trajectories of condylar points during nonworking side and protrusive movements of the mandible. *J Prosthet Dent.* 1999;82:322-331.
4. Lundeen HC, Shryock EF, Gibbs CH. An evaluation of mandibular border movements: Their character and significance. *J Prosthet Dent.* 1978;40:442-452.
5. Little RM, Riedel RA, Stein A. Mandibular arch length increase during the mixed dentition: postretention evaluation of stability and relapse. *Am J Orthod Dentofac Orthop.* 1990;97:393-404.
6. Artun, Krogstad O. Periodontal status of mandibular incisors following excessive proclination. A study in adults with surgically treated mandibular prognathism. *Am J Orthod Dentofac Orthop.* 1987;91:225-232.
7. Yared KF, Zenobio EG, Pacheco W. Periodontal status of mandibular central incisors after orthodontic proclination in adults. *Am J Orthod Dentofac Orthop.* 2006;130:631-638.
8. Lost C. Depth of alveolar bone dehiscences in relation to gingival recessions. *J Clin Periodontol.* 1984;11:583-589.
9. Kokich V. Anterior dental esthetics: An orthodontic perspective. I. Crown length. *J Esthet Dent.* 1993;5:19-23.
10. Kokich VG, Kokich VO, Spear F. Maximizing anterior esthetics: An interdisciplinary approach. In: *Frontiers in Dental and Facial Esthetics.* McNamara JA, Kelly, Jr K, eds. 2001; Needham Press, Ann Arbor, Michigan.
11. Reitan K. Clinical and histologic observations of tooth movement during and after orthodontic treatment. *Am J Orthod.* 1967;53:721-745.
12. Kokich VG, Kokich VO. Interrelationship of orthodontics with periodontics and restorative dentistry. In: *Biomechanics and Esthetic Strategies in Clinical Orthodontics.* Nanda R, ed. 2005; Elsevier Press, St. Louis, Missouri: 348-373.