

Chapter 24

IMPACTED TEETH: ORTHODONTIC AND SURGICAL CONSIDERATIONS

By Vincent G. Kokich and David P. Mathews

Most permanent teeth erupt into occlusion. In some individuals, however, the permanent teeth may fail to erupt and become impacted within the alveolus. When this lack of eruption occurs, two alternative treatment plans are possible. The impacted tooth could be extracted; the removal of the tooth, however, might require the placement of an implant or fixed prosthesis to replace the missing tooth. The other alternative is to uncover the tooth surgically and move it into the dental arch orthodontically. The timing of orthodontic treatment, type of surgical procedure to uncover the impacted tooth, orthodontic mechanics necessary, and potential problems with treatment vary, depending on which tooth has become impacted.

This chapter will discuss the orthodontic and surgical management of impacted teeth. In order to elucidate the differences in treatment techniques, this chapter will be subdivided based upon the specific tooth or teeth that commonly are impacted. In each subsection, the etiology, method of uncovering, timing of uncovering, preoperative and postoperative mechanics, and potential problems will be discussed.

SURGICAL TECHNIQUES

Four techniques can be employed to uncover impacted teeth. Subtle variations of each technique also are available for use in uncovering complex impactions. The type of impacted tooth and its location within the alveolus will dictate selecting the appropriate technique to uncover an impacted tooth.

Gingivectomy

A simple excision of gingiva can be accomplished with a sharp blade. This technique is indicated when there is a wide zone of attached gingiva, bone removal is not needed, and one-half to two-thirds of the crown can be exposed, leaving at least a 3 mm gingival collar. There are few instances where this technique can be used, unfortunately. The most common area where this technique may be employed is over the labially impacted maxillary canine and/or central incisor.

Apically Positioned Flap

A split thickness flap is reflected from the area adjacent to the impacted tooth. Appropriate bone removal is accomplished, and the flap is sutured apically, exposing about two-thirds of the crown. This technique most often is employed on "simple" labially impacted teeth.

Flap/Closed Eruption Technique

A crestal incision is made and buccal and/or lingual flaps are reflected. Appropriate bone removal is accomplished, and a bracket or chain is attached to the impacted tooth. The flaps are returned to their original location for complete closure. The chain passes under the flap, exits at the mid-crestal incision area, and is attached to the archwire. This technique is best used with high labially impacted teeth and teeth that are impacted in the mid-alveolar area. With appropriate orthodontic mechanics, the tooth can be erupted, mimicking its natural eruptive path through the mid-crestal area.

Pre-Orthodontic Uncovering Technique

This technique is used on "simple" palatally impacted canines. A full thickness palatal flap is reflected from the premolar to the midline, and appropriate bone removal is accomplished. The flap is repositioned, and the area over the impacted canine is scalloped so the tooth remains uncovered. The canine will erupt on its own, and this eruption will facilitate final orthodontic positioning. This technique is used before placement of orthodontic appliances or during the initial stage of orthodontic treatment.

MAXILLARY CENTRAL INCISORS

Etiology

The most commonly impacted tooth is the maxillary canine,¹ followed by the maxillary central incisor. The usual cause of impaction of the maxillary central incisor is the presence of a supernumerary tooth or mesiodens.² If the supernumerary tooth is discovered early and extracted, the central incisor may erupt spontaneously. If the root of the impacted incisor forms completely and the mesiodens has not been removed, however, then the central incisor may not erupt spontaneously.

When the central incisor is impacted, it usually is located in the middle of the alveolus faciolingually. In most situations, the tooth is oriented vertically with the incisal edge directed toward the dental arch. In some patients, however, the tooth bud of the central incisor becomes rotated and diverted, and the impacted tooth may be oriented in a horizontal direction parallel to the occlusal plane. Obviously, these complex impactions are much more difficult to treat.

Preoperative Orthodontics

Usually an impacted central incisor is recognized during the mixed dentition. At that time, all maxillary and mandibular central and lateral incisors are erupted, except for the impacted central incisor. The first step is to extract any supernumerary teeth as a separate procedure. In some patients, the impacted central incisor may erupt. If not, orthodontic treatment must be initiated to erupt the tooth. Brackets should be placed on the remaining central incisor and the two maxillary lateral incisors. This bracket placement typically provides sufficient anchorage to erupt the impacted tooth. If the contralateral central and adjacent lateral incisors have tipped toward one another, the space is opened using a coiled spring. Bands are cemented to the maxillary permanent first molars to help provide anchorage during the course of orthodontic treatment. After sufficient space has been established, a rectangular stabilizing wire is placed in the maxillary brackets. A loop may be

placed in the arch wire to temporarily anchor the attachment that will be placed on the impacted central incisor during the uncovering procedure. At this point, the patient is referred to the surgeon to uncover the impacted central incisor.

Surgery

Impacted central incisors can be classified either as "simple" where the tip of the impacted tooth is near the adjacent cemento-enamel junctions (CEJ) (Fig. 24-1A), or "complex" where the impacted tooth is positioned high in the vestibule (Fig. 24-1B). Central incisors usually are impacted labially.

Simple

The simple labially impacted tooth can be uncovered with either the apically positioned flap or the flap/closed eruption technique. In the example shown in Fig. 24-2, the closed eruption technique is used. A crestal incision is made and joined with vertical incisions, and a pedicle flap is reflected from the edentulous ridge. Approximately two-thirds of the crown is exposed with appropriate bone removal by means of curettes and surgical round burs. The area is isolated with hemostatic agents such as SurgicelTM or HemodentTM. The tooth is etched and a bonding agent is placed. At this point, either a small button can be placed on the labial of the tooth with a gold chain or wire ligated to the button, or a gold chain can be bonded directly to the labial aspect of the tooth. The pedicle flap is returned to its original position and sutured. The chain is covered by the flap and exits at the mid-crestal incision. The chain can be ligated to the bracket on the adjacent tooth, and the orthodontist may begin erupting the tooth within one to two weeks.

Complex

If the tooth is impacted high in the vestibule on the labial aspect, then the closed eruption technique is the treatment of choice. In the example shown in Figure 24-3, the tooth is impacted high in the vestibule near the base of the nasal spine; it also is positioned horizontally. The use of an apically positioned flap in this situation is injudicious. First, appropriate bone removal is accomplished. In this situation, the lingual aspect of the tooth is the only visible area. A bracket is bonded to the tooth, a wire or chain is attached, and the flap is returned to its original position. With appropriate orthodontic mechanics, this tooth can follow its normal eruptive pattern through the crest of the edentulous ridge, leaving adequate attached gingiva and a gingival margin that is esthetically harmonious with the adjacent central incisor.

In a third example (Fig. 24-4), an apically positioned

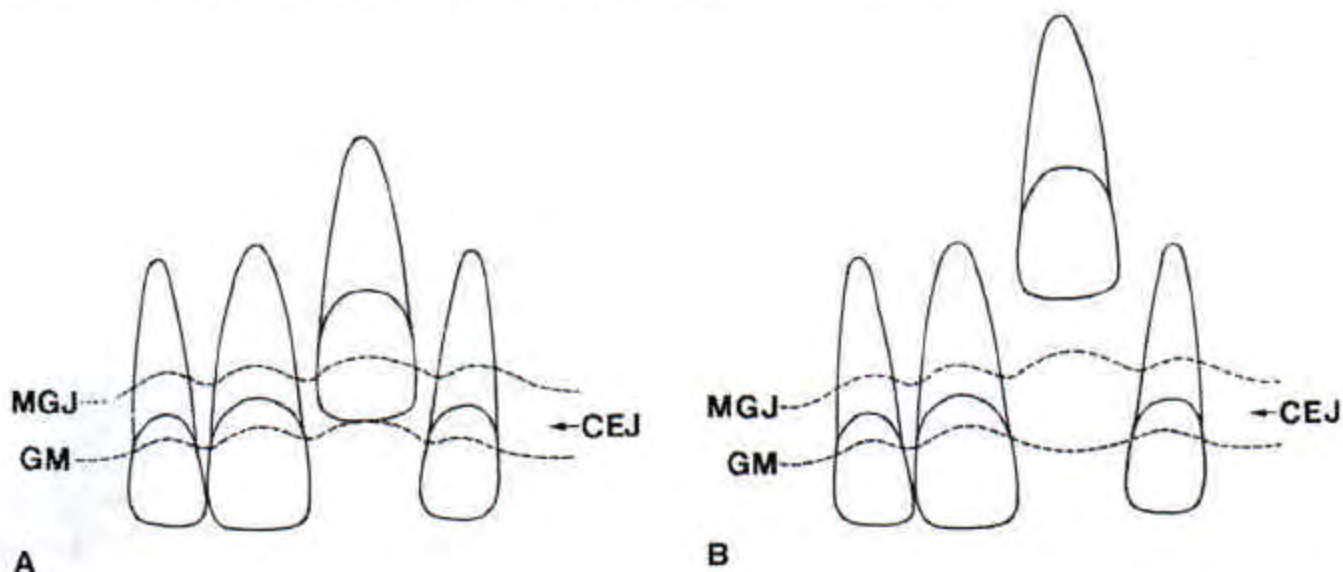


Figure 24-1. Diagrams indicating different positions for impacted maxillary central incisors. *A*. If the incisal edge of the maxillary central incisor is positioned coronal (incisal) to the mucogingival junction, an apically positioned flap, flap/closed eruption technique, or a gingivectomy procedure can be used to uncover the impacted central incisor crown. If the patient has insufficient attached gingiva, an apically positioned flap is chosen. If sufficient gingiva is present, a gingivectomy uncovering may be appropriate. *B*. If the incisal edge is positioned apical to the CEJ, a flap/closed eruption technique should be employed. With the latter technique, the tooth may be erupted through the crest of the ridge, and sufficient gingiva will be present over the labial of the central incisor.

flap was performed on this high labial impaction. This case points out the difficulty of using this technique to apically position tissue on a high labially impacted tooth. The tooth has been moved into its proper location, but as can be seen, the gingival margin is more apical than the adjacent central incisor. This example illustrates one reason why the flap/closed eruption technique is used to uncover most labially impacted teeth, except for the ectopic labially impacted tooth.

Postoperative Orthodontics

During the postoperative orthodontic treatment phase, the key to success is the eruption of the maxillary central incisor into the center of the alveolar ridge. In order to accomplish this maneuver, the orthodontic force must originate from the center of the edentulous alveolar ridge. If the clinician directs the force labially toward the archwire, the impacted tooth may erupt into the oral cavity in a more apical position. This movement may cause apical positioning of the gingival margin over the erupted central incisor, creating a difference in the crown lengths between the impacted and non-impacted central incisors and compromising the esthetic appearance of the teeth. In order to erupt the tooth into the center of the ridge, a Ballista loop (Fig. 24-5) is helpful. This loop can be activated, and its force is directed from the center of the ridge in a vertical direction. The use of this type of loop will help pull the tooth into its normal path of eruption and not toward the labial. After the

tooth has erupted, a bracket is bonded to the labial surface, and the crown and root of the tooth are positioned properly.

MAXILLARY CANINE—LABIAL IMPACTION

Etiology

Labial impaction of the maxillary canine over the maxillary lateral incisor (Fig. 24-6) occurs occasionally. This type of impaction is due to one of two causes. Either the canine moves ectopically over the labial surface of the maxillary lateral incisor root and fails to erupt, or the maxillary dental midline may shift toward the canine, causing it to be impacted labially. In some instances, the canine will erupt spontaneously and then can be moved orthodontically into the dental arch. In other patients, however, the tooth will not erupt and must be uncovered surgically and subsequently erupted into position orthodontically.

Preoperative Orthodontics

When the maxillary canine is labial to the maxillary lateral incisor, the root of the lateral incisor is oriented toward the palate. If brackets are placed on all maxillary teeth, including the lateral incisor, the root of the lateral may be forced toward the labial. If the canine crown is

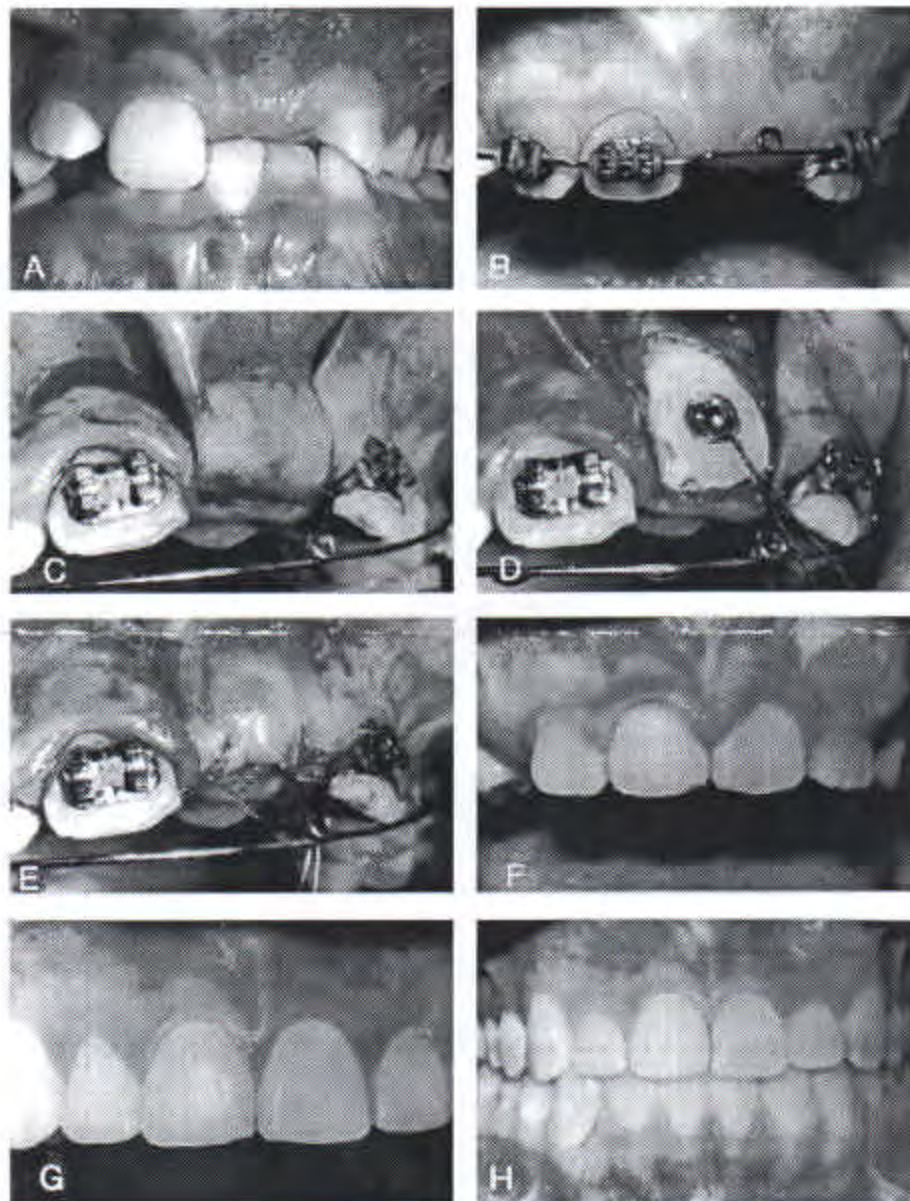


Figure 24-2 A labially impacted maxillary central incisor. A. The maxillary central incisor was impacted and had not erupted at age 10. B. Orthodontic treatment was initiated to create sufficient space between the maxillary right central and left lateral incisors. C. A pedicle flap was reflected from the crest of the ridge. D. A button was bonded onto the tooth, and a piece of ligature wire was attached. E. The flap was repositioned and sutured, and elastomeric chains were used to erupt the tooth. F. At the completion of this phase of orthodontic treatment, the gingival margins of both central incisors were identical, in that the left central was erupted through the crest of the ridge. G. At the end of the second phase of orthodontic treatment, the gingival margins of the two central incisors remained identical. H. Three years after orthodontic treatment, the positions of the central incisors and the gingival margins were at the same level.

occupying this space, root resorption could occur on the labial surface of the lateral incisor. Therefore, in this situation, it is best not to bracket the maxillary lateral incisor initially. Bands and brackets are placed on the remaining teeth in the maxillary arch, and a coil spring usually is needed to move the first premolar and central incisor apart. The archwire bypasses the lateral incisor and does not attach to the lateral until after the canine has been uncovered and moved distally. After the re-

maining maxillary teeth have been positioned properly, the patient should be referred to the surgeon to uncover the maxillary canine.

Surgery

If the labially impacted tooth is located lateral to the edentulous area, *i.e.*, an ectopic labial impaction (Fig. 24-6DE), an apically positioned flap is the appropriate

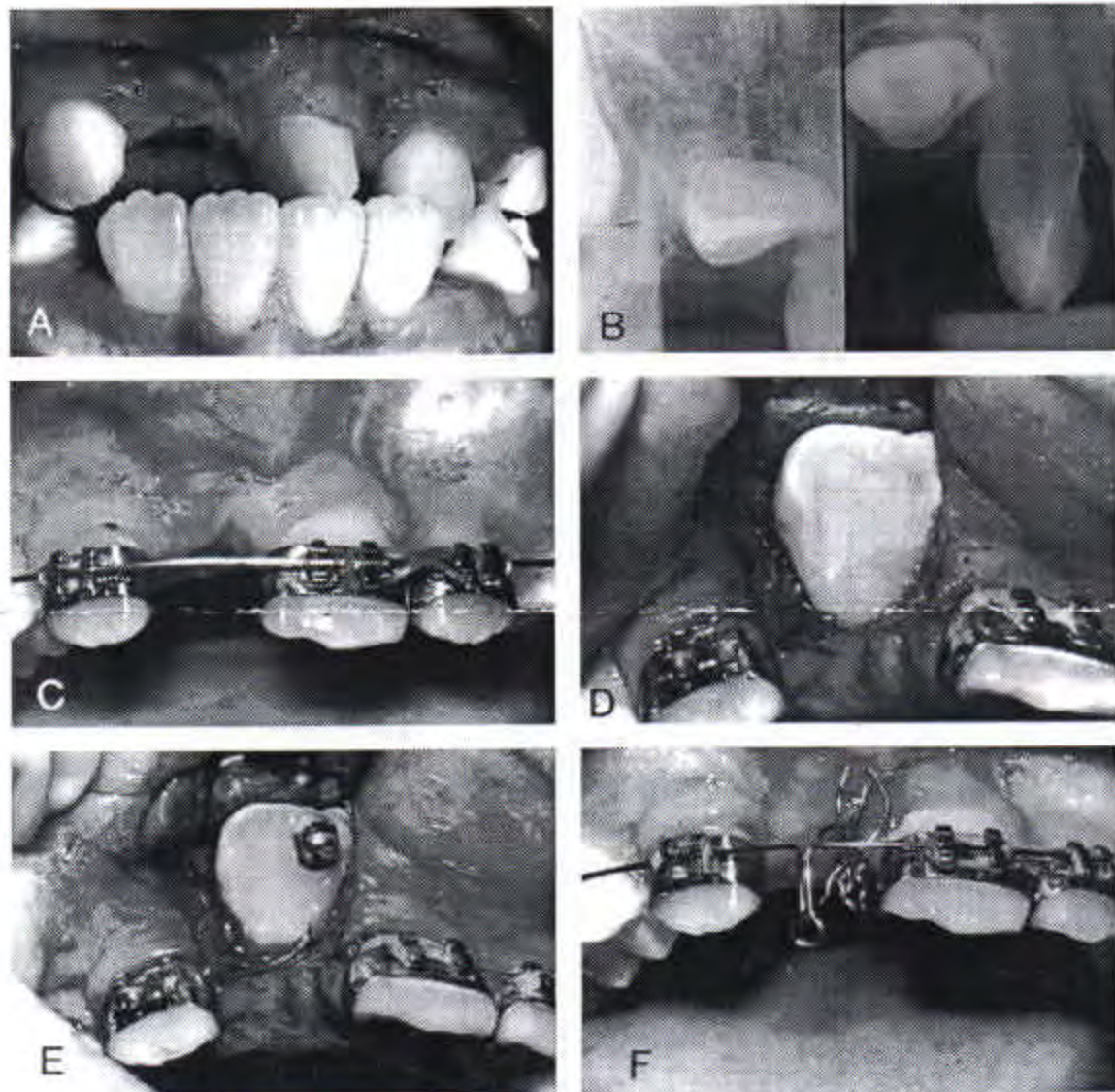


Figure 24-3. Horizontally impacted maxillary central incisor. *A*. The upper right central incisor was unerupted, and the upper left central incisor was rotated and in lingual crossbite. *B*. Pretreatment radiographs indicate the horizontal impaction of the maxillary right central incisor. *C*. Initially, brackets were placed on the teeth, and the teeth were aligned. *D*. A pedicle flap was reflected, and the tooth was uncovered. *E*. A button was bonded to the lingual surface of the central incisor, and the flap was repositioned in its original location. *F-H*. A Ballista loop was used to deliver an eruptive force to the impacted central incisor. *I*. After the tooth had been erupted, a bracket was placed on the tooth, and it was aligned in its proper axial inclination. *J*. After orthodontic treatment, the gingival margins of the maxillary central incisors were nearly at the same level. In addition, the same amount of gingiva was present over both central incisors.

technique. It is rare that there is enough attached gingiva to allow use of the gingivectomy technique and still obtain an adequate collar of attached tissue. Use of the closed eruption technique would not be appropriate, because it would not allow the orthodontist to use the appropriate mechanics to move the tooth over the lateral incisor and into the edentulous area.

Ideally, to use the apically positioned flap on this type of impaction, there should be a minimum of 4 to 6 mm of gingiva on the adjacent central and lateral incisor. In this instance (Fig. 24-6), the donor tissue for the pedicle

flap can be reflected from the central and lateral incisor by way of a split-thickness pedicle flap. Bone is removed from the crown of the impacted tooth, exposing approximately two-thirds of the enamel. The flap is sutured with resorbable gut suture to the periosteum, exposing approximately two-thirds of the tooth. It is important when using this technique to leave a 2 to 3 mm gingival collar around the incisor donor site (Fig. 24-6*D*). In addition, at least a 2 mm width of gingiva should be incorporated with the pedicle flap. This technique must be planned and employed carefully. The impacted

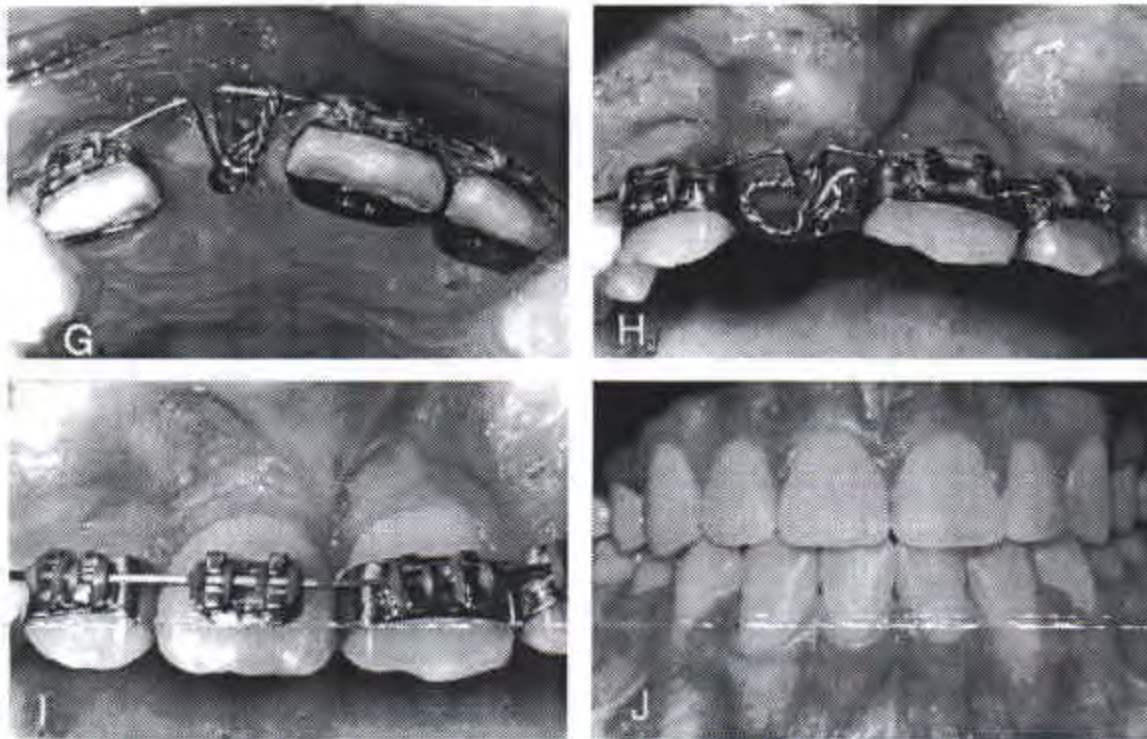


Figure 24-3. (Continued)

tooth often is lying over the root of the incisor, and a significant bony dehiscence may be present.

If there is not adequate gingiva over the incisor donor site, then the edentulous area will need to be used.³ Introduction of an incision into the edentulous area complicates the flap design because of the distance from the edentulous ridge crest to the impacted tooth. The incisions must be planned very carefully to allow adequate exposure of the impacted tooth and to leave adequate gingiva over the central and lateral incisors.

Postoperative Orthodontics

After the labially impacted maxillary canine has been uncovered, the tooth must be moved into the dental arch. If sufficient space exists for the tooth, and the canine is positioned immediately above the edentulous space, a flexible nickel-titanium wire may be used to facilitate tooth eruption. If the canine is positioned mesially and has erupted labial to the lateral incisor, an elastomeric chain should be attached from the maxillary canine to the premolars and maxillary first molar on that side (Fig 24-6F). It is helpful to attach the chain as far distally as possible to enhance the anchorage. In some patients, it may be beneficial to place a maxillary Nance holding arch or a transpalatal arch to increase the amount of molar anchorage. Gradually, the maxillary canine is moved distally (Fig. 24-6G). It is important not to place a bracket on the lateral incisor during this movement in order to avoid root resorption of the

lateral incisor. After the canine has been moved far enough distally, the lateral incisor can be bracketed, and space can be created for the canine by pushing the lateral incisor toward the mesial. After that movement has been accomplished, the maxillary canine may be erupted vertically into its position in the dental arch. At that point, a rectangular archwire is helpful to complete the correction of tooth positioning and root angulation. During orthodontic finishing, the clinician also must move the root of the maxillary lateral incisor toward the labial to improve the axial inclination of the crown.

MAXILLARY CANINE— INTRA-ALVEOLAR IMPACTION

Etiology

Intra-alveolar impaction of the maxillary canine (Fig. 24-7) is more common than labial impaction; however, neither is more common than palatal impaction of the maxillary canine.³ Intra-alveolar maxillary canine impactions usually are due to the presence of a supernumerary tooth in the path of eruption of the maxillary canine. Even when the supernumerary tooth is removed, the canine may fail to erupt. The tooth may be located within the center of the alveolar ridge, but the root forms completely, and the tooth becomes stalled and impacted in the alveolus.

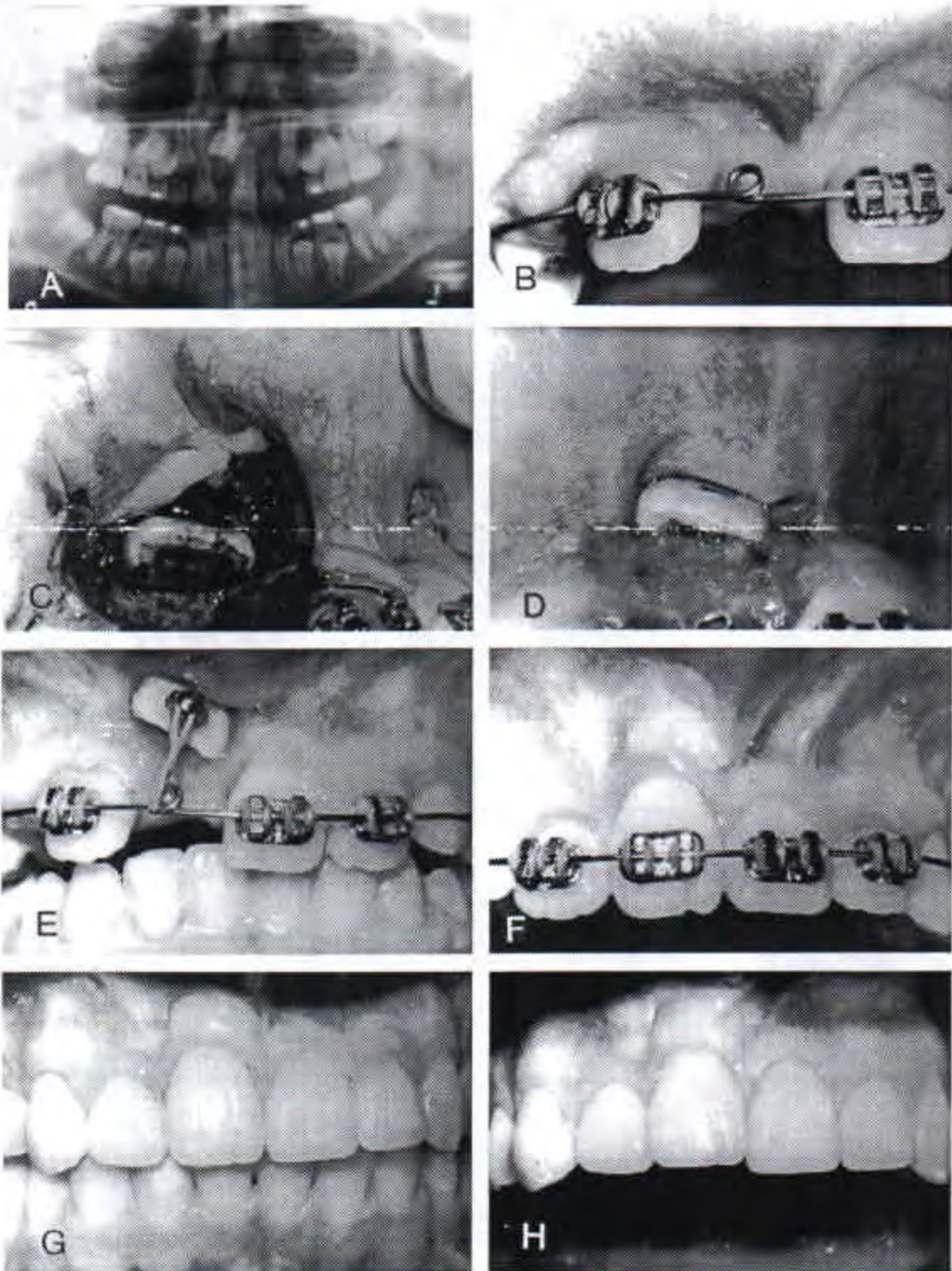


Figure 24-4. Horizontally impacted maxillary central incisor. *A*. The pretreatment radiograph shows the position of the impacted maxillary right central incisor. *B*. Brackets were placed on the adjacent teeth, and sufficient space was created for the right central incisor. *C*. An apically positioned flap was elevated. *D*. The flap was positioned near the CEJ of the impacted central incisor. *E*. An elastomeric chain was used to erupt the right central incisor, and brackets eventually were placed to position the crown and root of the formerly impacted tooth (*F*). *G*. After the completion of orthodontic treatment, the gingival margin of the right central incisor was more apical than the left central incisor. In addition, the gingiva is thicker over the formerly impacted tooth. *H*. Five years after treatment, the maxillary right central incisor had reintruded. This rebound probably was due to the pull of the mucosa, in that the apically positioned gingival flap had healed to the mucosa, well above the mucogingival junction of the adjacent teeth.

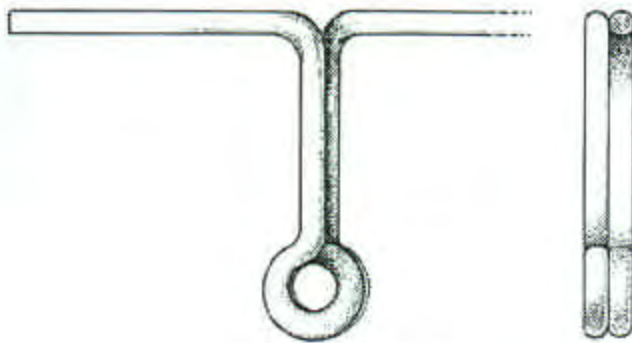

Figure 24-5. Diagrammatic representation of the Ballista loop, which is formed from .018" stainless steel wire.

Preoperative Orthodontics

In this situation, the orthodontist should wait until all permanent teeth have erupted before beginning treatment. At that time, bands and brackets should be placed on all of the maxillary teeth. The dental arch should be aligned, and space must be created for the maxillary canine. After the proper amount of space has been apportioned, a rectangular archwire is placed in the maxillary arch, and the patient is referred to the surgeon to uncover the impacted tooth.

Surgery

When the tip of the labially impacted tooth is coronal to the adjacent CEJs, and there is a wide zone of attached gingiva, it may be possible to use the gingivectomy technique⁵ (Fig. 24-7). In this patient, a simple gingivectomy was possible; two-thirds of the crown of the tooth was exposed, and no bone removal was necessary. There still is adequate remaining attached tissue. A dressing can be placed over the enamel to prevent tissue overgrowth. In one week, the dressing may be removed, and the patient is instructed to keep the exposed crown clean with a toothbrush or cotton swab using a chlorhexidine rinse on the swab to prevent gingival proliferation. In three to four weeks, the tissue will be healed sufficiently to allow the orthodontist to place a bracket and begin tooth movement. If this technique is used properly, there should be adequate attached gingiva and no recession, when the orthodontic treatment is completed (Fig. 24-7D).

If the tip of the labially impacted canine is near the adjacent CEJs, or slightly apical, then the apically positioned flap or closed eruption technique can be used. In this location, it would be impossible to perform an excisional gingivectomy and leave adequate attached gingiva. In the example shown in Figure 24-8, a split-thickness pedicle flap is reflected from the crest of the edentulous area, preserving as much gingiva as possible. The incisions are extended vertically into the vestibule,

and the split-thickness flap is reflected (Fig. 24-8C). Occasionally a thin shell of bone covers the enamel, and this covering can be removed with a curette or surgical round bur. Two-thirds of the crown is exposed, and the connective tissue follicle is curetted from the periphery of the exposed portion of the crown. The flap is sutured to the periosteum with resorbable suture, exposing approximately two-thirds of the enamel. A small dressing can be placed over the enamel. If the patient employs good home care including the use of a chlorhexidine rinse, tissue overgrowth rarely is a problem. The orthodontist can place a bracket and initiate orthodontic therapy in four to six weeks after the uncovering procedure (Fig. 24-8E). If the tooth is impacted high in the vestibule or within the alveolus, then the closed eruption technique is the treatment of choice (Fig. 24-8D).

Before any surgery is initiated, it is important to determine the location of the impacted tooth. In the case of a labial impaction, locating the tooth often can be accomplished by palpation. If the tooth is positioned in the middle of the alveolus or palatally, however, it will be necessary to determine its location by taking two radiographs at different angles. Use of the Buccal Object Rule⁶ is helpful in determining the location of these impacted teeth. When two different radiographs are made of a pair of objects, the image of the buccal object moves, relative to the image of the lingual object, in the same direction that the X-ray beam is directed (see Figure 24-9B). In this instance (Fig. 24-9), it was determined that the tooth was impacted in the mid-alveolar area.⁷⁻¹⁰ The flap/closed eruption technique is the treatment of choice in this situation. A crestal incision can be made, and vertical incisions can help release the flap on the labial aspect. Sulcular incisions can be made on the palatal aspect of adjacent teeth for better reflection. Curettes and surgical round burs are used to find the tip of the impacted tooth. Bone must be removed from the incisal aspect of the tooth to allow placement of a bracket and/or chain. The amount of bone removed must be sufficient to allow the widest part of the crown to pass through the bone unobstructed. The flaps are returned to their original location for complete closure with resorbable suture. The chain passes under the flap and exits at the mid-crestal incision area, where it is attached to the archwire or adjacent bracket. The orthodontist can activate force within one week. If proper mechanics are used, the tooth will erupt, as it would have naturally.

Postoperative Orthodontics

If the crown of the canine has been uncovered completely by means of excising the gingiva or apically positioning a flap, an orthodontic attachment may be bonded to the labial surface of the tooth. It is advantageous to place an orthodontic bracket. In some situations, however, a smaller attachment may be required if

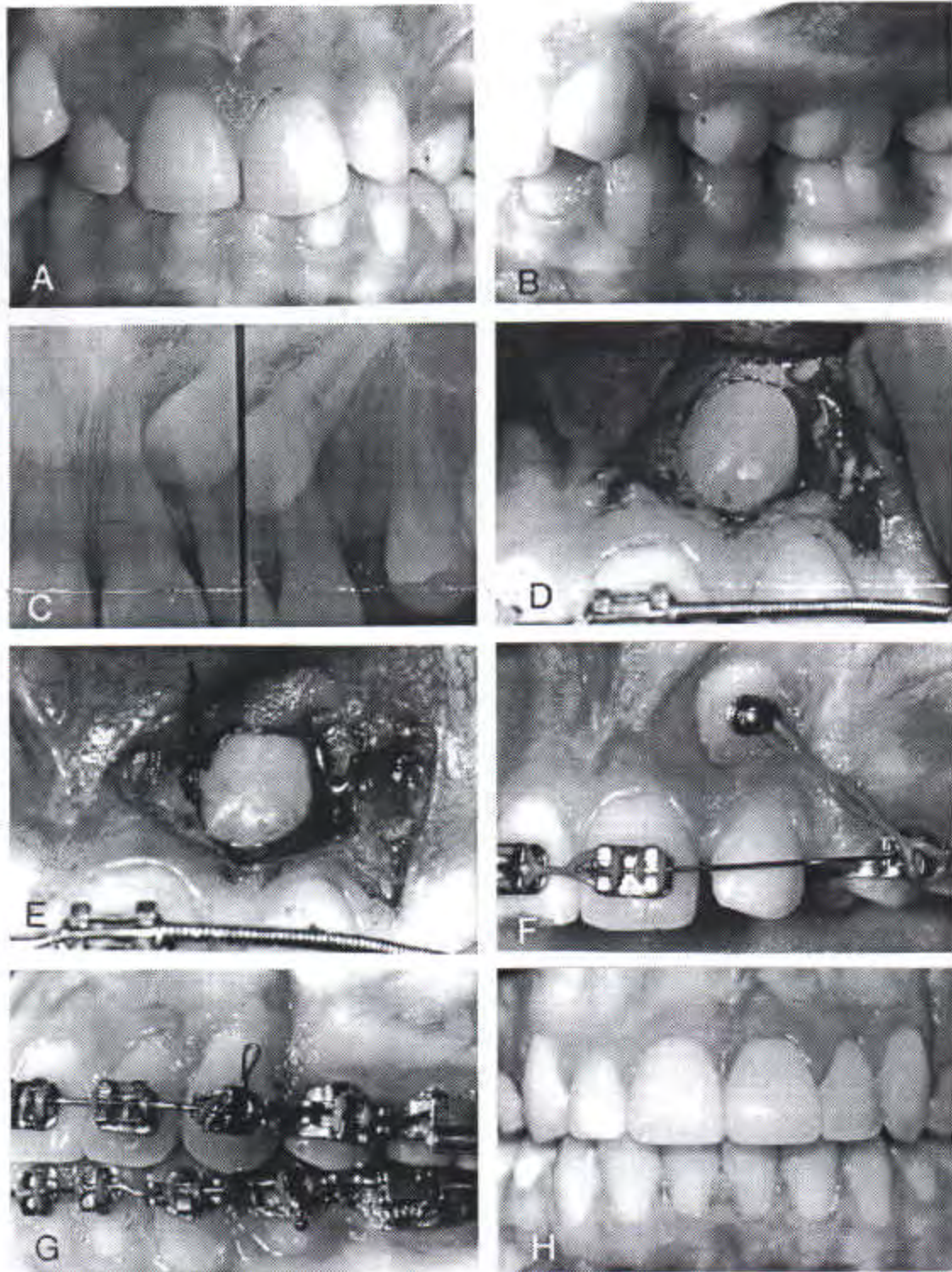


Figure 24-6. A 13-year-old patient with a maxillary left canine that is impacted mesial and labial to the left lateral incisor. *A, B.* Pretreatment intraoral photographs show that the maxillary left lateral incisor was proclined labially. The canine was impacted mesial to the root of the lateral incisor. Four premolars had been extracted previously, and the spaces were closed. *C.* Periapical radiographs indicate the location of the labially impacted canine. *D.* The adjacent incisors had adequate gingiva as a donor site for a split-thickness pedicle flap. Care was taken to leave a gingival collar over the central and lateral incisors. *E.* The flap was positioned apically and sutured to the periosteum, exposing two-thirds of the anatomic crown. *F.* An orthodontic attachment was placed on the canine, and the posterior teeth were used as anchorage to retract the canine distally. The lateral incisor was not bracketed to avoid moving the root of the lateral incisor into the crown of the canine and potential root resorption. *G.* After the canine was moved far enough distally, the lateral incisor was bracketed, and the proper occlusion and axial inclination of the teeth were established. *H.* At the end of orthodontic treatment, the maxillary left canine was well-positioned with sufficient attached gingiva. In addition, the gingival margin was only slightly higher than the contralateral canine that had erupted normally.

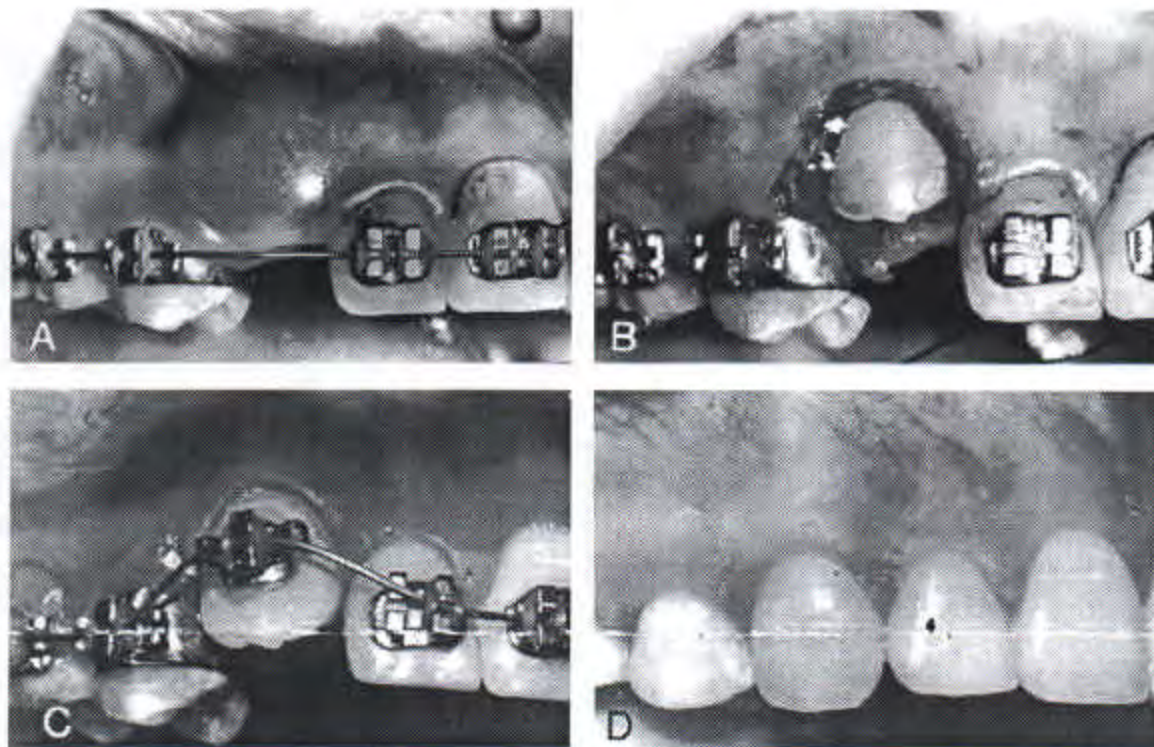


Figure 24-7. Intra-alveolar impacted maxillary canine. *A*. Initially, space was opened orthodontically to accommodate the canine into the dental arch. The gingiva had been stained with Schiller's solution. This solution temporarily stains the mucosa a dark brown, clearly delineating the mucogingival junction. The canine could be palpated, and a wide zone of attached gingiva was present. *B*. A gingivectomy was possible because of the wide zone of gingiva and location of the tooth. About two-thirds of the crown was exposed. *C*. An orthodontic bracket was placed, and a flexible wire was used to erupt the canine. *D*. Finished intraoral views show an adequate zone of attached gingiva over the erupted canine.

an insufficient area of enamel is available. After the bracket has been positioned, the objective of the orthodontic eruption process is to avoid distortion of the maxillary occlusal plane. In addition, the tooth must be erupted gradually to avoid potential recession of the gingiva. Flexible nickel titanium wires are advantageous for the eruption process. These wires will not distort permanently and will permit gradual eruption of the impacted tooth.

If the crown of the tooth is apical to the mucogingival junction, and a closed eruption procedure has been performed, a wire or chain will be extending through the gingiva at the crest of the alveolar ridge. The wire or chain will be connected to an attachment that has been bonded to the tooth. In this situation, the orthodontic objective is to erupt the tooth through the crest of the alveolar ridge. This movement will duplicate the normal eruption process. A Ballista spring or loop may be used to direct the eruption toward the crest of the ridge. This type of eruption system is easy to adjust as the tooth begins to erupt. As that process occurs, segments of the wire or chain are removed until the crown of the tooth protrudes through the gingiva. At that point, a bracket may be placed on the tooth and the final positioning completed. After eruption of a labially impacted tooth,

the root and crown of the tooth may require changes in axial inclination to position the tooth in its proper position. This movement usually is accomplished best with a rectangular wire.

MAXILLARY CANINE— SIMPLE PALATAL IMPACTION

Etiology

The cause of palatal impaction of the canine is unknown. For some reason during tooth development, the direction of eruption of the canine becomes diverted toward the palate. Once this redirection of eruption occurs, although the tooth may erupt, it usually will be positioned in crossbite.

Palatal impactions can be divided into two categories depending on the severity of the impaction. A *simple* palatal impaction is defined as a tooth that is diverted toward the palate, not deeply imbedded within the alveolus, and with the canine cusp tip located near the cemento-enamel junctions of the adjacent teeth (Fig. 24-10). A *complex* palatal impaction describes a canine that usually is oriented horizontally relative to the oc-

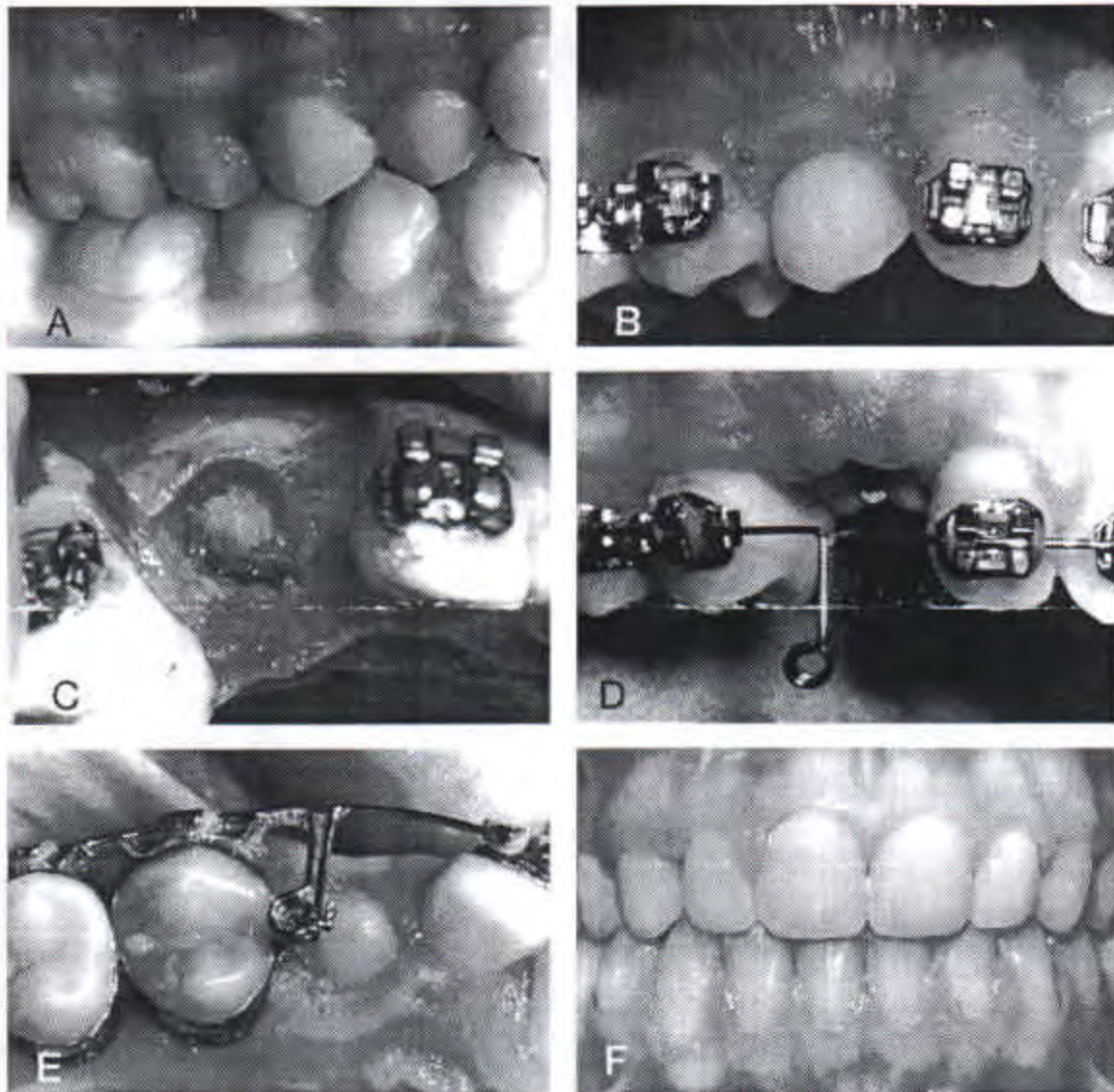


Figure 24-8. An adolescent patient with bilateral labially impacted maxillary canines. *A*, The pretreatment intraoral photograph shows that the maxillary primary canines still are present. *B*, Orthodontic treatment was initiated to make sufficient space for the permanent canines. *C*, A pedicle flap was reflected on the labial along with a small palatal flap to expose the tip of the canine. Sufficient bone was removed so that the crown was visible, and an attachment was placed on the crown. *D*, The flaps were reapproximated and sutured. This flap/closed eruption technique created sufficient gingiva labial to the tooth. *E*, A Ballista spring was used to erupt the tooth into position. *F*, At the end of orthodontic treatment, both canines were positioned properly, and the gingival margins were nearly identical with one another. Sufficient attached gingiva was present over the labial surfaces of the canines.

clusal plane, with the canine cusp tip located near the middle to apical portions of the adjacent teeth (Fig. 24-11). The strategy for erupting these teeth and treating them orthodontically is different.

Preoperative Orthodontics

The timing of uncovering palatally impacted canines depends on the position of the tooth. If the impacted canine is not located high in the palate, but rather is positioned near the alveolar ridge (*simple*), it may be advantageous to uncover the tooth prior to beginning orthodontic ap-

pliance placement. If the orientation of the crown and root are similar to the adjacent teeth, and the canine has been uncovered early, it usually will erupt partially into the palate. This pattern of eruption is advantageous, because the tooth can be moved laterally without dragging the crown through the palatal gingiva. If the canine is impacted near the roof of the palate (*complex*), early uncovering of the tooth may not be advisable. In this instance, the soft tissue probably will migrate over the crown, requiring a second surgical procedure.

In some patients, the primary canine still is present. It generally is advantageous to remove the primary canine

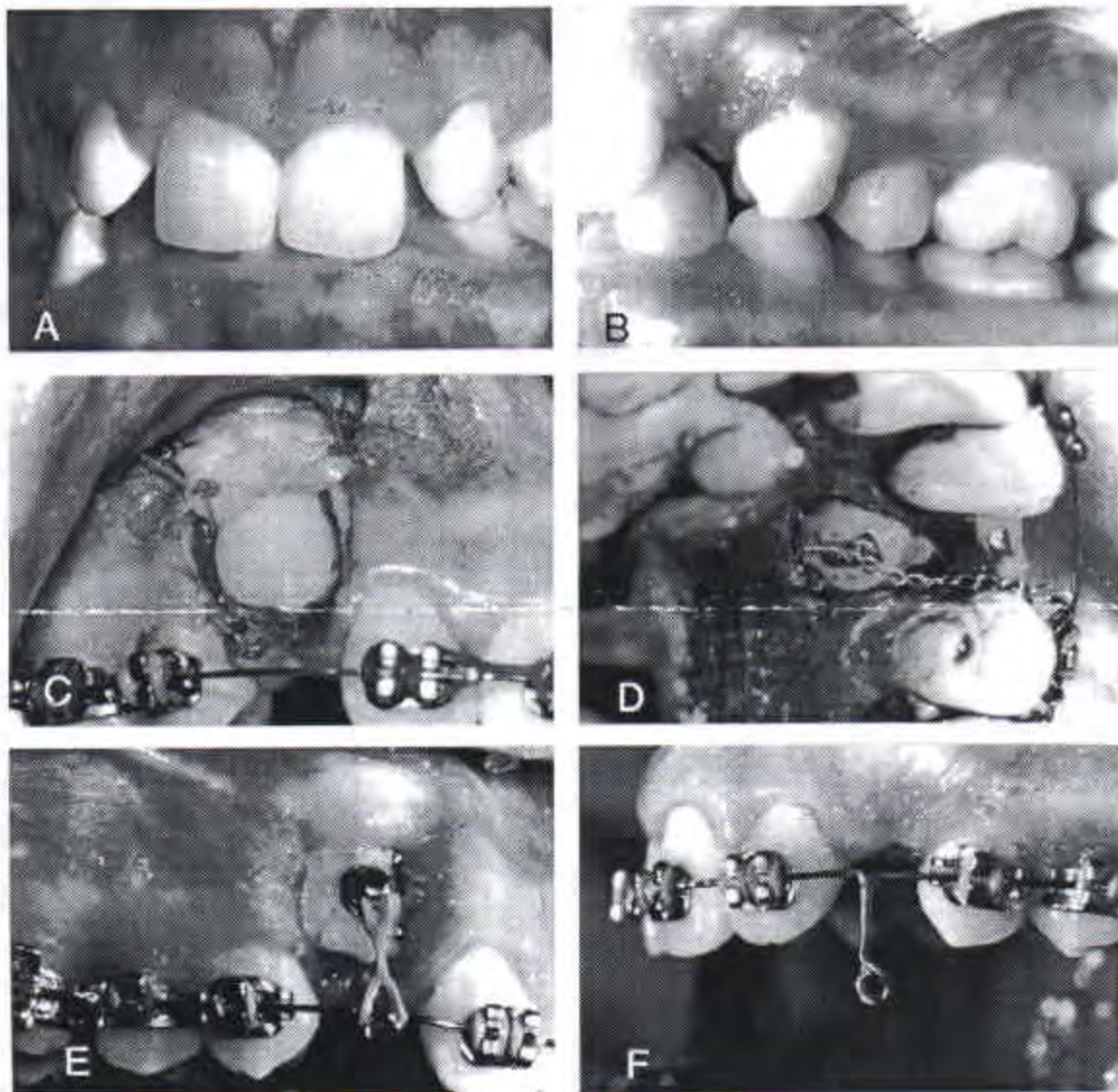


Figure 24-9. A patient with bilaterally impacted maxillary canines. *A, B.* The pretreatment intraoral photographs show that the patient had a Class II malocclusion with deep anterior overbite. The maxillary right canine was impacted labially, and the left canine was impacted within the alveolus and slightly to the palate. Two different types of uncovering procedure were used for this patient. *C.* Because the cusp tip of the right canine was positioned coronally relative to the mucogingival junction, and there was inadequate gingiva to perform gingivectomy, an apically positioned flap procedure was used to uncover the right canine. *D.* Because the left canine was impacted within the alveolus, a flap/closed eruption procedure was used. *E.* An elastomeric chain was used to erupt the right canine. *F.* A Ballista loop was used to erupt the left impacted canine.

when the permanent canine is uncovered. In that way, only one surgical procedure will be necessary.

During the preoperative orthodontic phase of treatment, sufficient space must be created for the permanent canine. Most maxillary canines are about 7.5 to 8.0 mm in width. Of course, the clinician can use the contralateral canine as a guide. If both canines are impacted, a radiographic assessment of the width of the tooth must be made. If the radiograph is distorted, the width of the permanent canine can be estimated from the relative size of the erupted first premolar. Permanent canines generally are about 1.0 to 1.5 mm wider

than the first premolars. After sufficient interproximal space has been established, the patient is ready for surgical uncovering of the impacted canine.

Surgery

Two different techniques can be employed to uncover the palatally impacted tooth: Most palatal impactions are like those in Figure 24-10. These are *simple* impactions and are positioned palatal to the central and lateral incisors and not too deeply embedded within the alveolus. The *complex* situation shown in Figure 24-11 is

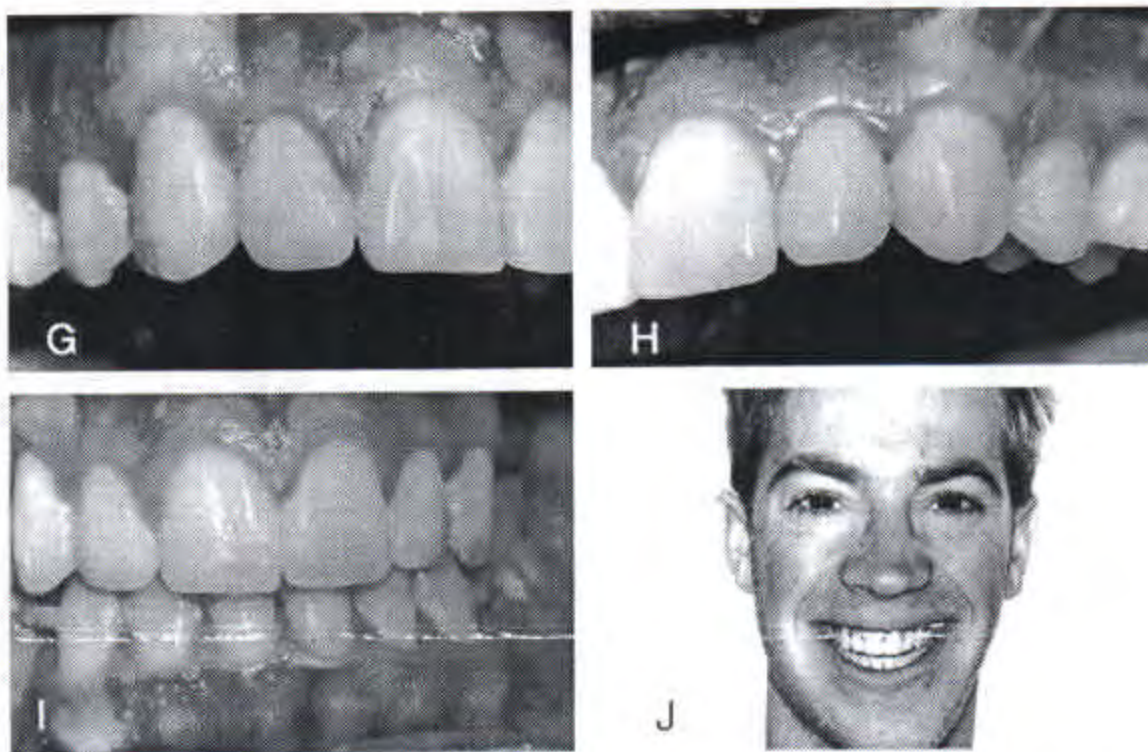


Figure 24-9 (Continued) *G-J*. After orthodontic treatment, the intraoral photographs show the comparison of the gingival margins and amount of gingiva around both canines. The maxillary right canine has more gingiva, because an apically positioned flap procedure was used; however, the left canine also has sufficient gingiva. The front intraoral photograph after treatment (*I*) shows the difference in the level of the gingival margins of the left and right canines. With the apically positioned flap, the gingival margin generally ends up more apical than the flap/closed eruption side. If the patient has a high lip line (*J*), then the discrepancy between the gingival margins of the right and left canines could be an esthetic compromise. In this patient, the difference in the levels of the gingival margins was not a problem.

positioned more horizontally and more deeply impacted within the alveolus, sometimes near the apices of the central and lateral incisor or even apical to them.

Preorthodontic Uncovering Technique

Simple palatal impactions (Fig. 24-10) can be treated by an early uncovering technique before placement of orthodontic appliances. When these teeth are uncovered early and left uncovered, they will erupt to a more favorable location that will facilitate orthodontic movement.

The technique requires flap reflection and complete bone removal from the coronal aspect of the tooth. If the primary canines are present, they are extracted at the time of the uncovering procedure. A full-thickness palatal flap is reflected from the premolar up to the midline (Fig. 24-10C). A curette or surgical round bur is used to locate the impacted tooth by gently removing the encasing bone. The follicle is curetted from the periphery. Before flap closure, the area of the flap over the impacted tooth is scalloped, so that it leaves the tooth uncovered after the flap is sutured (Fig. 24-10D). A dressing is placed over the enamel of the tooth and contoured flush with the surface of the palatal flap. A stent

(Biostar(or Omnivac(; see Chapter 27 for the fabrication of invisible retainers) can be made to cover the palate and the dressing to ensure that it will stay in place. This stent also minimizes postoperative discomfort and postoperative bleeding.

The dressing is removed in 7 to 10 days, and the patient is instructed in swabbing the area with a chlorhexidine rinse. On teeth that are embedded more deeply, the area may require slight degranulating with a curette at this appointment and replacement of the dressing for another week. The margins around the impacted tooth will be epithelialized in four to six weeks. The tooth will begin to erupt on its own and can remain unbracketed until the appropriate time determined by the orthodontist.

MAXILLARY CANINE—COMPLEX PALATAL IMPACTION

In this type of patient (Fig. 24-11), a different technique is used. These teeth usually are impacted high within the alveolus. They will not erupt on their own if left uncovered, because the tissue will grow over the tooth. A full-thickness palatal flap is reflected from the molar

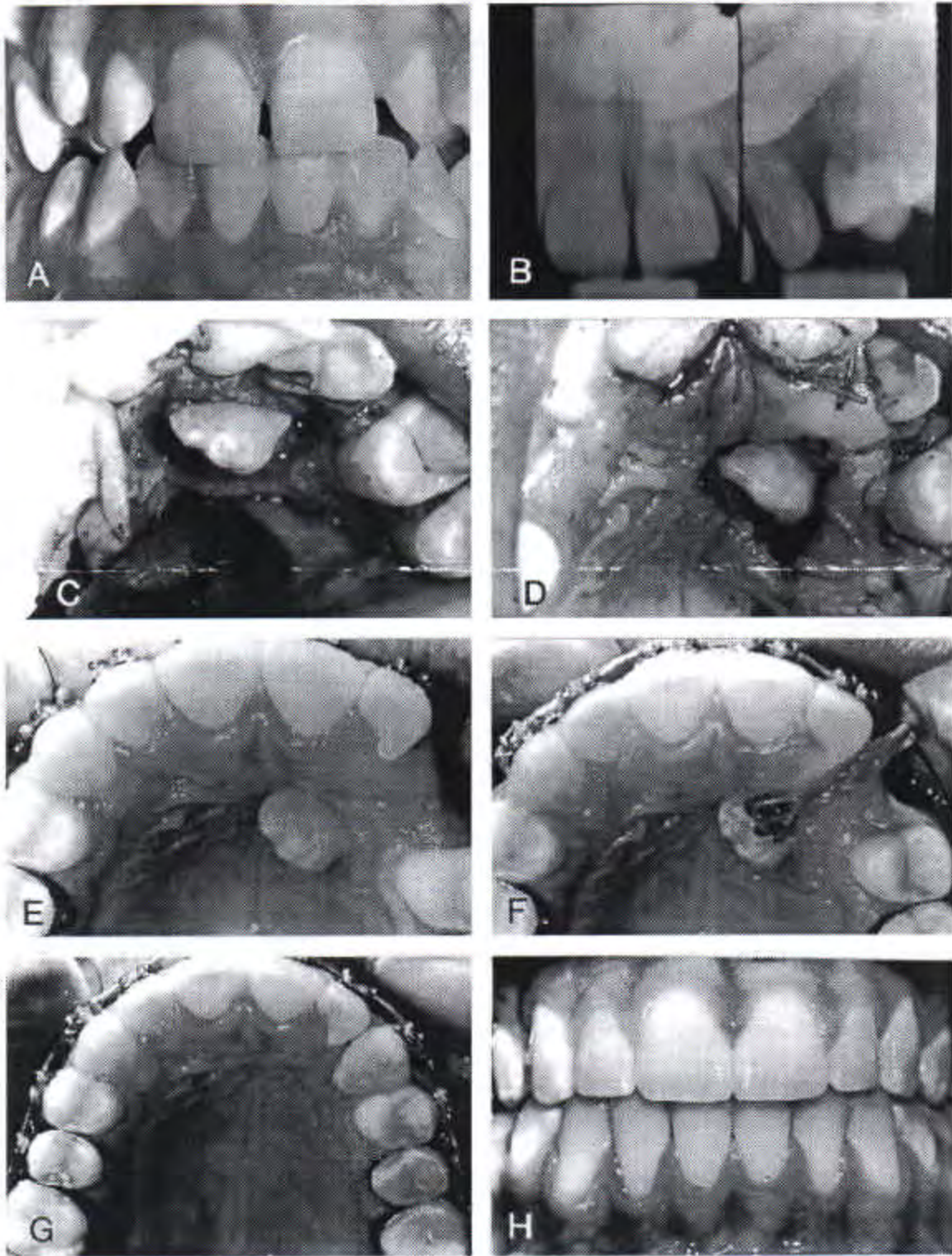


Figure 24-10. A patient with a palatally impacted maxillary left canine. *A.* The intraoral photograph shows that the patient had interdental spacing in the maxillary arch. *B.* The periapical radiographs confirmed that the maxillary canine was impacted palatally. In order to allow the canine to erupt during the initial stages of orthodontic treatment, the tooth was uncovered before placement of orthodontic brackets. *C.* A palatal flap was elevated in order to locate the impacted canine. The follicle was removed, and all of the bone was removed from around the crown. *D.* The flap was reapproximated, and a window was cut in the flap to allow the canine to protrude into the oral cavity. *E.* One year after uncovering, orthodontic treatment had begun, and space was created for the canine. By that time, the tooth had erupted farther into the oral cavity. *F.* The tooth then could be moved laterally into proper position. The independent eruption of the tooth facilitates movement of the tooth laterally. *G.* After movement into the dental arch, a bracket was placed and the root was positioned appropriately. *H.* After orthodontic treatment, the position of the canine on the left side matches the non-impacted canine on the right side.

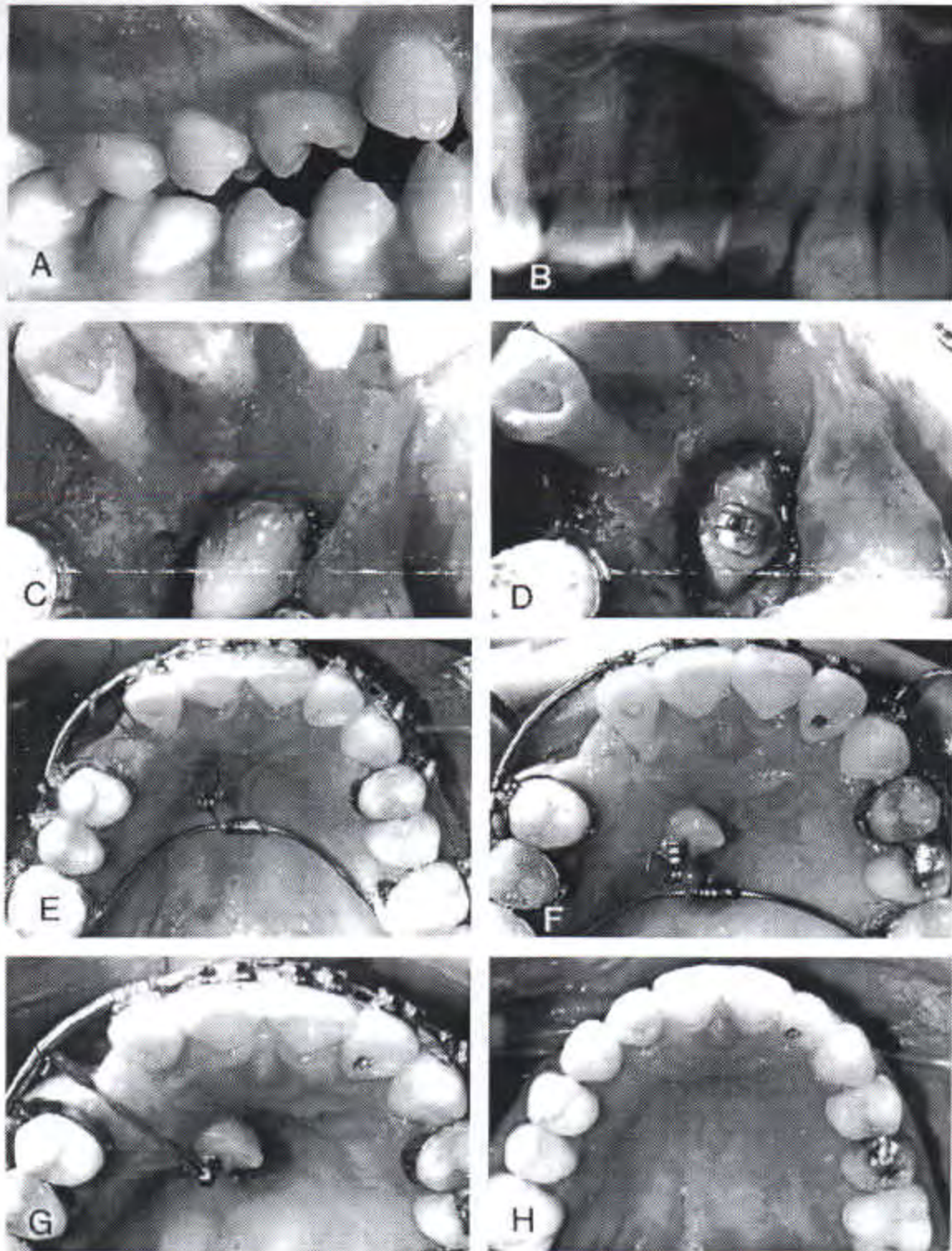


Figure 24-11. An adolescent patient with a complex palatally and horizontally impacted maxillary right canine. *A*. The impacted canine crown was located near the apices of the maxillary central incisors. *B*. Because the canine did not erupt, the maxillary first premolar and lateral incisor drifted toward one another, closing the space for the canine. Initially, orthodontic mechanics were used to open space for the impacted canine. *C*. A palatal flap was elevated to expose the crown of the canine. It was impacted next to the roots of the central and lateral incisors. All of the bone was removed over the crown. *D*. A cleat was bonded to the crown of the canine. The palatal flap was repositioned, and a window of tissue was removed over the eyelet. A dressing was placed on the exposed crown. *E*. A lingual arch was constructed and soldered to the maxillary first molar bands. *F*. A spring was soldered to the mid-portion of the palatal arch. This spring permitted eruption and posterior movement of the crown of the impacted canine to avoid damaging roots of the central and lateral incisors. *G*. After the crown of the canine had been moved away from the central and lateral incisors and into the oral cavity, an elastomeric chain was attached to the archwire to gradually move the canine into the dental arch. *H*. After orthodontic treatment, the position of the canine was corrected, and the shape of the dental arch was maintained.

through the midline (Fig. 24-11C). A modification of the flap can be used when the tooth is impacted very high in the roof of the palate.^{11, 12} Bone is removed from the crown of the impacted tooth, being very careful not to damage the roots of the central or lateral incisor, especially around the apices of these teeth. The area is isolated to achieve a dry field for bracketing. Surgical notes should be made of the tooth and its bone relationship, and a photograph should be taken.¹² Documenting the surgery photographically or digitally will help the orthodontist in choosing the appropriate mechanics to erupt the tooth. A bracket is bonded to the tooth; pulling on the bracket with a hemostat will test the bond strength as well as verify the mobility of the tooth. If the canine is ankylosed, it should be luxated and loosened in the alveolus. The flap is returned to its original position. Before suturing, the flap is palpated to locate the bracket. This area of the flap is fenestrated with a #15 blade, so the bracket protrudes through the "window" in the flap¹² (Fig. 24-11E). The palatal flap then is sutured to its original position using 4-0 gut suture with a continuous sling technique. A ligating wire or gold chain is attached from the bracket and runs outside the flap to the archwire. In one to two weeks, the orthodontist can initiate tooth movement. If the tooth is ankylosed, immediate force should be applied.

Postoperative Orthodontics

In the instance of a simple palatal impaction, the canine will have erupted partially into the palate after pre-orthodontic uncovering. In most cases, an attachment can be bonded to the crown of the tooth. If the tooth has erupted sufficiently, an elastomeric chain can be used to move the canine laterally into the dental arch gradually. During this time, a non-resilient rectangular stainless steel archwire should be used to avoid arch distortion.

If the canine is impacted near the roof of the mouth, it is difficult to move the tooth directly into the arch. In these situations, it is advantageous first to erupt the tooth into the oral cavity and then to attach it to the archwire. A transpalatal arch connected to the maxillary molars provides suitable anchorage for the eruption process. A flexible spring or loop may be attached to the transpalatal bar. This attachment is activated to provide a vertical direction of eruption.

After the tooth has erupted sufficiently, it may be attached to the maxillary archwire and moved laterally into the dental arch. An important aspect during this process is to maintain the original arch width. There are several options for moving the canine laterally. Elastomeric chain or elastic thread is easy to attach and provides adequate force to move the canine into position. The disadvantage of the chain and thread is that the force levels produced by these materials diminish gradually, requiring frequent changing of the elastic modules. As the tooth nears its proper position in the

arch, a double archwire may be used to move the canine into position. A flexible auxiliary wire made of nickel titanium may be attached in addition to the rectangular wire. The attachment of the auxiliary wire will ensure that the transpalatal width does not change as the tooth is brought into position.

After the canine has been moved into the arch, a radiograph should be taken. Final positioning of the root and crown requires placement of a rectangular wire. If the tooth has been moved from the palate, there usually is insufficient labial crown torque. The use of auxiliary torquing springs or rectangular archwires will accomplish the proper torque and angulation.

MANDIBULAR CANINE

Etiology

Impaction of the mandibular canine (Fig. 24-12) is uncommon. In some situations, the tooth bud of the mandibular canine will become rotated in the alveolus. As that happens, the canine root can develop in a horizontal direction. The canine then becomes impacted below the apices of the incisors. In these situations, it is very difficult to correct the impaction. In some of these patients, it is prudent to extract the canine to avoid damage to the roots of the incisors.

Occasionally, the mandibular canine will become impacted due to the presence of a supernumerary tooth. This type of impaction is similar to that found in the maxillary arch. If the supernumerary is not removed early enough and the root of the canine forms completely, then the canine will lose its eruptive potential. In this situation, the tooth must be uncovered surgically and erupted orthodontically into position.

Preoperative Orthodontics

Initially, bands and brackets must be placed on all teeth, and space is opened for the mandibular canine. Usually 6.5 to 7 mm of space is adequate for most mandibular canines. After the space has been opened, a stabilizing rectangular wire is placed (Fig. 24-12C), and the patient is referred to the surgeon to uncover the tooth.

Surgery

When mandibular canines are impacted, they usually are in the intra-alveolar or labial position. It is very important that the surgeon has proper radiographs to determine the exact location of the tooth before surgery. Again, the Buccal Object Rule⁶ can be used to locate the impacted tooth precisely.

The intra-alveolar impaction can be uncovered with the flap closed-eruption technique. To use this technique properly, it is imperative that orthodontic appli-

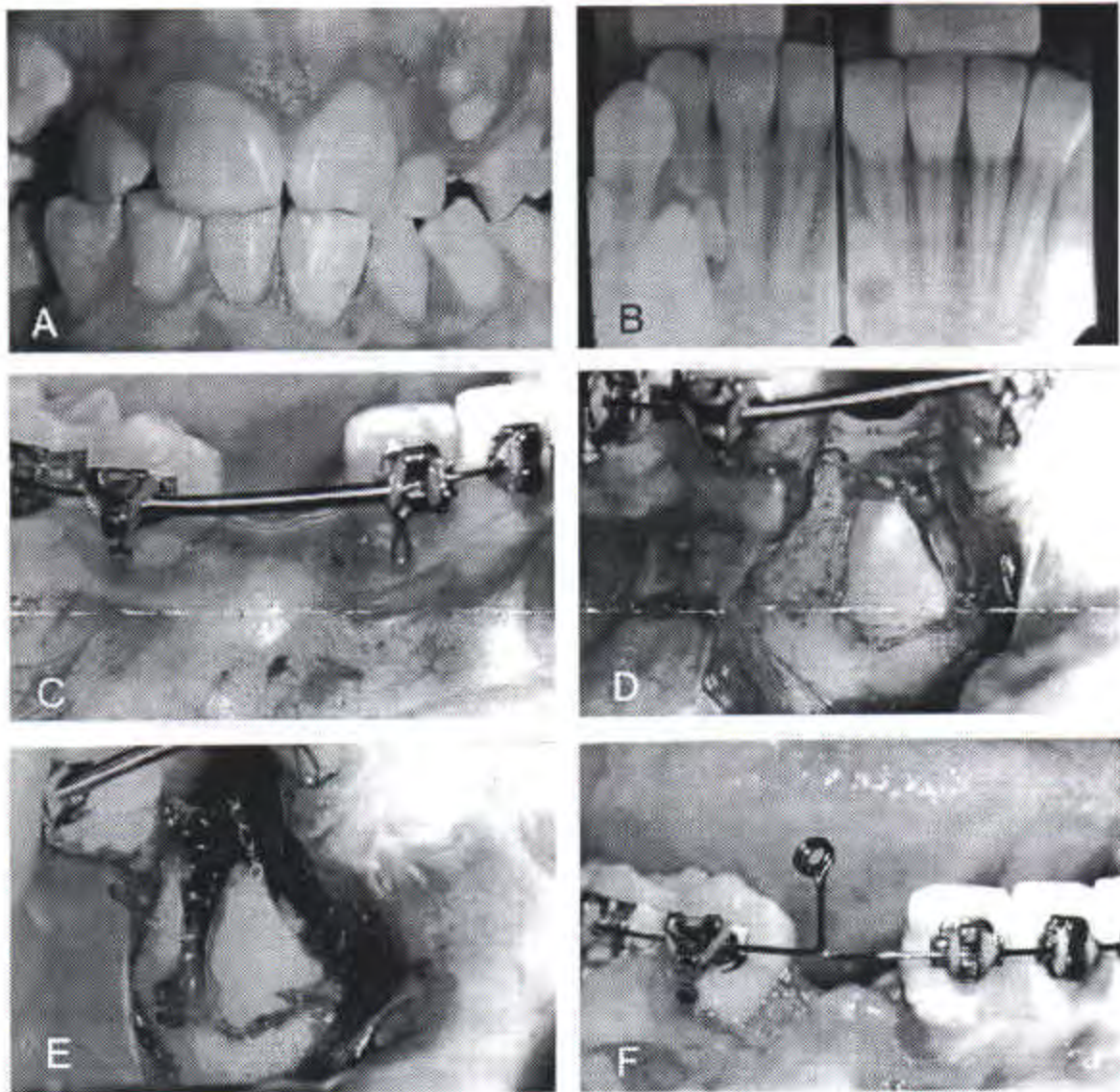


Figure 24-12. An adolescent patient with an impacted mandibular right canine. *A*. The pretreatment intraoral photograph shows that the patient had moderate arch length deficiencies with the maxillary canines erupting ectopically toward the labial. *B*. The pretreatment radiograph showed a supernumerary tooth that had impeded eruption of the mandibular right canine. The primary canine and supernumerary tooth were removed. *C*. Orthodontic treatment was initiated to open space for the permanent canine. *D*. A pedicle flap with a mid-crestal incision was reflected to uncover the impacted canine. The bone was removed from around the crown. *E*. A piece of gold chain was bonded to the cusp tip of the canine. *F, G*. A Ballista loop was used to deliver an eruptive vertical force to the impacted canine. *H*. After the tooth had erupted, the gold chain still was visible at the cusp tip. The tooth was rotated. *I*. Stainless steel buttons and elastomeric chains were used to rotate the tooth into proper position. *J*. After orthodontic treatment, the mandibular right canine was positioned properly in the dental arch. The crown length and position of the gingival margin match the opposite unimpacted tooth. Use of a flap/closed eruption procedure allows tooth movement that closely matches natural tooth eruption.

ances have been placed on the teeth, and the patient is at the stage where the appropriate archwire size is present to help facilitate eruption of the tooth. The deciduous tooth and any supernumerary teeth should be extracted at the time of the uncovering. If the patient is too young to initiate orthodontic therapy, then these teeth should be removed at the appropriate times to help the impacted canine erupt on its own.

To uncover the intra-alveolar impaction, the flap closed-eruption technique is used. A crestal incision is made with conservative flap reflection (Fig. 24-12DE). Appropriate bone removal is accomplished and a bracket and/or chain, is bonded to the tooth. The flaps are returned to their original location and sutured with resorbable suture. The orthodontist can initiate tooth movement in one week.

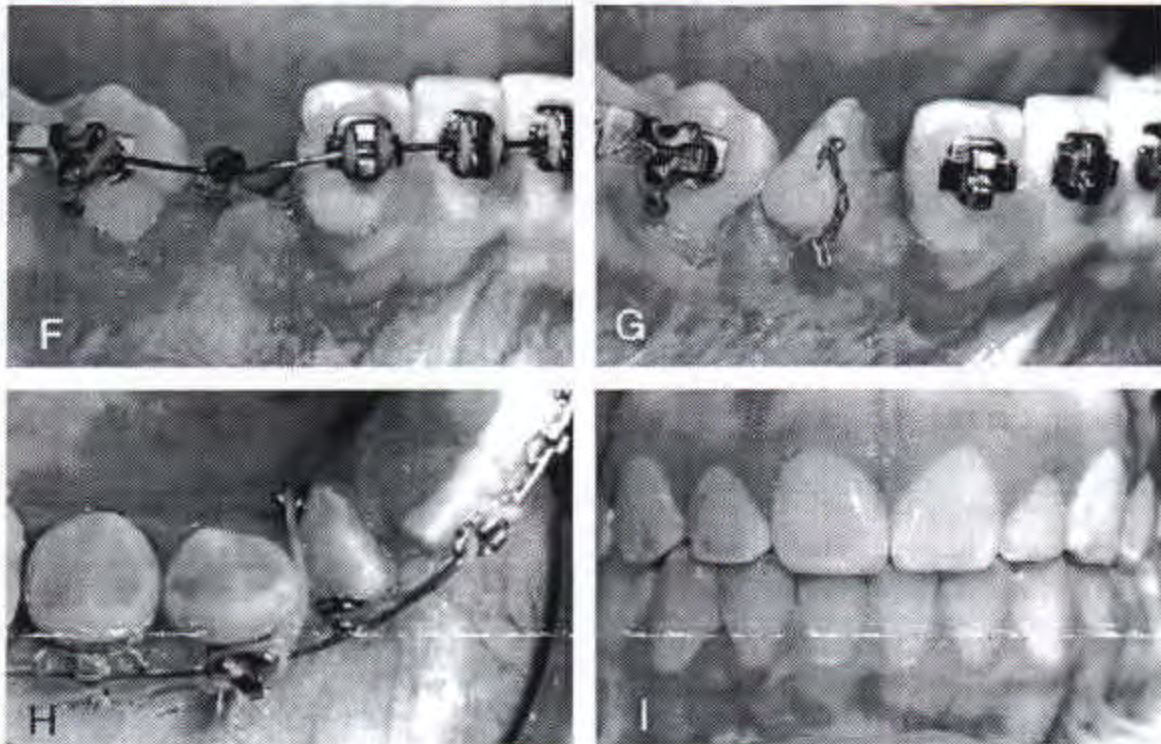


Figure 24-12 (Continued)

Postoperative Orthodontics

After the mandibular canine has been uncovered, a chain or wire will be extending through the gingival tissue into the oral cavity. The key in this situation is to erupt the tooth through the crest of the alveolar ridge. In order to accomplish this, it is advantageous to use a Ballista spring (Figs. 24-5 and 24-12F) to erupt the tooth in a vertical direction. This spring typically is made out of .018" round archwire. As the tooth erupts, the links of the chain can be removed until the crown has erupted sufficiently into the oral cavity. At that point, a bracket may be placed on the tooth.

Occasionally, the canine will erupt into a rotated position. Mechanics to derotate the tooth must be used before aligning the crown and root into the dental arch. During the finishing phase of orthodontic treatment, the root of the tooth must be positioned to match the axial inclination of the adjacent teeth.

MANDIBULAR SECOND PREMOLAR

Etiology

The most common mandibular impaction is the third molar, followed by the second premolar and the second molar. The second premolar impaction (Fig. 24-13) probably is due to idiopathic rotation of the tooth bud

during development. If the tooth bud does not upright itself as the root develops, it eventually will become impacted horizontally. In this situation, surgical exposure of the tooth and orthodontic treatment will be necessary to properly position the tooth.

Preoperative Orthodontics

Prior to initiation of orthodontic therapy, the primary second molar should be removed to encourage eruption of the impacted second premolar. In some situations, the premolar may erupt spontaneously in response to the extraction of the primary tooth. If orthodontic treatment will be delayed, a mandibular space maintainer will hold the position of the first molar. If orthodontic treatment is necessary to erupt the second premolar, it generally is advisable to wait until all permanent teeth have erupted. It also is advantageous to wait until the root of the second premolar has formed completely. Often when second premolars are impacted, they also have delayed root formation.

During the preoperative orthodontic phase, it will be necessary to provide sufficient space for the second premolar. Usually the contralateral second premolar can be used as a guide for tooth size. If both second premolars are impacted, the size of the second premolars generally is about 0.5 to 1 mm larger than the first premolars. After sufficient space has been established, the patient is referred to the surgeon to uncover the second premolar.

Surgery

Second premolars usually can be located by palpation. They often are impacted on the lingual aspect of the mandibular corpus. If a tooth cannot be palpated, an occlusal radiograph or two differently angled periapical radiographs should be used to determine its exact location. When the tooth is impacted lingually, a full thickness lingual flap is reflected from the canine to the mesial of the second molar (Fig. 24-13D). Sometimes a

vertical incision is needed when the impacted tooth is positioned near the apices of the adjacent teeth. Judicious bone removal is accomplished to create a hole wide enough for the widest dimension of the crown. The surgeon must proceed carefully when the tooth is displaced lingually, because it usually is located near the roots of the first molar (creating a bony dehiscence). A bracket and/or chain is placed and attached to the archwire (Fig. 24-13EF). The lingual flap is returned to its original location. Slight scalloping of the flap can be

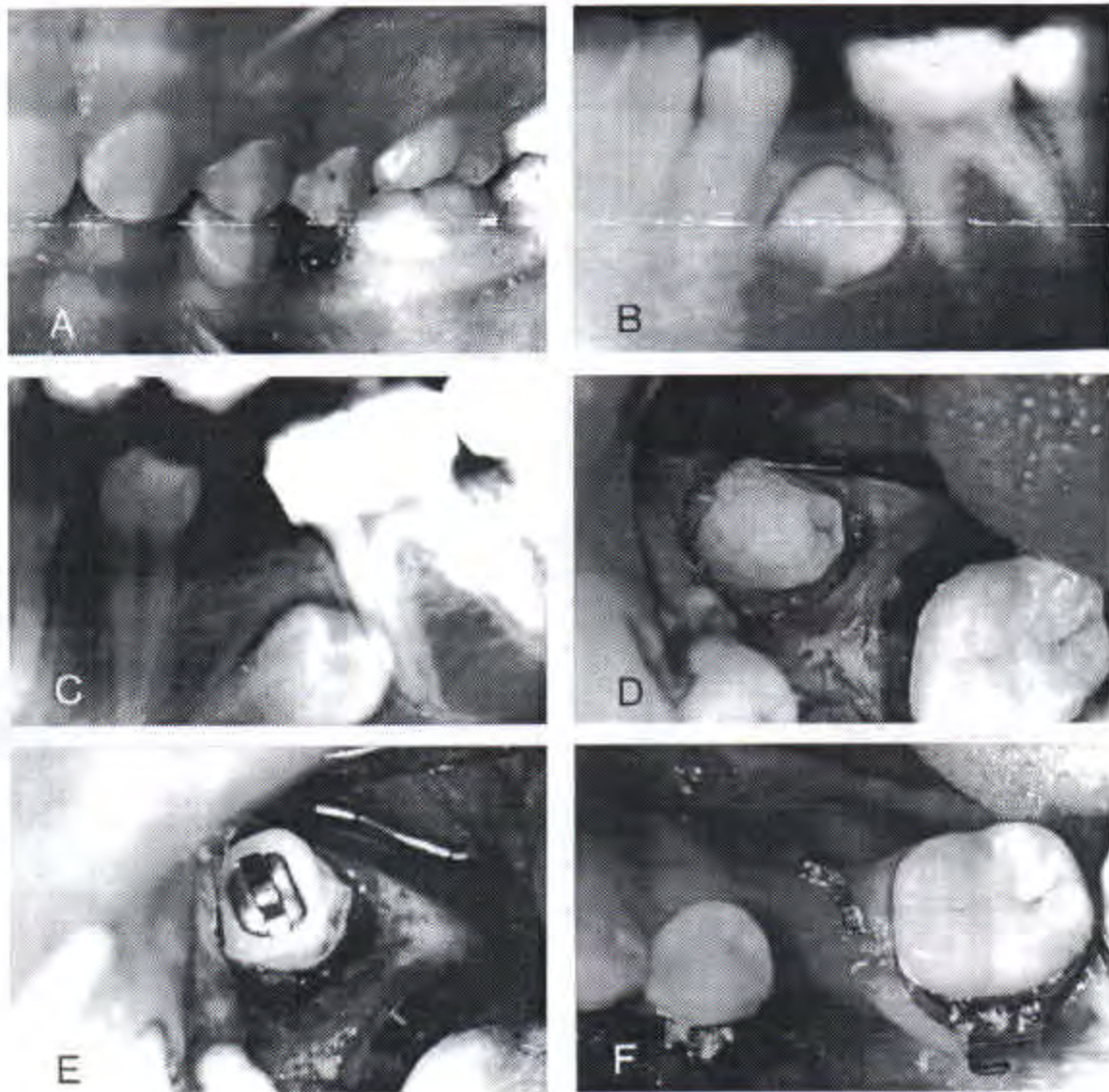


Figure 24-13. A patient with a horizontally impacted mandibular left second premolar. *A*. Pretreatment intraoral photograph. *B*. Although the maxillary and mandibular second molars had erupted, the pretreatment intraoral radiograph shows that the development of the mandibular left second premolar was delayed. The root had not developed. Orthodontic treatment was postponed for two years. *C*. After two years, the root of the second premolar had developed, but the tooth was impacted horizontally. *D*. Orthodontic appliances were placed on the teeth, and after sufficient space had been created, a lingual flap with vertical incisions was used to uncover the lingually and horizontally impacted mandibular second premolar. *E*. A cleat was bonded onto the crown of the premolar, and a gold chain was attached and extended out to the archwire. *F*. The flap was reapproximated and allowed to heal.

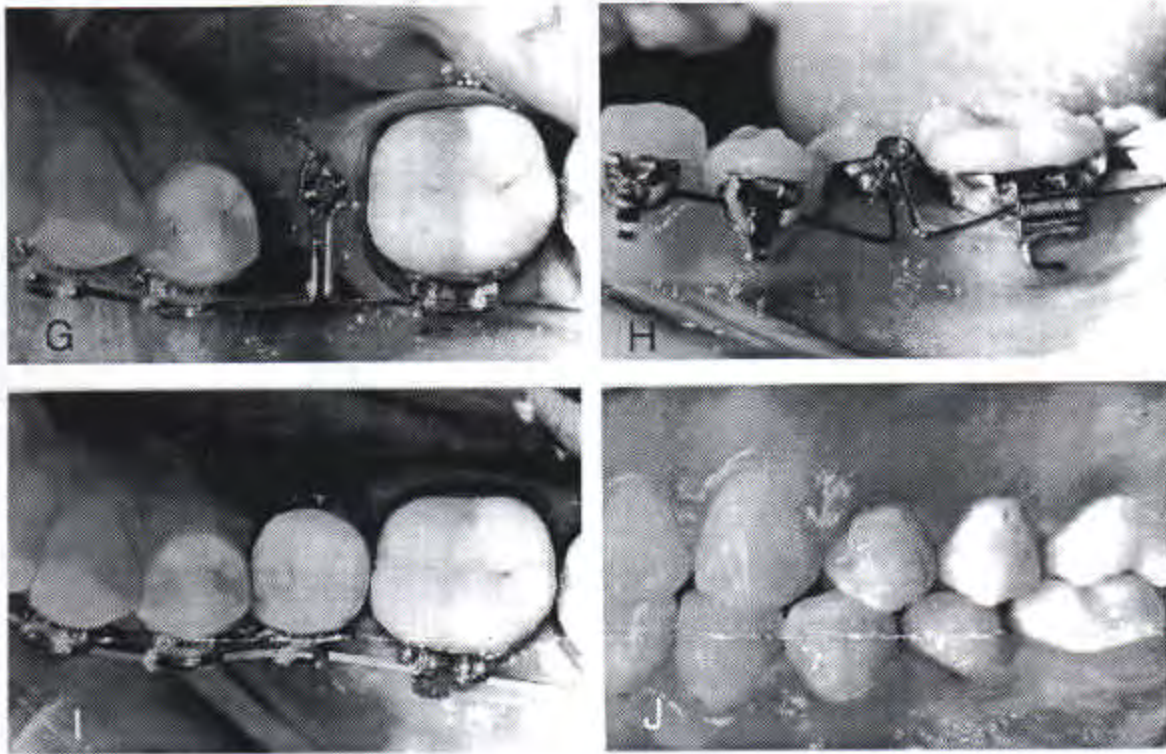


Figure 24-13 (Continued) *G, H.* A Ballista spring was used to erupt the canine and move it into position in the center of the alveolar ridge. *I.* Although the second premolar was rotated 180° in the alveolus, the decision was made to leave the premolar in its rotated position. The crown was positioned properly, and the occlusion was finished. *J.* After orthodontic treatment, the amount of gingiva labial to the formerly impacted premolar was adequate, as the tooth was erupted with a flap/closed eruption technique.

performed around the crown so it remains partially exposed. This *manipulation of the flap* will allow the orthodontist to use the necessary mechanics to erupt the tooth. If the impacted premolar is located within the alveolus, the closed eruption technique can be used.

Postoperative Orthodontics

Usually the crown of the impacted second premolar lies either within the alveolar housing or toward the lingual surface. If the tooth is positioned lingually, the crown will be visible after uncovering. In this situation, a bracket should be attached to the crown. Elastomeric chains or elastic thread may be used to move the tooth into position.

If the tooth is confined within the alveolar housing, a flap closed-eruption technique should be performed. The tooth will not be visible after the attachments have been placed. A wire or chain should extend through the gingiva at the crest of the alveolar ridge. In this situation, a Ballista spring may be used to erupt the tooth through the crest of the ridge. A radiograph should be made after the tooth is positioned in the dental arch. In some situations, the root of the second premolar is dilacerated. The angulation of the root should be assessed so the tooth may be positioned properly between the

first premolar and first molar. A rectangular archwire often is needed to provide the proper torque and angulation.

MANDIBULAR FIRST MOLAR

Etiology

The etiology of mandibular first molar impaction (Fig. 24-14) is unknown. For some reason, the first molar fails to erupt. In some instances, this may be confused with ankylosis; however, many of these teeth are probably not ankylosed. The key in this situation is to diagnose the problem early. If the patient is seen in the early mixed dentition, it may be possible to uncover the tooth and erupt it into position. As time passes, however, the molar may need to be extracted if the tooth remains submerged to allow the second molar to drift mesially.

Preoperative Orthodontics

If the mandibular first molar is hopelessly impacted and is located significantly below the occlusal plane, this tooth may need to be extracted. In this situation, a mandibular lingual arch may help to avoid a change in

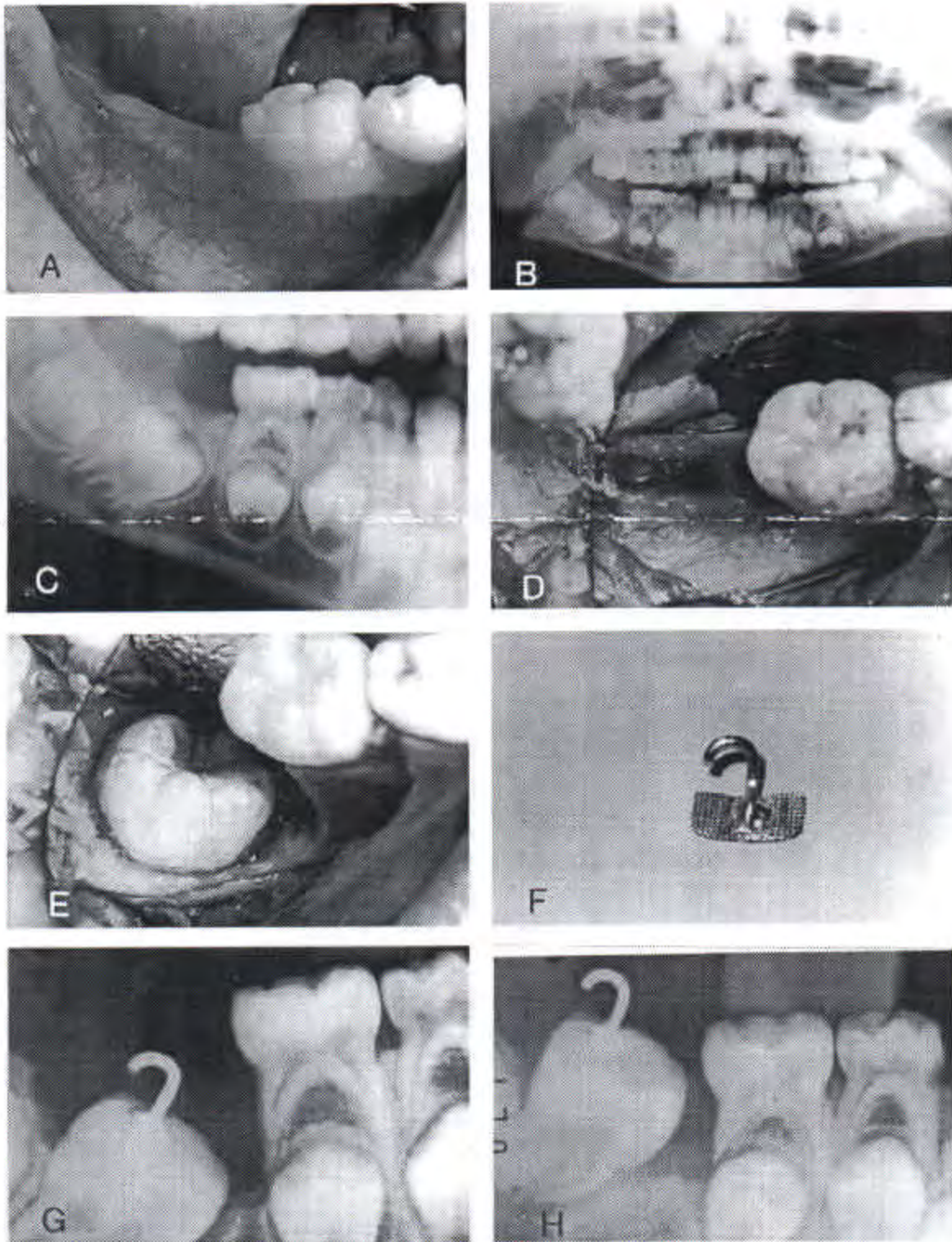


Figure 24-14. A young patient with an impacted mandibular right first molar. *A*. Pretreatment intraoral photograph. *B*, *C*. The pretreatment panoramic radiograph indicated that the mandibular right first molar was impacted and angulated mesially. The tooth was well below the level of the eruption of the contralateral first molar and maxillary first molars. The treatment plan involved uncovering the tooth, bonding an attachment, and using an elastic force from the maxillary arch to erupt the impacted molar. *D*. A flap was elevated over the ridge, distal to the mandibular right primary second molar. *E*. The bone over the first molar crown was removed. *F*. A piece of wire mesh was soldered to a segment of archwire shaped in the form of a hook, and this attachment was bonded the buccal surface of the first molar (*G*). *H*. A palatal expander was placed in the maxilla, and a rubber band was used to erupt the first molar.

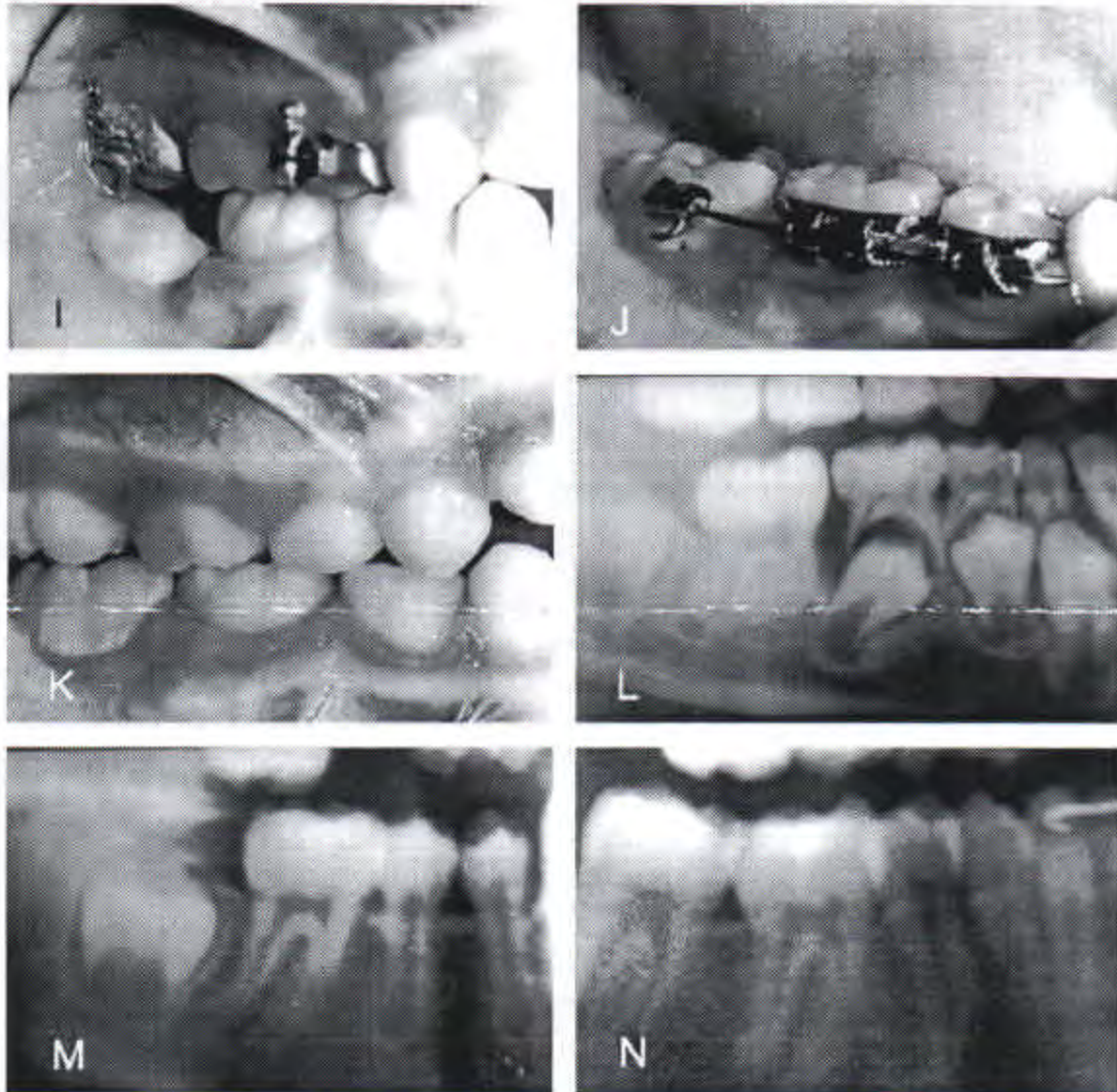


Figure 24-14 (Continued) *I, J.* After the first molar had erupted, the bonded attachment was removed and a bracket was placed on the tooth. Segmental orthodontic techniques were used to complete the uprighting process. *K.* After bracket removal, the mandibular first molar was positioned in proper occlusion with the maxillary arch. *L.* The panoramic radiograph showed that the mandibular right second premolar had angulated somewhat mesially during the eruption of the first molar. *M, N.* After 12 months, the second premolar had erupted. The first molar also was erupting. The tooth appeared to be developing normally 1.5 years after the orthodontic treatment had been completed.

the mandibular dental midline. Placing a lingual arch between the mandibular lateral incisor and first molar on the opposite side will maintain the dental midline. In that way, the posterior teeth may erupt more toward the mesial. When all teeth erupt, the second molar can be moved mesially and substituted for the first molar.

If the patient is seen at an early age, the impacted mandibular first molar may be uncovered and erupted. It is important, however, to have sufficient anchorage to erupt the impacted molar. During the preoperative orthodontic phase, a stabilizing appliance should be placed in the opposite arch, using the maxillary first molar as an anchor tooth to erupt the impacted man-

dibular first molar. A palatal expander or a transpalatal arch is helpful to obtain cross-arch anchorage. The ideal way to erupt the tooth would be with elastic or rubber band forces to the teeth in the opposite arch. Once the expander or stabilizing appliance has been cemented, the patient should be referred to the surgeon to uncover the impacted mandibular first molar.

Surgery

Fortunately, mandibular first molars rarely are impacted, and they can be very difficult to uncover adequately. It is a challenge to uncover the tooth com-

pletely and not damage adjacent teeth or tooth buds. A common error in uncovering teeth that are embedded in the mid-alveolar region is to not remove enough bone so that the greatest width of the tooth can be erupted through the opening. Due to the "bell" shape of posterior teeth, the widest dimension usually is found in the mid-coronal region (Fig. 24-14E).

These teeth usually are in the mid-alveolar region; however, appropriate radiographs need to be taken to verify the exact position of the tooth before uncovering. The closed-eruption technique is used, but more extensive flap reflection will be needed due to the severe apical position of the tooth (Fig. 24-14D). Vertical incisions can be used on the buccal aspect to facilitate access. Great care must be taken to avoid damage to the adjacent roots, tooth buds, and the mental nerve. The tooth is isolated, and the appropriate bracket is bonded to the tooth. A chain is ligated to the bracket and exits through the crestal incision and is attached to the archwire. The flaps are returned to their original location and sutured. Tooth movement can be initiated within a week.

Postoperative Orthodontics

After the surgical procedure, the patient will have an attachment protruding through the gingival tissue. Again, it is important to erupt the tooth through the crest of the ridge. In this way, the patient will have sufficient attached gingiva after it has erupted. Usually a hook (Fig. 24-14F) will be protruding through the gingiva. A rubber band can be worn from this hook to the palatal expander and the first molar in the opposite arch. When the patient chews and functions, the rubber bands will stretch, and the tooth will be erupted. If the tooth does not move, the surgeon may not have removed enough bone around the crown of the tooth. After the tooth has erupted sufficiently, using an elastic force, a bracket may be placed on the crown of the first molar (Fig. 24-14GH). The adjacent posterior primary molars in that segment can be banded or bracketed and used as anchors to upright the permanent first molar. This technique of erupting the impacted mandibular first molar is efficient and avoids distortion of the occlusal plane in the opposing arch.

MANDIBULAR SECOND MOLAR

Etiology

Impaction of the mandibular second molars (Fig. 24-15) occurs in less than one percent of the population.¹³⁻¹⁵ When it occurs, however, second molar impaction is a difficult problem to correct. Some second molar impactions occur spontaneously and may be related to the position of the third molar. The reason for the im-

paction may be due to differential development of the mesial and distal roots of the second molar. If the distal root develops first, the crown of the second molar may tip toward the mesial. Second molar impaction also may occur iatrogenically. Such an impaction may be the result of attempting to increase arch length in the mandibular arch. During this process, the mandibular first molar may tip distally and impact the second molar. In either situation, it often is necessary to uncover the tooth and position it orthodontically.

Preoperative Orthodontics

Prior to orthodontic treatment, the mandibular third molar should be evaluated. If the third molars will interfere with the eruption or distal movement of the second molars, they may need to be extracted. Another consideration may be possible. If the second molars are hopelessly impacted horizontally, and the third molars are in a reasonably good position, it may be prudent to extract the second molars. This is not a guaranteed solution, because in some situations, the third molars also may become impacted horizontally.

It is necessary to place orthodontic appliances on all remaining mandibular teeth to provide sufficient anchorage to move the second molars into their proper position. Once the mandibular teeth have been aligned and stabilized, the patient should be referred for uncovering of the second molar.

Surgery

Mandibular second molars usually are impacted in the mid-alveolar region. When they are "locked" under the first molar, they will need to be uncovered and left uncovered so that the orthodontist can apply appropriate mechanics to erupt the tooth. In the example shown in Figure 24-14, the flap closed-eruption technique cannot be used due to the mesial angulation. A modification of the technique is needed for proper exposure and orthodontic access.

A gingivectomy rarely is adequate to uncover enough of the buccal surface of these teeth. This inadequacy is due to the narrow width of the attached gingiva in this area and the mesial angulation of the tooth in the vestibule. Therefore, a conservative lingual flap and a buccal pedicle flap are reflected for access (Fig. 24-15D). Enough bone is removed to expose two-thirds of the crown. The lingual flap is positioned apically to uncover the lingual/coronal aspect of the molar. The buccal pedicle flap is positioned apically exposing two-thirds of the crown (Fig. 24-15E). A dressing then is placed on the buccal surface to keep the tissue in place and avoid hypertrophy of adjacent tissue. Within a week the tooth can be bracketed, and tooth movement can be initiated.

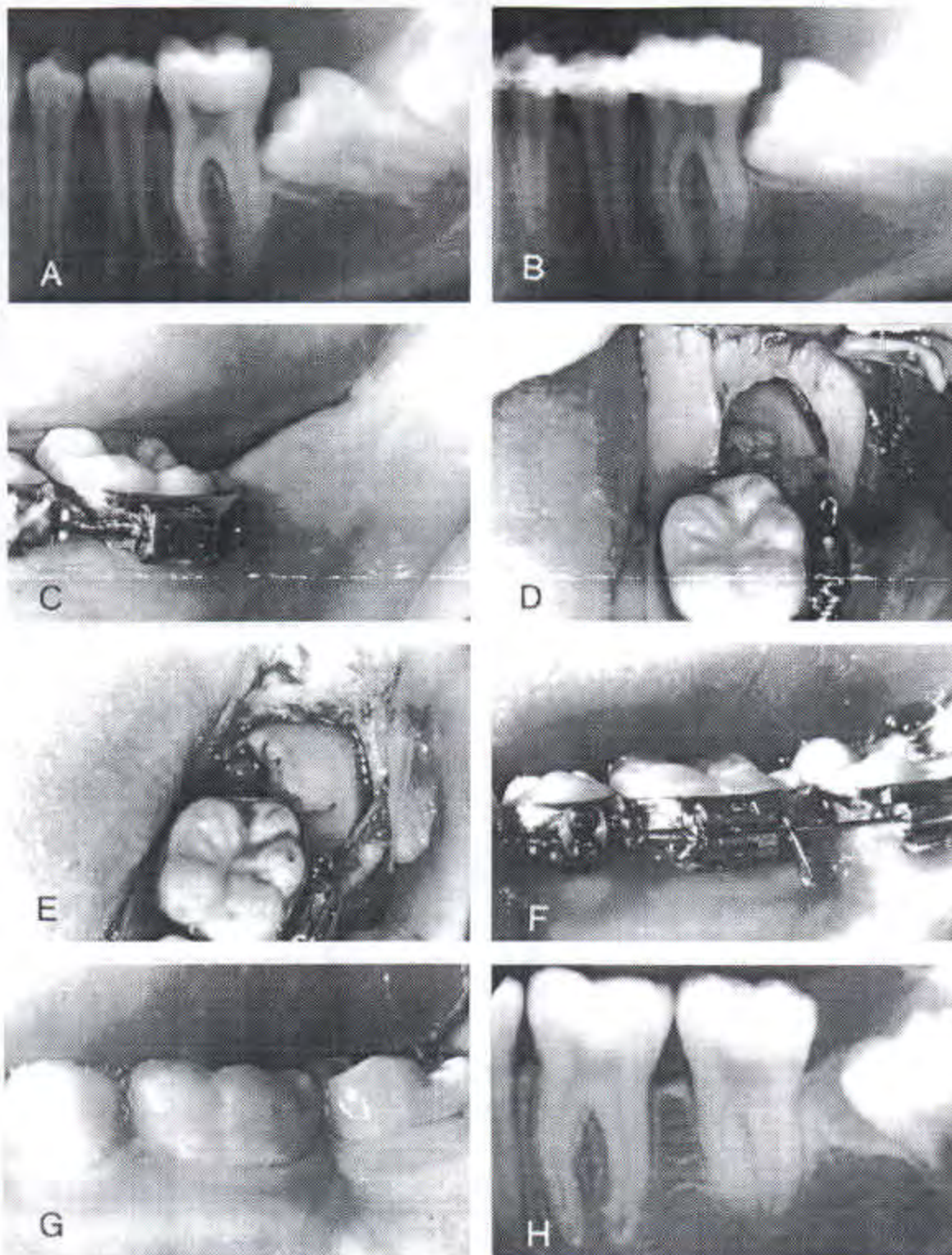


Figure 24-15: An adolescent patient with an impacted mandibular second molar. *A*. The mandibular left second molar was angulated mesially and impacted distal to the first molar. *B*. Orthodontic appliances were placed on all teeth, and initial alignment of the dental arches was achieved. The position of the impacted second molar did not improve. *C*. This preoperative intraoral photograph shows that the amount of gingiva distal to the first molar was not sufficient to permit a gingivectomy to expose the tooth. *D*. Therefore, a buccal pedicle flap and a lingual flap were elevated from the crest of the ridge to expose the second molar, which was covered by bone. *E*. The bone covering the buccal and occlusal portions of the second molar crown was removed. The buccal and lingual flaps were apically positioned to expose the second molar. *F*. After sufficient healing, the second molar was gradually erupted into position. *G*. The amount of attached gingiva buccal to the mandibular second molar has been increased with the apically positioned flap technique. *H*. The roots of the second molar have been positioned properly. The impacted third molar did not impede tooth movement and can be extracted later.

Postoperative Orthodontics

If the second molar is tipped severely to the mesial, it may be impossible to place a bracket on the buccal surface of the tooth. In those situations, a bracket or other attachment may be bonded to the occlusal or distal surface of the second molar. A spring from the first molar also can be used to push the second molar distally.

If the tooth is tipped moderately, a bracket may be placed on the buccal surface. A flexible nickel titanium wire is useful in engaging the bracket. These wires are very effective at producing gradual movement to upright the second molar. Again, it is important to assess the proximity of the third molars to determine if they will interfere with the movement of the second molars. After initial uprighting of the second molar, a rectangular wire usually is necessary to produce the proper axial inclination of the root.

POTENTIAL PROBLEMS

Lack of Movement

After uncovering an impacted tooth, orthodontic mechanics to erupt the tooth may be started within a few weeks. Occasionally the impacted tooth may seem immobile and resist orthodontic force. This situation occurs more commonly with palatal rather than intra-alveolar impactions. Usually this problem is temporary. Persistent orthodontic force in the proper direction usually will move the impacted tooth. In some patients, however, the impacted tooth will continue to resist movement. This problem has three possible causes. First, during the uncovering procedure, bone may have been left around the crown of the impacted tooth. As an orthodontic force is applied, there is no biologic mechanism for the enamel of the crown to resorb the surrounding bone. The tooth becomes wedge in the alveolus. It is important for the surgeon to remove sufficient bone to permit clearance of the crown of the impacted tooth as it erupts.

A second possible cause of lack of tooth movement is the use of inappropriate orthodontic mechanics. An impacted tooth may resist lateral movement because of its angulation within the alveolus. The solution for this problem is to erupt the tooth into the oral cavity initially. Extrusive mechanics do not require bone resorption. If the tooth can be erupted initially into the oral cavity, then it can be moved into position more easily.

The third possible cause of immobility is ankylosis. Although it is rare, ankylosis of an impacted tooth may occur. When the tooth is uncovered, it is important for the surgeon to test the mobility of the tooth. If the impacted tooth is mobile, it probably will erupt if the direction of force is correct. If not, the tooth may be ankylosed and should be luxated or loosened within its

alveolar housing. Some ankylosed teeth will still not move and will require extraction.

During orthodontic finishing, it is important to position the root of an impacted tooth properly to avoid potential relapse. As a palatally impacted canine is moved laterally toward the alveolar crest, the root often tips toward the palate. If the root remains in this position after appliance removal, the crown will tend to migrate back toward the palate and into crossbite. Therefore, during orthodontic finishing, it is important to tip the root of the canine labially. This movement is performed with rectangular archwires or torquing springs. This process must be performed gradually, however. If the canine root is moved labially too rapidly, a dehiscence may occur at the labial crestal margin. If the tissue is thin over this defect, the gingival tissue may recede exposing the cementum of the root. In these situations, it may be necessary to refer the patient for gingival grafting to prevent recession.

In some situations, it may be more prudent to extract an impacted tooth rather than to attempt erupting it into the dental arch. Although this situation is rare, it may occur in patients with palatally impacted canines and horizontally impacted mandibular canines and second molars. If the maxillary canine is impacted horizontally and is high in the palate, and the patient has significant crowding of the maxillary teeth, it may be more judicious to extract an impacted canine instead of a first premolar. In this situation, the first premolar should be non-restored, non-carious, have good root form, and be in proper position to justify this unique extraction decision.

In the mandibular arch, a horizontally impacted mandibular second molar may be difficult to erupt. If the patient has third molars that are in reasonable relationship, it may be more judicious to extract the mandibular second molars. This extraction, however, does not ensure that the third molars will erupt into their proper position. Occasionally, the third molars also will be tipped to the mesial and require orthodontic uprighting.

Occasionally, the palatally impacted canine will be wedged against the root of the maxillary central or lateral incisor. In some of these patients, this close proximity of the impacted crown will cause resorption of the roots of the incisors. In this situation, it is important to develop orthodontic mechanics to move the crown of the impacted tooth away from the roots of the incisors. Usually, after proper positioning of the impacted tooth and completion of the orthodontic treatment, the root resorption will cease. If the root of the affected incisor has not shortened significantly, it may remain functional indefinitely.

A common question is whether or not to extract the third molars during the uncovering of the impacted second molars. If sufficient space exists for the third molars to erupt, they can be extracted at the time of uncover-

ing; however, there are some possible disadvantages. The amount of trauma and postoperative discomfort will be greater and may delay bracketing of the second molars. Second, it may complicate flap management if both teeth are difficult impactions. The second molar will require considerable apical positioning of the flap, whereas the third molar site will require primary closure. These two adjacent flaps are not compatible. The primary goal is to uncover the second molar adequately. It may be more prudent to remove the third molars after completion of the orthodontic treatment.

Surgical Complications

Improper technique is the most common problem when impacted teeth are uncovered surgically. Inadequate surgery can complicate or even make orthodontic movement impossible. Inadequate flap reflection or operating through a "pigeon hole" can lead to damage to the crown or adjacent roots, inadequate or excessive bone removal, and poor isolation, causing a weakly bonded bracket.¹¹ Improper technique also can lead to loss of attached gingiva and damage to the attachment apparatus.^{3,5,9} It also can lead to unesthetic gingival sequelae, seen most commonly when a gingivectomy is attempted in an improper situation.

The apically positioned flap has been the most common technique for uncovering labial impactions. Although this technique is appropriate for some labially impacted teeth (transposed labial impactions), the flap closed-eruption technique is the procedure of choice for most labial impactions and mid-alveolar impactions. When the apically positioned flap is not employed properly, the following problems may be encountered:

1. This technique produces a greater risk of recession and uneven gingival margins compared with the non-impacted contralateral tooth.¹⁶
2. Impactions located near the nasal spine are impossible to leave uncovered.⁷⁻⁹
3. When this technique is used for very high or laterally displaced impactions, accessory frena can be created in the vertical incision area, and orthodontic relapse has been observed in some patients.

The flap closed-eruption technique usually produces the best gingival esthetics.¹⁷

Two potential problems can arise with the flap closed-eruption technique if it is employed improperly. First, debonding of the bracket or chain can occur if proper isolation and bonding techniques are not used. Second, if improper orthodontic mechanics are used, a mucogingival problem can result. If the tooth erupts through mucosa or too near the mucogingival junction, it may have inadequate attached gingiva. This problem can be eliminated by properly using the Ballista spring to erupt the tooth through the mid-crestal area. When

used properly, this technique mimics the normal eruptive pattern, eliminates potential recession, and leaves an adequate zone of attached gingiva.

The preorthodontic uncovering technique for palatally impacted canines has proved to be an excellent technique. Compared with other approaches, it requires considerably less time for the orthodontist to move the tooth into its proper location. It is also less traumatic to the teeth used for anchorage to erupt the tooth. There are also fewer instances of damage to the roots of adjacent teeth.

The problems with the preorthodontic uncovering technique center around postsurgical sequelae. The postoperative healing period is slower and more uncomfortable. Some teeth require deep, broad, scalloping of the palatal flap, and this type of surgical procedure can lead to bleeding problems during surgery and the postoperative period. Teeth in the "gray area" (*i.e.*, higher in the roof of the palate and more deeply embedded) are more difficult to keep uncovered during the first few weeks. Sometimes they require degranulation of the tissue margins and replacement of the dressing until the tissue epithelializes. Most importantly, if bone is not properly removed from the crown of the tooth, the tooth will not erupt.

Some teeth are so deeply impacted that even if they can be uncovered, there is no possible orthodontic means to erupt them. There are times when it is preferable to extract the tooth than to create unnecessary surgical and orthodontic trauma. These situations usually can be diagnosed with proper records and consultation with the orthodontist.

It is the surgeon's responsibility to make detailed notes about the nature of the impacted tooth and its position and to take appropriate photographs. This information will assist the orthodontist in his/her efforts to erupt the tooth and will greatly facilitate the treatment.

LITERATURE CITED

1. Bass T. Observation on the misplaced upper canine tooth. *Dent Practitioner* 1967;18:25.
2. Witsenberg B, Boering G. Eruption of impacted permanent upper incisors after removal of supernumerary teeth. *Int J Oral Surg* 1981;10:423-431.
3. Vanarsdall RL, Corn H. Soft-tissue management of labially positioned unerupted teeth. *Am J Orthod* 1977;72:53-64.
4. Johnston WD. Treatment of palatally impacted canine teeth. *Am J Orthod* 1969;56:589-96.
5. Boyd RL. Clinical assessment of injuries in orthodontic movement of impacted teeth. II. Surgical recommendations. *Am J Orthod* 1984;86:407-18.
6. Richards A. The buccal object rule. *Dent Radiogr Photog* 1980;55:3.

7. Fournier A, Turcotte JY, Bernard C. Orthodontic considerations in the treatment of maxillary impacted canines. *Am J Orthod* 1982;81:236-9.
8. Hunter S. Treatment of the unerupted maxillary canine. *Br Dent J* 1983;154:294-296.
9. Wong-Lee TK, Wong FC. Maintaining an ideal tooth-gingiva relationship when exposing and aligning an impacted tooth. *Br J Orthod* 1985;12:189-92.
10. Magnusson H. Saving impacted teeth. *J Clin Orthod* 1990;24:246-9.
11. Abrams H, Gossett S, Morgan W. A modified flap design in exposing the palatally impacted canine. *J Dent Child* 1988;55:285-287.
12. Smukler H, Castellucci G, Goldman H. Surgical management of palatally impacted cuspids. *Compend Cont Educ Dent* 1987;8:10-17.
13. Montelius G. Impacted teeth. A comparative study of Chinese and Caucasian dentitions. *J Dent Res* 1932;12:931-938.
14. Johnsen D. Prevalence of delayed emergence of permanent teeth as a result of local factors. *J Am Dent Assoc* 1977;94:100-106.
15. Grover P, Lorton L. The incidence of unerupted permanent teeth and related clinical cases. *Oral Surg* 1985;59:420-424.
16. Ranalli D, Buzzato J, Braun T, Jones R, Smith P. Long-term interdisciplinary management of multiple mesiodens and delayed eruption: Report of case. *J Dent Child* 1988;55:376-380.
17. Cangialosi TJ, Meistrell ME, Jr. A cephalometric evaluation of hard- and soft-tissue changes during the third stage of Begg treatment. *Am J Orthod* 1982;81:124-9.