

28

# Orthodontic Therapy for the Periodontal- Restorative Patient

*Vincent G. Kokich and Vincent O. Kokich*

## **ORTHODONTIC MANAGEMENT OF GINGIVAL DISCREPANCIES**

- Uneven Gingival Margins
- Significant Abrasion and Overeruption
- Open Gingival Embrasures

## **ORTHODONTICS AND THE IMPLANT PATIENT**

- Congenitally Missing Second Premolars
- Congenitally Missing Lateral Incisors
- Implant Anchorage during Orthodontics

## **ORTHODONTIC MANAGEMENT OF OSSEOUS DEFECTS**

- Hemiseptal Defects
- Advanced Horizontal Bone Loss
- Furcation Defects
- Root Proximity
- Fractured Teeth/Forced Eruption
- Hopeless Teeth

## **CONCLUSION**

Orthodontic tooth movement may be a substantial benefit to the adult periorestorative patient. Many adults who seek routine restorative dentistry have problems with tooth malposition that compromise their ability to clean and maintain their dentitions. If these individuals also are susceptible to periodontal disease, tooth malposition could be an exacerbating factor that could cause premature loss of specific teeth. Orthodontic appliances have become smaller, less noticeable, and easier to maintain during orthodontic therapy. Many adults are seeking orthodontic therapy to improve the esthetics of their smile. If these individuals also have underlying gingival or osseous defects, these problem areas often can be improved during orthodontic therapy. In addition, implants have now become a primary method of tooth replacement for patients with congenitally absent, previously extracted, or hopeless teeth. In some of these situations, there is insufficient bone to support the implant. In other situations, adjacent teeth may have drifted into the implant space preventing proper placement of the implant. Orthodontic therapy not only can create sufficient space for the implant, but strategic tooth movement can result in implant site development to create sufficient bone for the implant and to avoid surgical ridge augmentation. However, the orthodontist must be aware of these situations and design the appropriate tooth movement for all of these adjunctive procedures. The purpose of this chapter is to illustrate how orthodontic therapy can enhance the periodontal health and restorability of teeth and implants.

#### ORTHODONTIC MANAGEMENT OF GINGIVAL DISCREPANCIES

##### Uneven Gingival Margins

The relative level of the gingival margins of the six maxillary anterior teeth plays an important role in the esthetic appearance of the crowns.<sup>1,2</sup> Four characteristics contribute to ideal gingival form. First, the gingival margins of the two central incisors should be at the same level or within 1 mm of the same level. Research has shown that lay people will regard a 1.5-mm discrepancy between central incisors as unesthetic.<sup>3</sup> Second, the gingival margins of the central incisors should be positioned more apically than the lateral incisors and should be at the same level as the canines.<sup>4</sup> Third, the contour of the labial gingival margins should mimic the contour of the cemento-enamel junctions (CEJs) of the teeth. Last, there should be a papilla between each tooth, and the height of the tip of the papilla is usually halfway between the incisal edge and the labial gingival height of contour over the center of each anterior tooth. Therefore, the gingival papilla occupies half of the

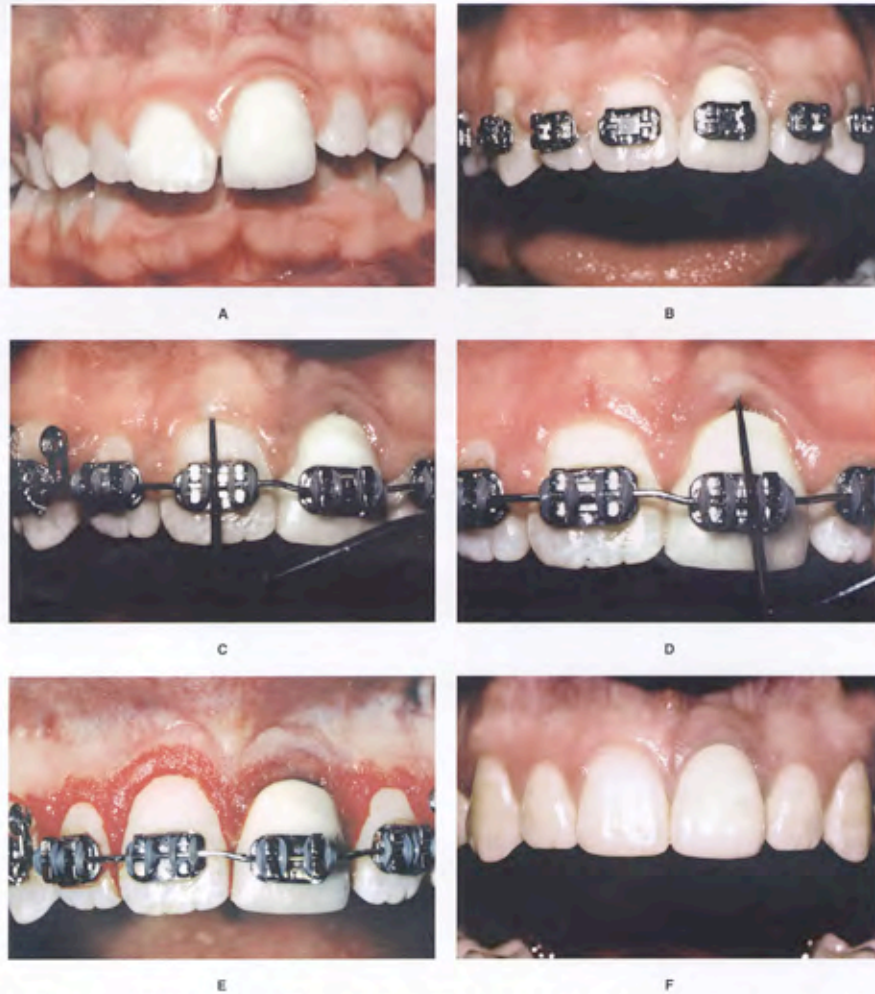
interproximal contact space, and the adjacent teeth form the other half of the contact.

However, some patients may have gingival margin discrepancies between adjacent teeth (Figs. 28-1 and 28-2). These discrepancies could be caused by abrasion of the incisal edges or delayed migration of the gingival margins. When gingival margin discrepancies are present, the clinician must determine the proper solution for the problem: orthodontic movement to reposition the gingival margins or surgical correction of gingival margin discrepancies.

To make the correct decision, it is necessary to evaluate four criteria.<sup>5</sup> First, the relation between the gingival margin of the maxillary central incisors and the patient's lip line should be assessed when the patient smiles. If a gingival margin discrepancy exists, but the patient's lip does not move upward to expose the discrepancy, it often does not require correction. If a gingival margin discrepancy is apparent, the next step is to evaluate the labial sulcular depths of the two central incisors. If the shorter tooth has a deeper sulcus, excisional gingivectomy may be appropriate to move the gingival margin of the shorter tooth apically (Fig. 28-1). However, if the sulcular depths of the short and long incisors are equivalent, and the CEJ is at the depth of the sulcus, gingival surgery may not be appropriate, because it could expose the cementum of the shorter tooth.

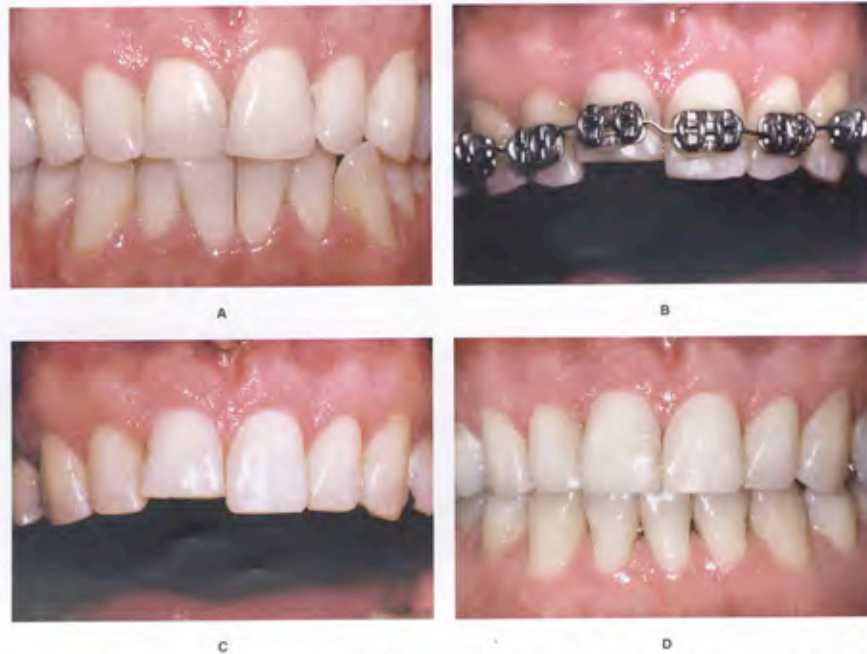The third step is to evaluate the relation between the shortest central incisor and the adjacent lateral incisors. If the shortest central incisor is still longer than the lateral incisors, the other possibility is to extrude the longer central incisor and equilibrate the incisal edge. This will move the gingival margin coronally and eliminate the gingival margin discrepancy. However, if the shortest central were shorter than the lateral incisors (Fig. 28-2), this technique would produce an unesthetic relation between the gingival margins of the central and lateral incisors.

The fourth step is to determine if the incisal edges have been abraded. This is best appreciated by evaluating the teeth from an incisal perspective. If one incisal edge is thicker labiolingually than the adjacent tooth, this may indicate that it has been abraded and the tooth has over-erupted. In addition, if the incisal edge has a yellow or brown central region, this could indicate abrasion into the dentin of the tooth. In these situations, the best method of correcting the gingival margin discrepancy is to intrude the short central incisor (Fig. 28-2). This method will move the gingival margin apically and allow restoration of the incisal edges. The intrusion should be accomplished at least 6 months before appliance removal. This allows reorientation of the principal fibers of the periodontium and avoids reextrusion of the central incisor(s) after appliance removal.<sup>6</sup>



**Figure 28-1.** This patient had fallen and injured the maxillary left central incisor. Root canal therapy was performed and a crown had been placed on the tooth (A). The original discrepancy in crown lengths between right and left central incisors (A and B) did not improve during orthodontic alignment. Periodontal probing showed that the sulcus depth over the right central incisor (C) was greater than over the left central (D). The diagnosis was altered passive eruption, and gingivectomy was performed to level the margins (E). The final crown on the left central now matches the length of the non-restored right central incisor. Enameloplasty was performed on teeth #7, 8, and 10 (F). A gingivectomy approach was possible in this case because the distance from the cemento-enamel junction to the crest of the bone was 3 mm on all incisors; thus, use of a gingivectomy did not violate the biologic width.





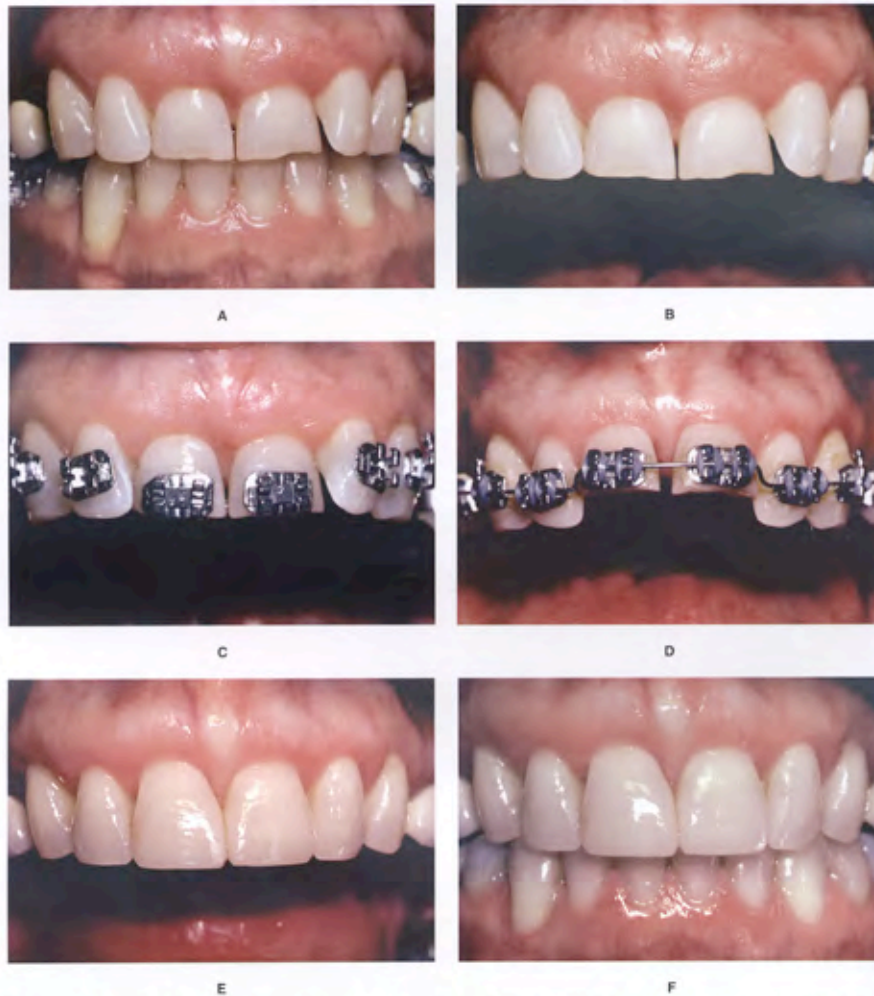
**Figure 28-2.** This patient had a protrusive brushing habit that had resulted in abrasion and overeruption of the maxillary right central incisor (A). The objective was to level the gingival margins during orthodontic therapy. Although gingival surgery was a possibility, the labial sulcular depth of the maxillary right central incisor was only 1 mm, and the cementoenamel junction was located at the bottom of the sulcus. Therefore, the best solution involved positioning the orthodontic brackets to facilitate intrusion of the right central incisor (B). The right central incisor has been intruded (C), permitting the restorative dentist to restore the portion of the tooth that the patient had abraded (D), resulting in the correct gingival margin levels and crown lengths at the end of treatment.

#### Significant Abrasion and Overeruption

Occasionally, patients will have destructive dental habits such as a protrusive brushing habit that could result in significant wear of the maxillary and mandibular incisors (Fig. 28-3) and compensatory overeruption of these teeth. When the restorative dentist contemplates restoration of these abraded teeth, it is often impossible, because of the lack of crown length, to achieve adequate retention and resistance form for the crown preparations.<sup>5</sup> Two options are available. One option is extensive crown lengthening by elevating a flap, removing sufficient bone, and apically positioning the flap to expose adequate tooth length for crown preparation. However, this type of procedure is contraindicated in the patient with short tapered roots,

because it could adversely affect the final root-to-crown ratio, and it could potentially result in “black triangles” or open gingival embrasures between the anterior teeth.

The other option for improving the restorability of these short abraded teeth is to orthodontically intrude the teeth and move the gingival margins apically (Fig. 28-3). It is possible for the orthodontist to intrude as many as four maxillary incisors by using the posterior teeth as anchorage during the intrusion process. This process is accomplished by placing the orthodontic brackets as close to the incisal edges of the maxillary incisors as possible. The brackets are placed in their normal position on the canines and remaining posterior teeth. The patient’s posterior occlusion will resist the eruption of the posterior



**Figure 28-3.** This patient had a protrusive brushing habit that had caused severe abrasion of both maxillary central incisors, resulting in loss of more than half of the crown length of these teeth (A and B). Two possible options existed for gaining crown length to restore the central incisors. One possibility was an apically positioned flap with osseous recontouring, which would expose the roots of the teeth. The less invasive option was to intrude the central incisors orthodontically, level the gingival margins (C and D), and allow the dentist to restore the abraded incisal edges (E and F). The orthodontic option was clearly successful and desirable in this patient.

teeth, and the incisors will gradually intrude and move the gingival margins and the crowns apically. This creates the restorative space necessary to temporarily restore the incisal edges of these teeth (Fig. 28-3) and to eventually place the final crowns.

When abraded teeth are intruded significantly, it is necessary to hold these teeth for at least 6 months in the intruded position with the orthodontic brackets and/or archwires, or some sort of bonded retainer. The principal fibers of the periodontium must accommodate to the new intruded position,<sup>6</sup> and this process could take a minimum of 6 months in most adult patients. Orthodontic intrusion of severely abraded and overerupted teeth is usually a distinct advantage over periodontal crown lengthening, unless the patient has extremely long and broad roots or has had extensive horizontal bone loss.

#### Open Gingival Embrasures

The presence of a papilla between the maxillary central incisors is a key esthetic factor in any individual.<sup>7,8</sup> Occasionally, adults will have open gingival embrasures or black triangles between their central incisors. These unsightly areas often are difficult to resolve with periodontal therapy. However, orthodontic treatment can correct many of these open gingival embrasures, even in some adult periodontal patients. This space is usually due to one of three factors: tooth shape, root angulation, or periodontal bone loss.<sup>9</sup>

The interproximal contact between the maxillary central incisors consists of two parts: one portion is the tooth contact, and the other portion is the papilla. The papilla-to-contact ratio is about 1:1; in other words, half the space is occupied by papilla and half is formed by the tooth contact.<sup>9</sup> If the patient has an open embrasure, the first aspect that the clinician should evaluate is whether the problem is caused by the papilla or the tooth contact. If the papilla is the problem, then the cause is usually a lack of bone support caused by an underlying periodontal osseous defect.

In some situations, a deficient papilla can be lengthened slightly with orthodontic treatment. By closing open contacts, the orthodontist can squeeze the interproximal gingiva and move it incisally. This type of movement can help to create a more esthetic papilla between two teeth despite alveolar bone loss. Another possibility is to erupt adjacent teeth when the interproximal bone level is positioned apically.

Most open embrasures between the central incisors are caused by problems with tooth contact. The first step in the diagnosis of this problem is to evaluate a periapical radiograph of the central incisors. If the root angulation is divergent (Fig. 28-4), then the brackets should be positioned so the root position can be corrected. In these situations, the incisal edges may be uneven and require restoration with either composite or porcelain restorations.

If the periapical radiograph shows that the roots are in their correct relation, then the open gingival embrasure is because of triangular tooth shape.

If the shape of the tooth is the problem, two solutions are possible: one possibility is to restore the open gingival embrasure; the other option is to reshape the tooth (Fig. 28-5), by flattening the incisal contact and then closing the space orthodontically. This will result in lengthening of the contact until it meets the papilla. In addition, if the embrasure space is large, closing the space will squeeze the papilla between the central incisors. This will help to create a 1:1 relation between the contact and papilla, and will restore uniformity to the heights between the midline and adjacent papillae.

#### ORTHODONTICS AND THE IMPLANT PATIENT

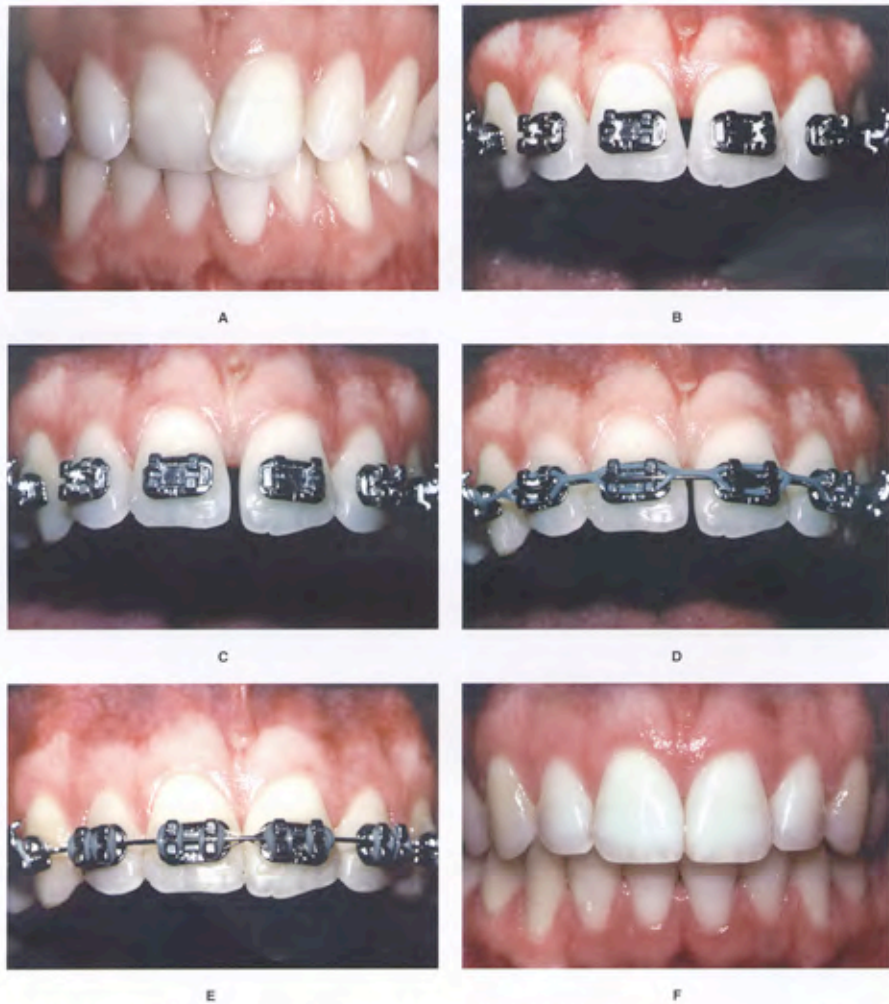Implants are routinely used in dentistry. In some situations, orthodontic intervention could be advantageous to enhance the outcome of implant therapy. Three situations could require interaction between the orthodontist and the implant surgeon. First, implants are used commonly to replace congenitally missing teeth in adolescent orthodontic patients. In some of these patients, there is insufficient space for the implant, and the orthodontist must create the appropriate space for the surgeon. Second, there may be insufficient thickness of alveolar bone to house the implant. These situations could require alveolar bone grafting to create enough buccolingual width for the implant. However, strategic orthodontic movement of adjacent teeth also could create the necessary thickness of the alveolar ridge. Third, implants could be used as abutments for orthodontic anchorage. The orthodontist and implant surgeon must collaborate not only on the precise placement of the implant, but also the timing of implant placement.

#### Congenitally Missing Second Premolars

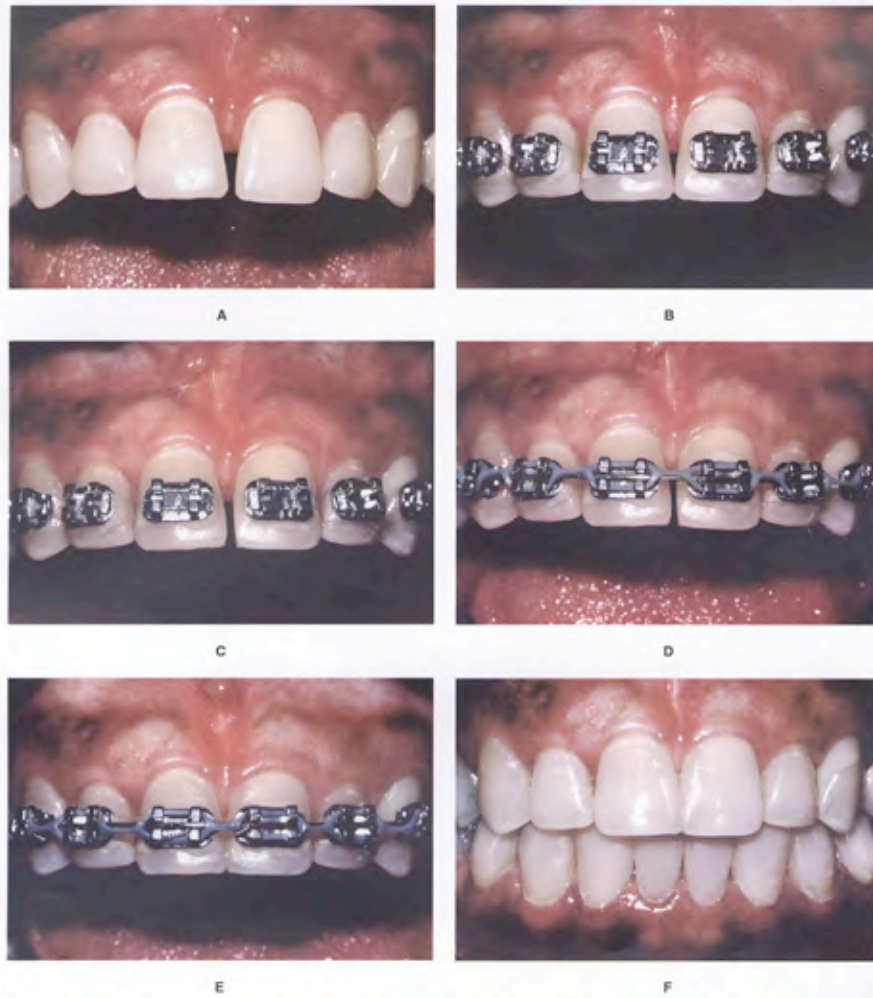
Often adolescent patients are congenitally missing mandibular second premolars. If the patient does not have an arch length deficiency with a satisfactory profile, extraction of teeth and space closure may be disadvantageous. In these situations, the space from the congenitally missing premolars must be maintained and restored with either a bridge or an implant.

If an implant is planned for the congenitally missing mandibular second premolar, the space and bone support must be monitored and maintained.<sup>10</sup> It is ideal to allow the mandibular primary molar to remain in position as long as possible to maintain the bone support. However, the primary molar may be too wide (mesiodistally) to occlude properly with the opposing dentition (Fig. 28-6). In this situation, it may be advantageous to reduce the width of the primary molar so it approximates the width of a second premolar (Fig. 28-6).



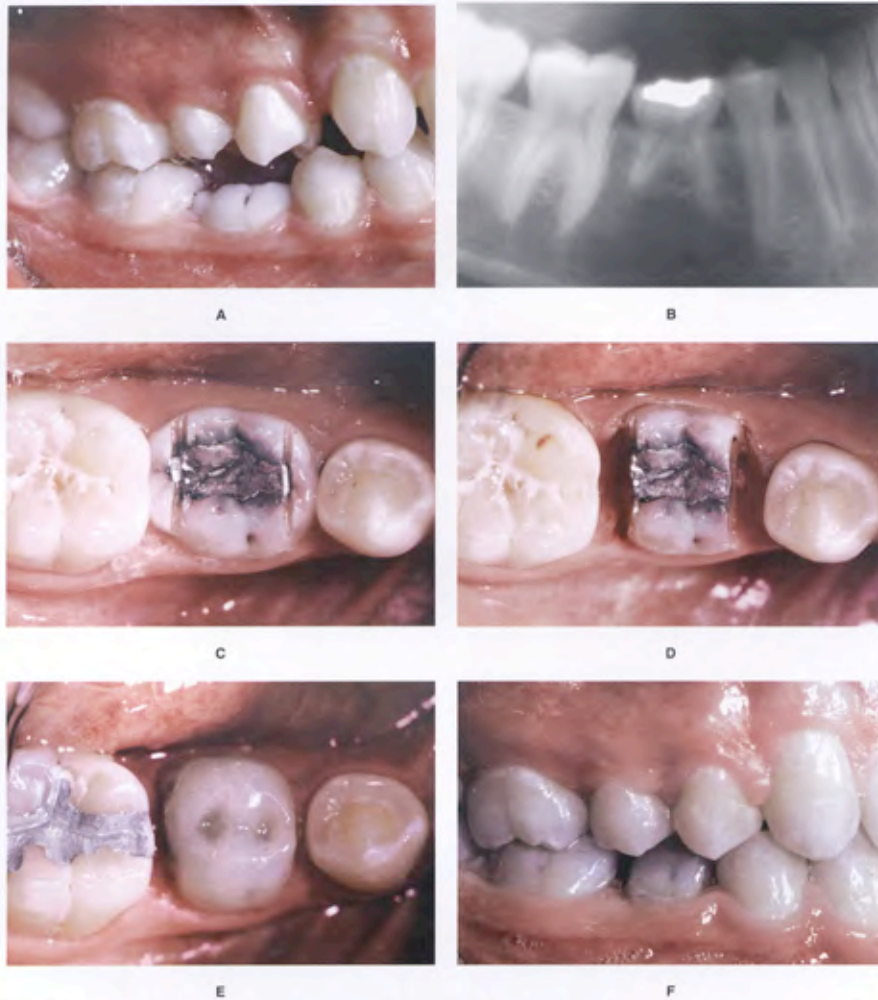


**Figure 28-4.** This patient initially had overlapped maxillary central incisors (A), and after initial orthodontic alignment of the teeth, an open gingival embrasure appeared between the central incisors (B). Because the roots had been aligned already, the correct option for closing the open gingival embrasure was to reshape the mesial surfaces of the central incisors (C). This created a diastema between these teeth (D), which was closed orthodontically (E). Because the incisal edges of these teeth had worn unevenly before orthodontics, they required restoration after orthodontics (F).



**Figure 28-5.** This patient initially had triangular-shaped central incisors (A), which produced an open gingival embrasure after orthodontic alignment (B). Because the roots of the central incisors were parallel with one another, the appropriate solution for the open gingival embrasure was to recontour the mesial surfaces of the central incisors (C). As the diastema was closed (D and E), the tooth contact moved gingivally, and the papilla moved incisally, resulting in the elimination of the open gingival embrasure (F).





**Figure 28-6.** The mandibular right second premolar was congenitally missing (A), but the primary molar was still present (B). This young adolescent patient would eventually receive an implant after she completed facial growth, but the mesiodistal width of the primary molar was much larger than the missing premolar. Therefore, the primary molar crown was reduced in width to approximate the size of a premolar (C and D). To cover the exposed dentin, the primary molar was restored with a composite buildup approximately the size of a premolar crown (E). With the reduction in mesiodistal width, the primary molar could be fit into the correct occlusal relation with the maxillary arch (F) and remain in position and maintain the alveolar bone until facial growth is complete and the implant can be placed.

After reduction of the primary molar, it is advantageous to cover the exposed dentin on the mesial and distal surfaces. This can be accomplished with a light-cured composite (Fig. 28-6). Then the composite restoration may be trimmed to simulate the shape and size of a mandibular premolar. In this way, the primary molar may be bracketed and remain in position to maintain the alveolar bone before implant placement.

The age for implant placement in adolescent boys and girls is completely dependent on the completion of facial growth.<sup>11</sup> As the mandibular ramus continues to grow, the posterior teeth erupt. If an implant is placed too early, before growth is completed, it will mimic an ankylosed tooth and become submerged in the alveolus. This could cause a periodontal defect between the implant and adjacent teeth. The most precise method for determining if facial or ramal growth is completed is to superimpose sequential cephalometric radiographs. If growth is continuing, the distance between nasion and menton will continue to increase, indicating that it is too early to place the implant. The implant should not be placed until there is no change in facial vertical dimension taken on two head films 1 year apart. In general, implants should not be placed in boys until after 21 years of age and in girls until after 17 years of age.<sup>11</sup>

If an ankylosed primary molar is not extracted early, and a vertical ridge defect is produced, an option to improve the implant site and eliminate the defect is to move the mandibular first premolar into the second premolar position<sup>10</sup> and to place the implant in the first premolar position (Fig. 28-7). Previous studies have shown that it is possible, within limits, to move a tooth into a narrower edentulous ridge<sup>12,13</sup> to create an implant site. The bone that is created behind the moving tooth typically will be the width of the root of the tooth that was moved.<sup>10</sup> This type of orthodontic movement may eliminate the need for a bone graft in the edentulous site. This type of tooth movement is called orthodontic implant site development.

#### **Congenitally Missing Lateral Incisors**

Another common congenitally missing tooth is the maxillary lateral incisor. A primary factor that the orthodontist must be aware of is the amount of mesiodistal space that should be created for the lateral incisor implant.<sup>14</sup> First, if a contralateral incisor is present, the space for the missing lateral incisor crown should match the width of the natural lateral incisor. In general, this space should be at least 5.5 mm in width. If the contralateral lateral incisor is malformed or peg-shaped and is smaller than 5.5 mm, then the crown should be built up to a width that is 67% to 75% the width of the central incisor. The width of most central incisors ranges from 8 to 10 mm. Therefore, the width of the lateral incisor implant crown should range from about 5.5 to 7.0 mm.

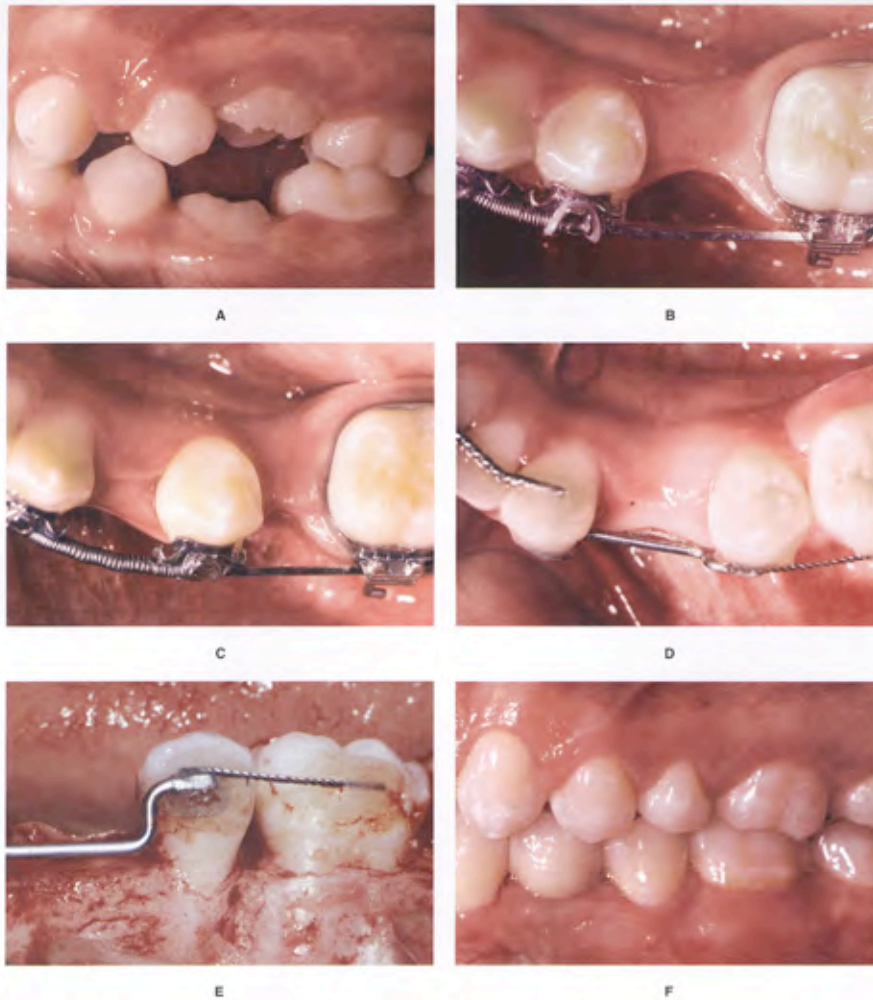
The width of the edentulous space should allow at least 1 mm between the implant and the adjacent teeth. If the distance between implant and tooth is less than 1 mm, the interproximal bone could be jeopardized,<sup>14,15</sup> and the space for the papilla between the implant crown and the adjacent teeth will be constricted and could appear much shorter than the contralateral papillae.<sup>15</sup> This will make the implant crown more obvious and appear less esthetic.

The space between the roots of the adjacent central incisor and canine must be sufficient to permit placement of the implant (Fig. 28-8). As space is created between a central incisor and canine by pushing the crowns apart, the roots tend to move toward one another. This root proximity must be corrected before implant placement. This type of tooth movement is accomplished by progressively bending the archwires to move the apices of the roots in opposite directions.

The labiolingual dimension of the alveolar ridge must be wide enough to place the implant in its proper position. If insufficient ridge width exists, a bone graft may be necessary before or during implant placement. However, a bone graft can be avoided if the central incisor and canine erupt adjacent to one another (Fig. 28-9). As the space is opened orthodontically for the future implant, bone is laid down along fiber tracks of the periodontal membrane. The labiolingual width of the alveolar ridge formed in this manner is generally stable over time. Therefore, if implant placement is delayed until an adolescent has completed facial growth, the ridge will not become narrower.

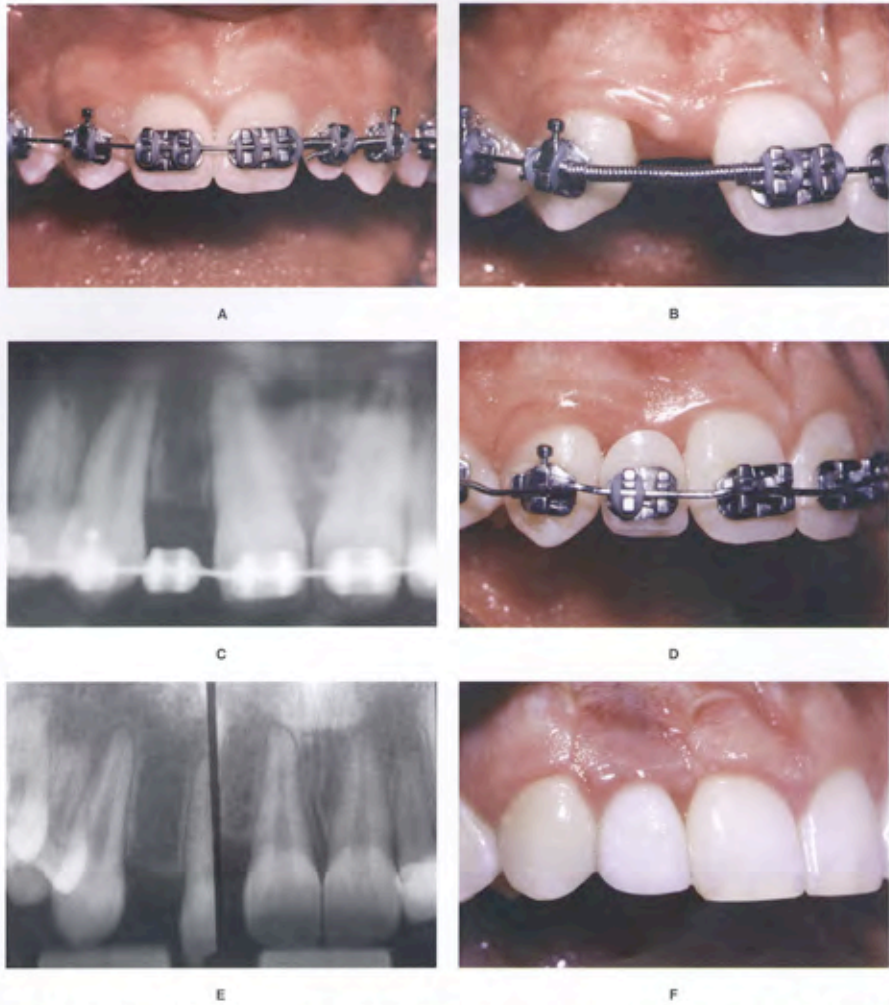
#### **Implant Anchorage during Orthodontics**

Occasionally, adult orthodontic patients may be missing several teeth. This could be a problem for the orthodontist, because adjacent teeth are necessary to provide the reciprocal anchorage necessary for orthodontic tooth movement. In these situations, if implants will be used to restore the edentulous spaces anyway, the implants could be placed before orthodontics<sup>16,17</sup> and used initially as an anchor to facilitate tooth movement, and then as a restorative abutment to restore the edentulous space (Fig. 28-10). In this situation, careful planning and collaboration are necessary between the orthodontist and implant surgeon to position the implant properly. A diagnostic wax-up is mandatory, because the implant is placed before orthodontic procedures are begun. The orthodontist must construct the set-up using specific guidelines that will simulate the eventual tooth movement. Then a plastic placement guide is constructed from the wax-up to provide the surgeon with the precise location of the implant. By locating the implant in this manner, it will be in the correct position not only for the orthodontist, but also for the restorative dentist.

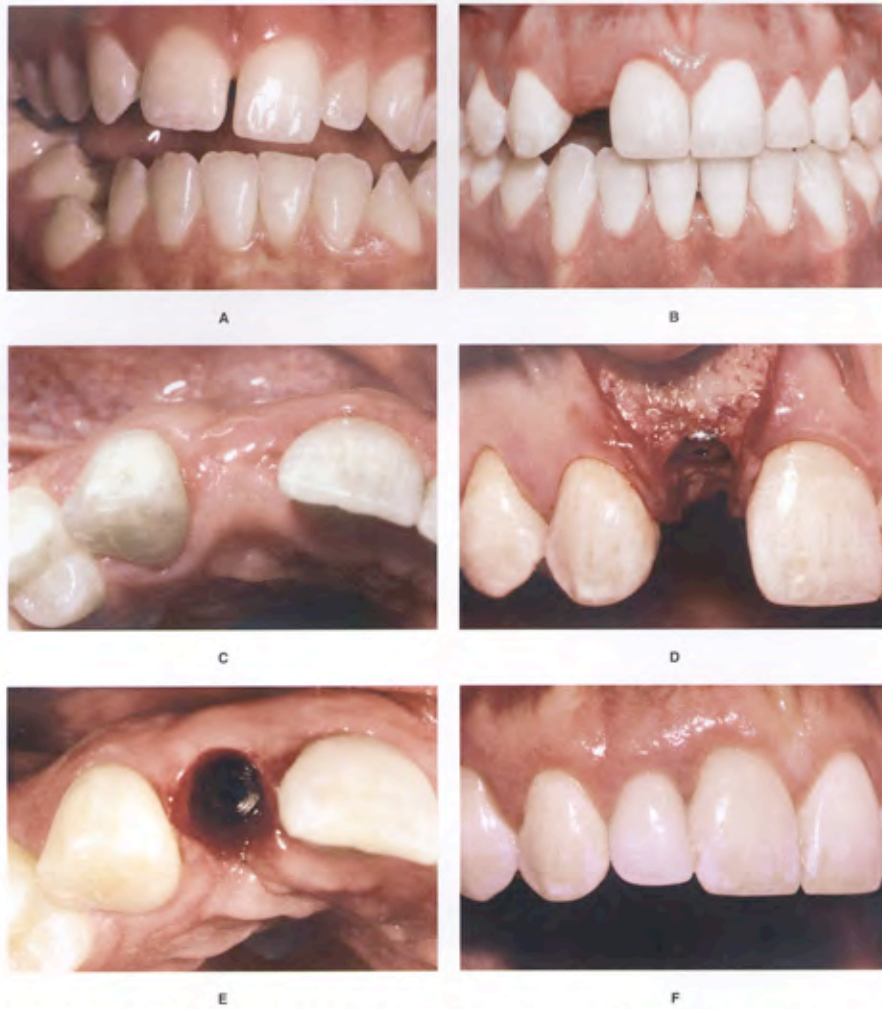

**Figure 28-7.** The mandibular left second premolar was congenitally missing, and the primary molar was ankylosed and submerged (A). After extraction of the primary second molar, the alveolar ridge narrowed significantly (B), and there was insufficient thickness of bone for an implant. To increase the ridge thickness and avoid a bone graft, the mandibular first premolar was moved distally (C and D). When a flap was elevated to place an implant, there was adequate bone in the implant site and also over the root of the first premolar (E), which permitted placement of the implant without the need for a bone graft (F).

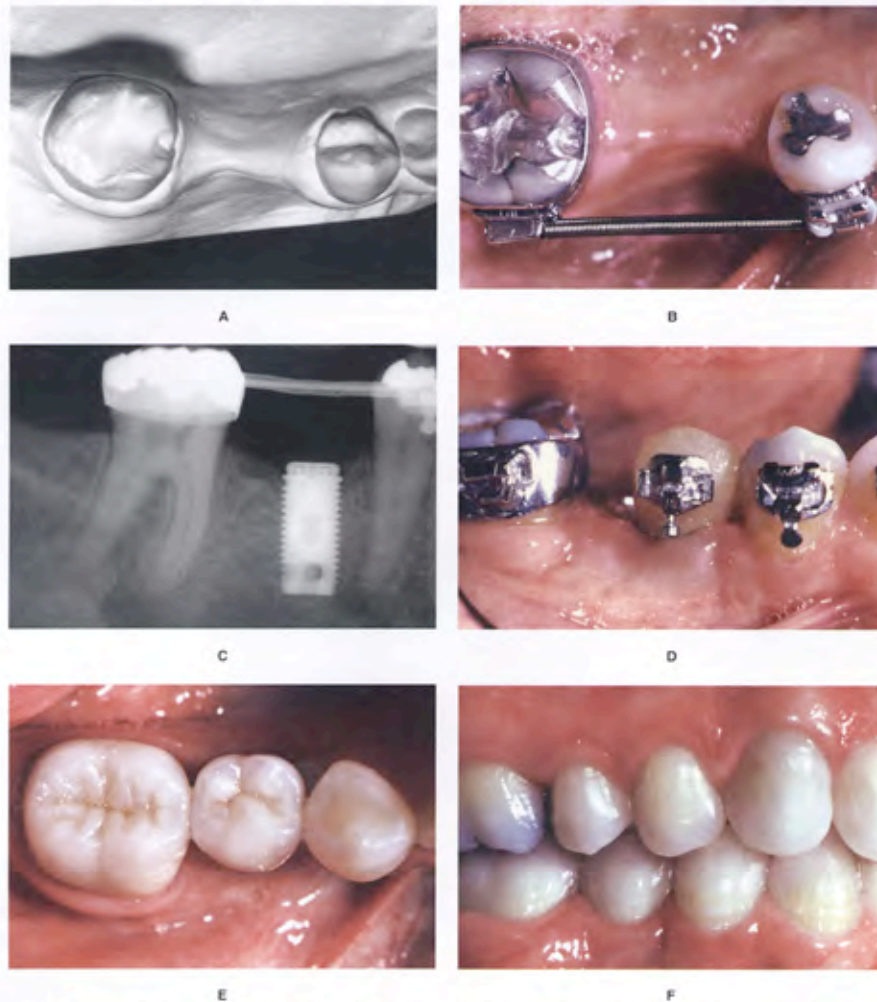




**Figure 28-8.** This patient was congenitally missing the maxillary right lateral incisor (A). As space was opened for the missing tooth, the roots moved toward one another as the crowns moved apart (B and C). The arch wire was adjusted to tip the roots apart (D) to create space for the implant (E). When sufficient space exists for an implant, gingival esthetics will be enhanced around the implant (F).



**Figure 28-9.** Implant site development is a method of creating alveolar bone in which to place an implant. This is especially important in the esthetic zone. This patient is congenitally missing the maxillary right lateral incisor, but fortunately the canine erupted into the lateral position (A). This is ideal, because as the orthodontist moves the central incisor and canine apart (B) to open space for the lateral incisor implant, alveolar bone is created in the path of the tooth movement (C). This provides an ideal ridge in which to position the implant (D and E), to maximize the esthetic result when the crown is seated on the implant (F).



**Figure 28-10.** Implants can be used for orthodontic anchorage. This patient was missing the mandibular right second premolar and first molar (A). Part of the space had closed. There was not enough space for two teeth, and too much space for a one-tooth prosthesis. Because implants were chosen as the method of restoration, the teeth were initially aligned (B), and an implant was placed in the position of the future second premolar (C). Then a provisional crown and bracket were placed on the implant (D). The implant was used as an anchor to drag the second molar mesially, without affecting the position of the first premolar. After orthodontic treatment, the same implant was restored as a second premolar (E and F).



### ORTHODONTIC MANAGEMENT OF OSSEOUS DEFECTS

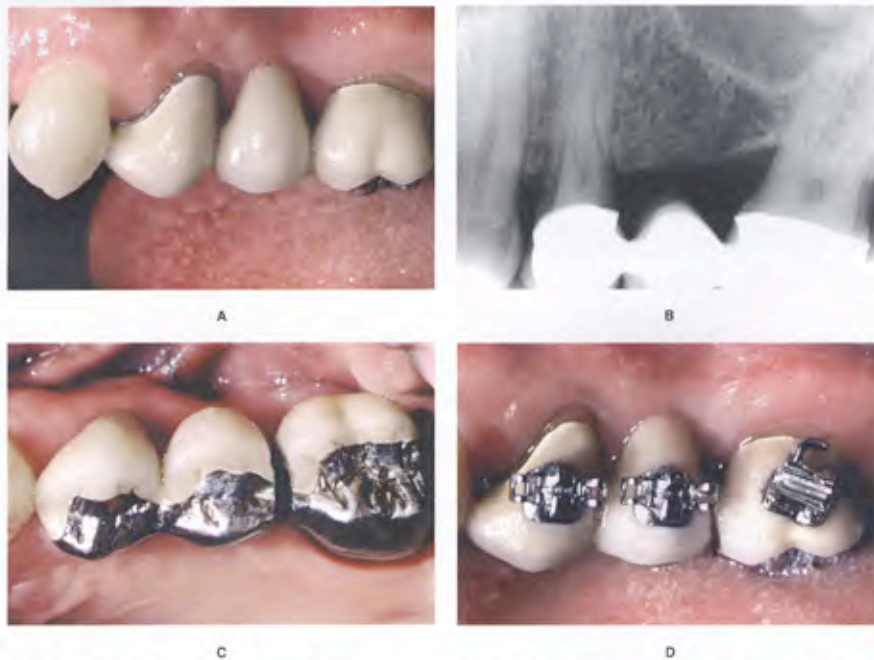#### Hemiseptal Defects

Hemiseptal defects are one-wall osseous defects. Often these are found around mesially tipped teeth (Fig. 28-11) or teeth that have supraerupted. Usually these defects can be eliminated with the appropriate orthodontic treatment. In the case of the tipped tooth, uprighting<sup>18,19</sup> and eruption of the tooth will level the bony defect (Fig. 28-11). In the case of the supraerupted tooth, intrusion and leveling of the adjacent CEJs can help to level the osseous defect.

*It is imperative that periodontal inflammation be controlled before orthodontic treatment.* This usually can be achieved with initial debridement and rarely requires any preorthodontic surgery. After the completion of orthodontic

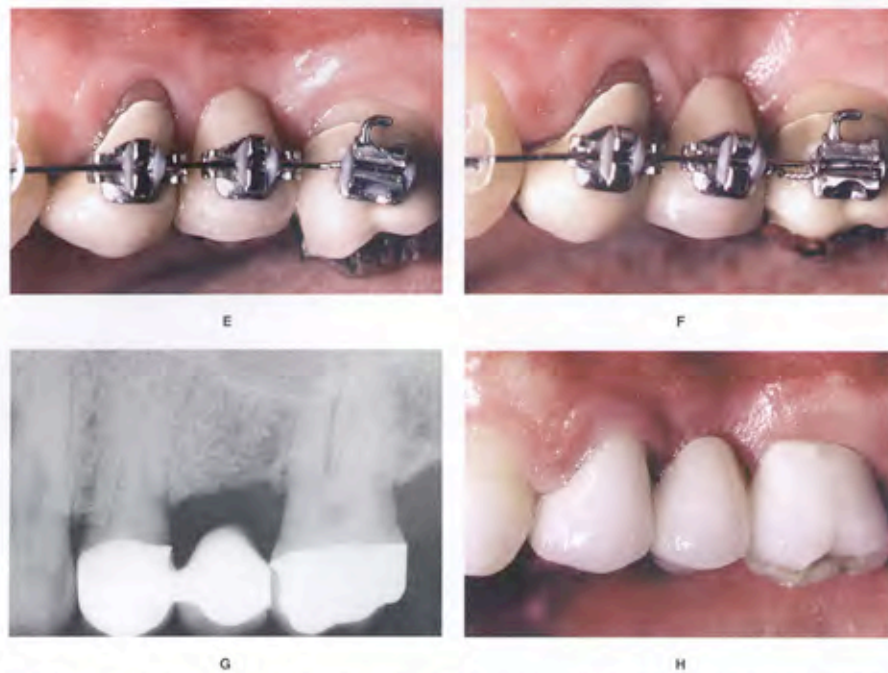
treatment, these teeth should be stabilized for at least 6 months and reassessed periodontally. Often the pocket has been reduced or eliminated and no further periodontal treatment is needed. It would be injudicious to do preorthodontic osseous corrective surgery in lesions such as these if orthodontics is a part of the overall treatment plan.

In the periodontally healthy patient, orthodontic brackets are positioned on the posterior teeth relative to the marginal ridges and cusps. However, some adult patients may have marginal ridge discrepancies caused by uneven tooth eruption during orthodontic treatment. When the orthodontist encounters marginal ridge discrepancies, the decision where to place the bracket or band is not determined by the anatomy of the tooth. In these situations, it is important for the orthodontist to assess bitewing or



**Figure 28-11.** This patient was missing the maxillary left second premolar and first molar. The second molar on that side had tipped mesially and had been used as a fixed partial denture abutment connecting the first premolar and second molar (A). A radiograph (B) confirmed the hemiseptal periodontal defect on the mesial of the second molar abutment, which was associated with a 7 mm pocket. Orthodontics was used to erupt this tooth and eliminate the defect. The pontic was sectioned (C), and a bracket was placed at an angle on the tipped molar abutment (D).

Continued



**Figure 28-11. cont'd** As the tooth erupted (E), the mesial marginal ridge of the second molar extended coronal to the occlusal plane. The marginal ridge was equilibrated (F). The radiograph shows the positive effect that orthodontics has on leveling the periodontal defect (G), and providing for a better fixed partial denture restoration for the patient (H).

periapical radiographs of these teeth to determine the interproximal bone level.<sup>47</sup>

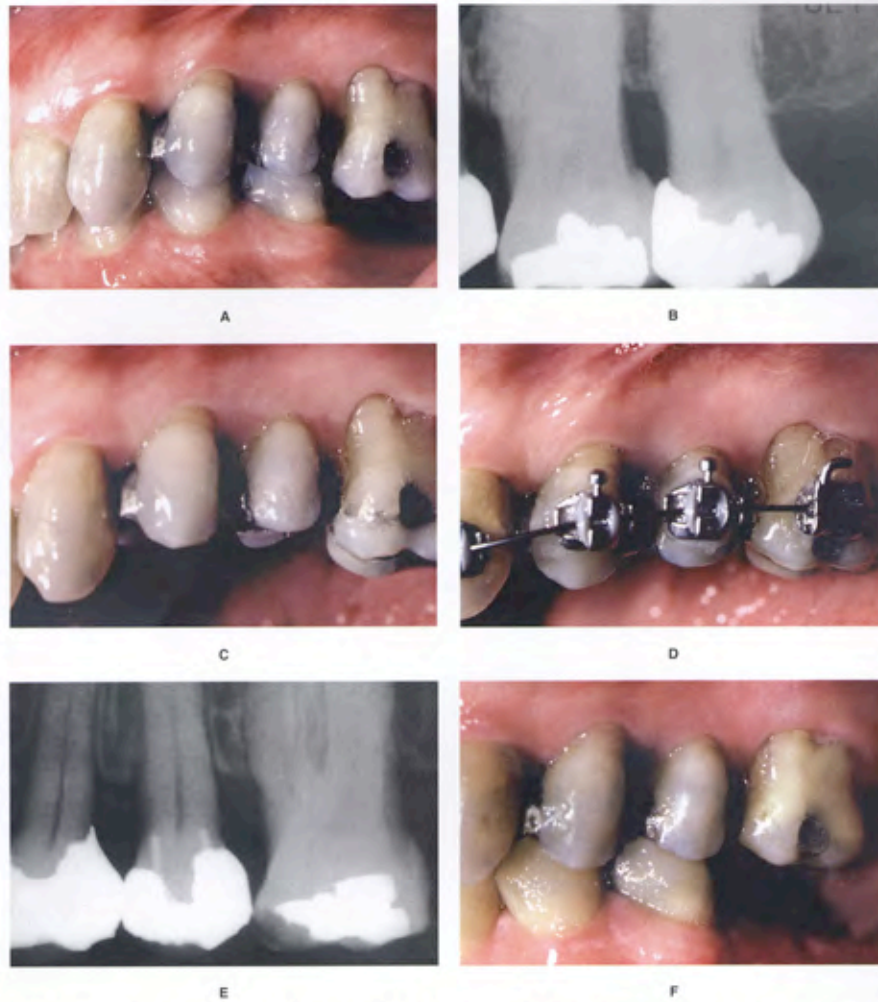
If the bone level is oriented in the same direction as the marginal ridge discrepancy, then leveling the marginal ridges will level the bone. However, if the bone level is flat between adjacent teeth, and the marginal ridges are at significantly different levels, correction of the marginal ridge discrepancy orthodontically will produce a hemiseptal defect in the bone. This could cause a periodontal pocket between the two teeth.

If the bone is flat and a marginal ridge discrepancy is present (Fig. 28-12), the orthodontist should not level the marginal ridges orthodontically. In these situations, it may be necessary to equilibrate the crown of the tooth. For some patients, the latter technique may require endodontic therapy and restoration of the tooth because of the amount of reduction of the length of the crown that is required. This

approach is acceptable if the treatment results in a more favorable bone contour between the teeth.

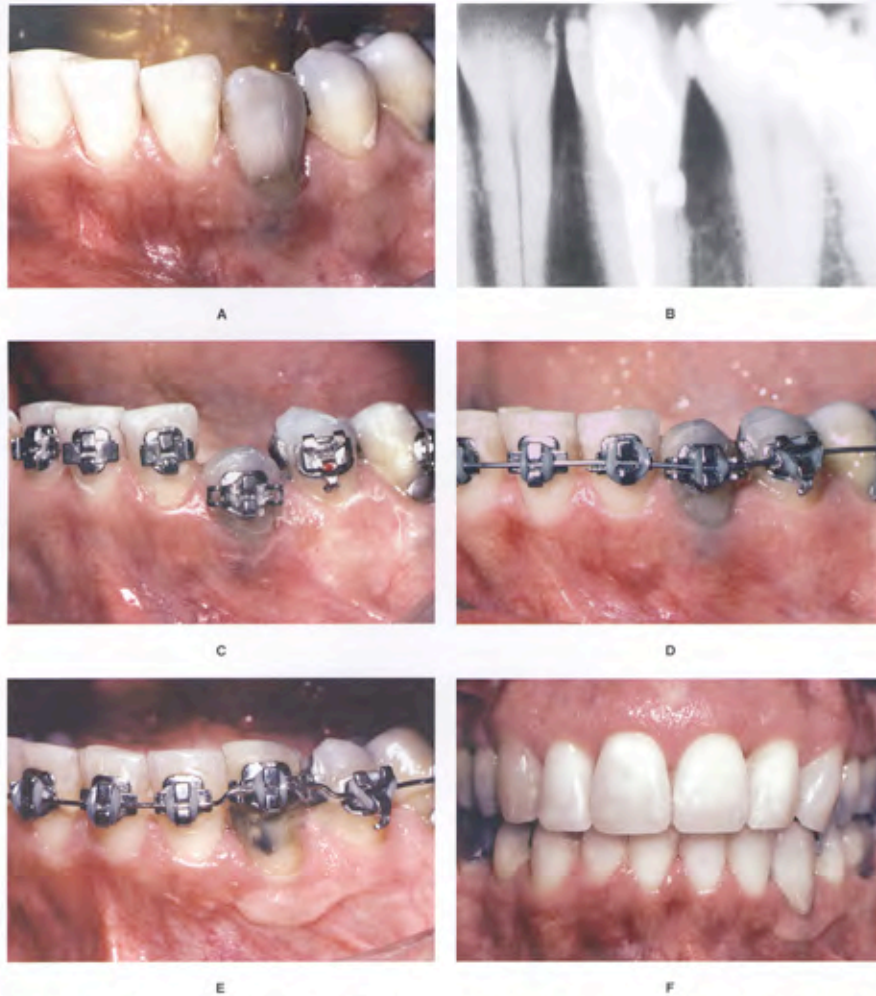
In some patients, a discrepancy may exist between both the marginal ridges and the bony levels between two teeth. However, these discrepancies may not be of equal magnitude. In these patients, orthodontic leveling of the bone may still leave a discrepancy in the marginal ridges. In these situations, the clinician should not use the crowns of the teeth as a guide for completing orthodontic therapy. The clinician should level the bone orthodontically and equilibrate any remaining discrepancies between the marginal ridges. This method will produce the best occlusal result and will improve the periodontal health.

In some patients, accidental or iatrogenic dental trauma may cause an osseous defect adjacent to the affected tooth (Fig. 28-13). In these situations, surgical



**Figure 28-12.** This patient had overeruption of the maxillary left first molar and second molars and a marginal ridge defect between the second premolar and first molar (A). A pretreatment periapical radiograph (B) showed that the interproximal bone was flat. The second molar was extracted. To avoid creating a hemiseptal defect between the first molar and second premolar, the occlusal surface of the first molar was equilibrated (C and D) and the malocclusion was corrected orthodontically (E and F). The opposing arch was subsequently restored.





**Figure 28-13.** This patient had an 8-mm probing on the distal of the mandibular left canine (A), which was caused by a perforation on the root surface during previous endodontic therapy (B). This produced a two-wall defect, with loss of the labial and distal walls. To correct this defect, the orthodontic brackets were placed gingivally and the cusp tip was equilibrated (C). This permitted eruption of the tooth to level the distal defect (D). However, to eliminate the mesial and lingual bone level discrepancies created by the eruption, an apically positioned flap was performed. Also, a free epithelialized soft-tissue graft was used to correct the lack of sufficient keratinized tissue (E). This allowed the restorative dentist to maintain and restore this previously difficult endodontic/periodontic situation (F).

correction of the osseous defect could require significant removal of bone from the adjacent healthy tooth to create an interproximal osseous relation that the patient can maintain. The other alternative in this situation is to erupt the tooth with the osseous defect to eliminate the vertical discrepancy in bone levels. If this were a two-wall defect, periodontal crown lengthening may be necessary after eruption, to level the bone on the nonperiodontally involved surfaces of the affected tooth (Fig. 28-13).

During orthodontic treatment, when teeth are being extruded to level hemiseptal defects, the patient should be monitored regularly by the dentist or periodontist. Initially, the hemiseptal defect will have a greater sulcular depth and will be more difficult for the patient to clean. As the defect is ameliorated through tooth extrusion, interproximal cleaning becomes easier. The dentist or periodontist should recall the patient every 2 to 3 months during the leveling process to control inflammation in the interproximal region.

#### Advanced Horizontal Bone Loss

After orthodontic treatment has been planned, one of the most important factors that determine the outcome of orthodontic therapy is the location of the bands and brackets on the teeth. In a periodontally healthy individual, the position of the brackets is usually determined by the anatomy of the crowns of the teeth. Anterior brackets should be positioned relative to the incisal edges. Posterior bands or brackets are positioned relative to the marginal ridges. If the incisal edges and marginal ridges are at the correct level, the CEJs also will be at the same level. This relation will create a flat bony contour between the teeth. However, if a patient has underlying periodontal problems and significant alveolar bone loss around certain teeth, using the anatomy of the crown to determine bracket placement is not appropriate.

In a patient with advanced horizontal bone loss, the bone level may have resorbed several millimeters from the CEJ. As this occurs, the crown-to-root ratio will become less favorable. By aligning the crowns of the teeth, the clinician may perpetuate tooth mobility by maintaining an unfavorable crown-to-root ratio. In addition, by aligning the crowns of the teeth and disregarding the bone level, there will be significant bone discrepancies between healthy and periodontally diseased roots. This could require periodontal surgery to ameliorate the discrepancies.

The orthodontist can correct many of these problems by using the bone level as a guide to position the brackets on the teeth (Fig. 28-14). In these situations, the crowns of the teeth may require considerable equilibration. If the tooth is vital, the equilibration should be performed gradually to allow the pulp to form secondary dentin and insulate the tooth during the equilibration process.<sup>41</sup> The goal

of equilibration and creative bracket placement is to provide a more favorable bony architecture and a more favorable crown-to-root ratio. In some of these patients, the periodontal defects that were apparent initially may not require periodontal surgery after orthodontic treatment.

#### Furcation Defects

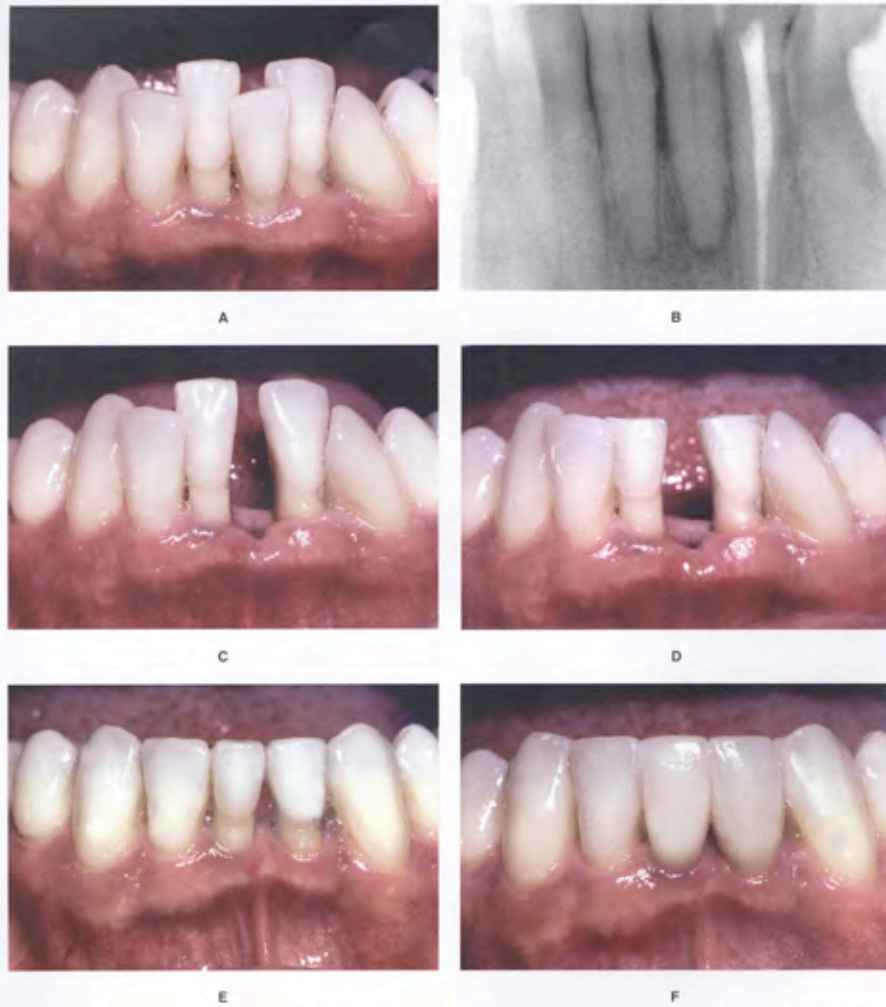
Furcation defects can be classified as incipient (Class I), moderate (Class II), and advanced (Class III). These lesions require special attention in the patient undergoing orthodontic treatment. Often the molars will require bands with tubes and other attachments that will impede the patient's access to the buccal furcation for home care and instrumentation at the time of recall.

Class I defects are amenable to osseous surgical correction with a good prognosis. Class II furcation defects can be treated with grafting or regenerative therapy with barrier membranes, or both. Class III furcation defects are more difficult to treat, and use of grafting and membranes in these lesions is not as predictable. Treatment of Class III furcation lesions in the lower arch can range from open-flap curettage to create a through-and-through furcation for easier cleaning, to hemisection (Fig. 28-15), or even extraction and replacement<sup>42</sup> with an implant (Fig. 28-16). In the upper arch, Class II and III furcations can sometimes be treated with root resection. The most favorable root to remove is the distobuccal root of an upper molar. This treatment has a good prognosis. The disadvantage of root resection is that it requires endodontic therapy and a full-coverage restoration. Detailed discussion of furcation treatment is found in Chapter 24.

Furcation lesions need special attention because they are the most difficult lesions to maintain and can worsen during orthodontic therapy. These patients will need to be maintained on a 2- to 3-month recall schedule. Detailed instrumentation of these furcations will help to minimize further periodontal breakdown.

Regenerative therapy using membranes, bone grafting, or both has been successful in Class I and II furcations. However, in Class III furcations, the use of membranes has not produced consistently satisfactory results. Therefore, another method of treatment must be used for orthodontic patients with Class III furcations in the mandibular arch.

If a patient with a Class III furcation defect will be undergoing orthodontic treatment, a possible method for treating the furcation is to eliminate it by hemisectioning the crown and root of the tooth. This procedure, however, will require endodontic, periodontal, and restorative treatment. If the patient will be undergoing orthodontic treatment, it is advisable to perform the orthodontic treatment first. This is especially true if the roots of the teeth will not be separated or moved apart. In these patients, the molar



**Figure 28-14.** This patient had severe crowding and overeruption of the mandibular incisors (A). In addition, she had significant periodontal bone loss around the mandibular anterior teeth, but the bone level was flat between these teeth (B). To align the teeth, a diagnostic set-up showed that a mandibular incisor extraction (C) would produce a good occlusion. To maintain the flat bone levels and to improve the unfavorable crown-to-root ratio, the incisal edges of the overerupted teeth were reduced (D). In this way, after orthodontic treatment (E), porcelain veneer restorations were able to improve the unesthetic shape of the mandibular incisors (F).



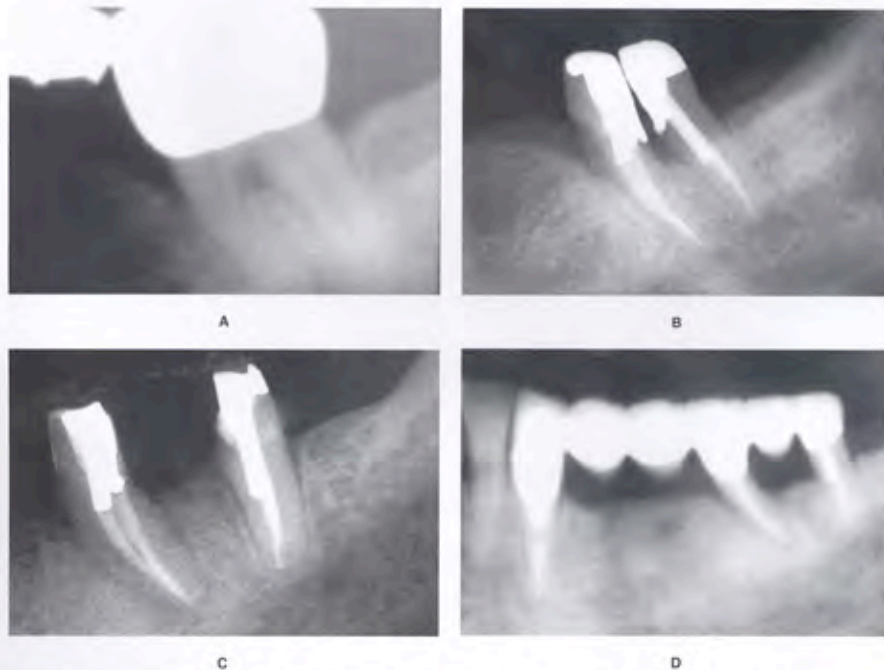
to be hemisected remains intact during orthodontics. These patients would require 2- or 3-month recall visits with the periodontist to ensure that the furcation defect does not lose bone during orthodontic treatment. By keeping the tooth intact during the orthodontic treatment, it simplifies the finishing and tooth movement for the orthodontist.

After orthodontic treatment, endodontic therapy must be performed on both roots of the tooth. Then, periodontal surgery is necessary to divide the tooth. Sulcular incisions are made, a flap is elevated buccal and lingual to the molar, and a fissure bur is used to divide the crown and roots of the teeth. In some situations, the process is more difficult if the furcation is positioned toward the apices of the tooth. After the tooth has been divided, the bone is recontoured around each of the roots and the tissue is allowed to heal. If the roots are short and tapered, the

crowns that restore the two halves of the tooth could be splinted together. If the solder joint of the splinted teeth is positioned toward the occlusal, the patient can clean interproximally in the area of the previous furcation.

In some patients requiring hemisection of a mandibular molar with a Class III furcation, it may be advantageous to push the roots apart during orthodontic treatment (Fig. 28-15). If the hemisected molar will be used as an abutment for a fixed partial denture after orthodontics, moving the roots apart orthodontically will permit more favorable restoration and splinting across the adjacent edentulous spaces.<sup>23</sup>

In the latter situation, hemisecting the tooth, endodontic therapy, and periodontal surgery must be completed before the start of orthodontic treatment. After these procedures have been completed, the orthodontist may place bands or brackets on the root fragments and use a coil



**Figure 28-15.** Before orthodontic treatment, this patient had a Class III furcation defect in the mandibular left second molar (A). Because the patient had an edentulous space mesial to the molar, the tooth was hemisected (B), and the root fragments were separated orthodontically (C). After orthodontic treatment, the root fragments were used as abutments to stabilize a multiunit posterior fixed partial denture (D).

spring to separate the roots. The amount of separation is determined by the adjacent edentulous spaces and the occlusion in the opposing arch. About 7 or 8 mm may be created between the roots of the hemisected molar (Fig. 28-15). This process eliminates the original furcation problem and allows the patient to clean the area with greater efficiency.

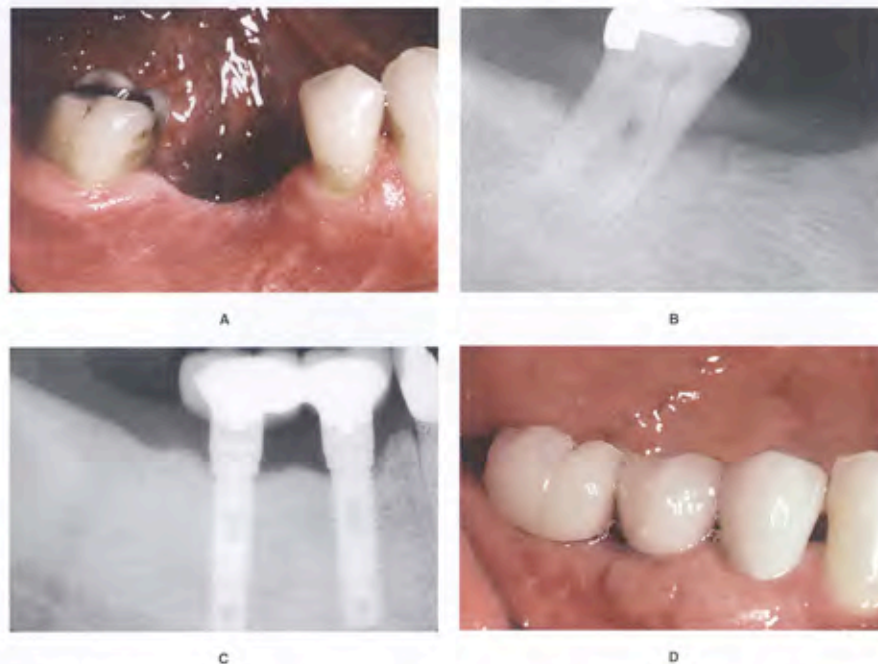
In some molars with Class III furcation defects, the tooth will have short roots, advanced bone loss, fused roots, or some other problem that prevents hemisection and crowning of the fragments. In these patients, it may be more advisable to extract the tooth with a furcation defect and place an osseointegrated implant (Fig. 28-16). If this type of plan were adopted, the timing of the extraction and placement of the implant could occur at any time relative to the orthodontic treatment. In some situations,

the implant could be used as an anchor to facilitate pre-restorative orthodontic treatment.

#### Root Proximity

When roots of posterior teeth are in close proximity, the ability to maintain periodontal health and accessibility for restoration of adjacent teeth may be compromised.<sup>7</sup> However, if the patient is undergoing orthodontic therapy, the roots can be moved apart and bone will be laid down between the adjacent roots. This will open the embrasure beneath the tooth contact, provide additional bone support, and enhance the patient's access to the interproximal region. This generally improves the periodontal health of this area.

If orthodontic treatment will be used to move roots apart, the orthodontist must be aware of this plan before



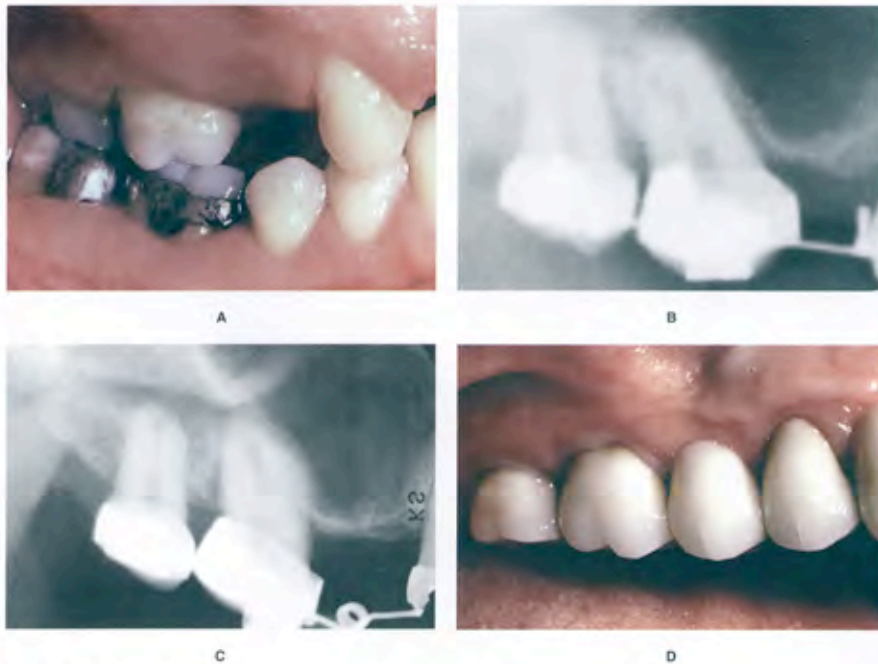
**Figure 28-16.** This patient was missing the mandibular right second premolar and first molar (A). Severe bone loss (B) and attachment loss on the second molar prevented its use as an abutment. Also, a Class III furcation invasion was present. Therefore, the second premolar and first molar were restored with an implant-supported fixed partial denture (C, D).

bracket placement. It is advantageous to place the brackets so the orthodontic movement to separate the roots will begin with the initial archwires (Fig. 28-17). Therefore, brackets must be placed obliquely to facilitate this process. To determine the progress of orthodontic root separation, radiographs will be needed to monitor the status. Generally, 2 to 3 mm of root separation will provide adequate bone and embrasure space to improve periodontal health. During this time, the patient should be maintained by the restorative dentist or periodontist to ensure that a favorable bone response will occur as the roots are moved apart. In addition, these patients will need occasional occlusal adjustment to recontour the crown, as the roots are moving apart (Fig. 28-17). As this happens, the crowns may develop an unusual occlusal

contact with the opposing arch. This should be equilibrated to improve the occlusion.

#### Fractured Teeth/Forced Eruption

Occasionally, an individual will traumatically injure a tooth. If the injury is minor and results in a small fracture of enamel, the tooth can be restored with light-cured composite or a porcelain veneer. However, in some situations, the fracture may extend beneath the level of the gingival margin and terminate at the level of the alveolar ridge. In these situations, restoration of the fractured crown is impossible, because the tooth preparation would extend to the level of the bone. This overextension could result in an invasion of the biologic width of the tooth and cause persistent inflammation of the marginal gingiva (Fig. 28-18).



**Figure 28-17.** This patient was missing the maxillary right second molar and both premolars (A). She had a large maxillary sinus, because the premolars were congenitally missing. The restorative treatment plan was a fixed prosthesis with the abutments on the first and third molars soldered together. However, the patient had root proximity and little bone between the first and third molar roots (B). Therefore, orthodontics was used to tip the roots of the first molar mesially (C), so when they were splinted together (D) there would be sufficient embrasure space apical to the soldered contact for the patient to maintain this area.

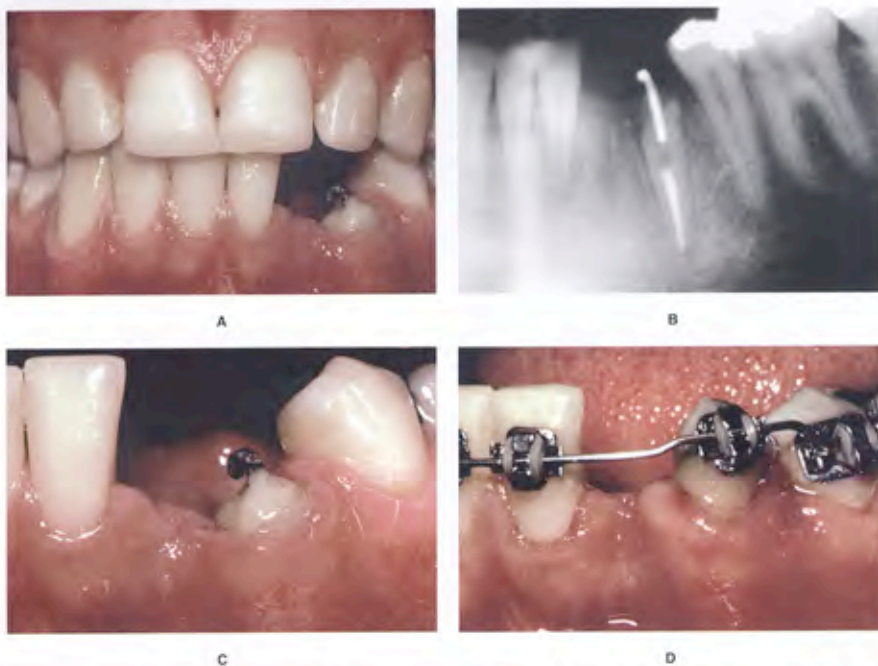


In these situations, it may be beneficial to erupt the fractured root out of the bone and move the fracture margin coronally, so that it can be restored without creating gingival inflammation.<sup>23</sup> However, in some situations, if the fracture is too severe, it may be better to extract the tooth and replace it with an implant or fixed partial denture. The orthodontist, restorative dentist, and periodontist should evaluate six criteria to determine if the tooth should be erupted or extracted.

The first criterion is root length. Is the root long enough so that a crown-to-root ratio of 1:1 will be preserved after the root has been erupted? To determine the answer to this question, the clinician must know how far to erupt the root. If a tooth fracture extends to the level of the bone, it must be erupted 4 mm. The first 2.5 mm will move the fracture margin far enough away from the bone to prevent a biologic width problem. The other 1.5 mm

will provide the proper amount of ferrule for adequate resistance form of the crown preparation. Therefore, if the root is fractured to the bone level and must be erupted 4 mm, the clinician must evaluate a periapical radiograph and subtract 4 mm from the end of the fractured tooth root (Fig. 28-18). Then the length of the residual root should be compared with the length of the eventual crown on this tooth. The crown-to-root ratio should be about 1:1. If the ratio is greater than 1:1, too little root may remain in the bone for stability. In this situation, it may be more prudent to extract the root and place a fixed partial denture or implant.

Root form is the second criterion that determines whether forced eruption is feasible. The shape of the root should be broad and nontapering rather than thin and tapered (Fig. 28-18). A thin, tapered root will provide a narrower cervical region after the tooth has been erupted



**Figure 28-18.** This patient had avulsed the mandibular left lateral incisor and had a severe fracture of the mandibular left canine (A) that extended apical to the level of the alveolar crest on the mesial (B). To restore the tooth adequately and avoid impinging on the periodontium, the fractured root was extruded (C). As the tooth erupted, the gingival margin followed the tooth (D).

*Continued*

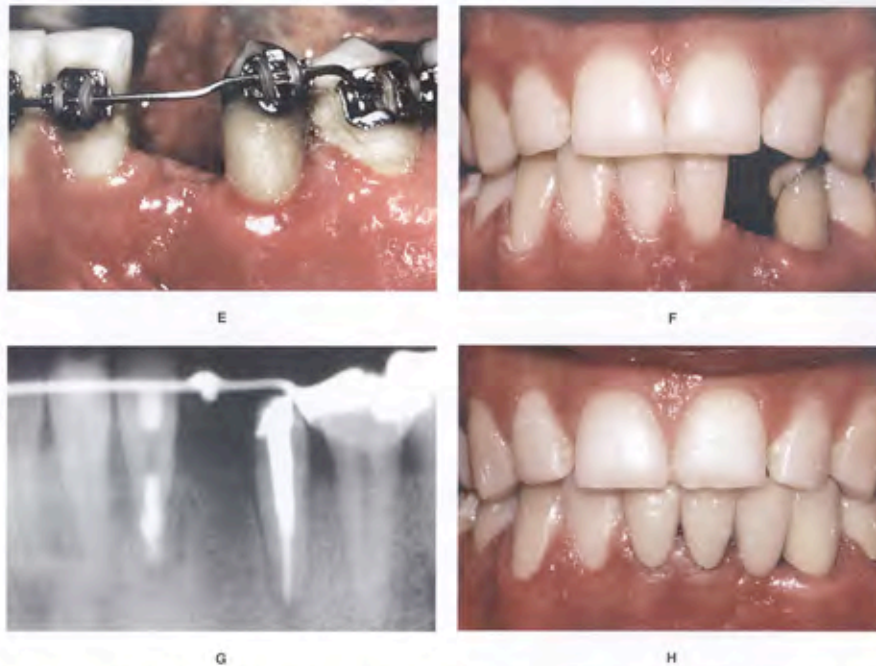


Figure 28-18. cont'd Gingival surgery was required to lengthen the crown of the canine (E-G) so that the final restoration (H) had sufficient ferrule for resistance and retention.

4 mm. This could compromise the esthetic appearance of the final restoration. The internal root form also is important. If the root canal is wide, the distance between the external root surface and root canal filling will be narrow. In these situations, the walls of the crown preparation will be thin, which could result in early fracture of the restored root. The root canal should not be more than a third of the overall width of the root (Fig. 28-18, B). In this way, the root could still provide adequate strength for the final restoration.

A third criterion that determines whether a fractured root should be erupted is the level of the fracture. If the entire crown is fractured 2 to 3 mm apical to the level of the alveolar bone, it is difficult if not impossible to attach to the root to erupt it. The fourth criterion is the relative importance of the tooth. If the patient were 70 years of age, and both adjacent teeth had prosthetic crowns, then

it might be more prudent to simply construct a fixed partial denture attaching to the crowned teeth. However, if the patient were 15 years of age, and the adjacent teeth were not restored, then forced eruption would be much more conservative and appropriate.

The fifth criterion to evaluate before beginning forced eruption of a fractured root is esthetics. If the patient has a high lip line and shows 2 to 3 mm of gingiva when smiling, then any type of restoration in this area will be more obvious. In this situation, keeping the patient's own tooth would provide much better esthetic results than any type of implant or prosthetic replacement. The sixth and final criterion to determine whether a tooth should be erupted is the endodontic/periodontal prognosis. If the tooth has a significant periodontal defect, it may not be possible to salvage the root. In addition, if the tooth root has a vertical fracture, then it is hopeless and must be extracted.

If all of these factors are favorable, then forced eruption of the fractured root is indicated (Fig. 28-18). The orthodontic mechanics necessary to erupt the tooth can vary from elastic traction to orthodontic banding and bracketing. If a large portion of the tooth is still present, then orthodontic bracketing will be necessary. If the entire crown has fractured leaving only the root, then elastic traction from a bonded bar may be possible. The tooth root may be erupted rapidly or slowly. If the movement is performed rapidly, the alveolar bone will be left behind temporarily, and a circumferential fiberotomy may be performed to prevent bone from following the erupted root.<sup>14</sup> However, if the root is erupted slowly, the bone will follow the tooth. In this situation, the erupted root will require crown lengthening and an apically positioned flap to expose the correct amount of tooth to create the proper ferrule, resistance form, and retention for the final restoration.

After the tooth root has been erupted, it must be stabilized to prevent it from intruding back into the alveolus. The reason for reintrusion is the orientation of the principal fibers of the periodontium. During forced eruption, the periodontal fibers become oriented obliquely and stretched as the tooth root moves coronally.<sup>6</sup> These fibers eventually will reorient themselves after about 6 months. Before this time, the tooth root can reintrude significantly. Therefore, if this type of treatment is performed, an adequate period of stabilization is necessary to avoid significant relapse and reintrusion of the root.

As the root erupts, the gingiva will move coronally with the tooth (Fig. 28-18, C). As a result, the clinical crown length will become shorter after extrusion. In addition, the gingival margin may be positioned more incisally than adjacent teeth. In these situations, gingival surgery is necessary to create ideal gingival margin heights.<sup>25-26</sup> The type of surgery varies depending on whether bone removal will be necessary. If bone has followed the root during eruption, the surgeon will elevate a flap and remove the appropriate amount of bone to match the bone height of the adjacent teeth. If the bone level is flat between adjacent teeth and adequate biologic width will remain, a simple excisional gingivectomy will correct the gingival margin discrepancy.

After gingival surgery, an open gingival embrasure may exist between the erupted root and adjacent teeth. This space occurs because the narrower root portion of the erupted tooth has been moved into the oral cavity. This space may be closed in one of two ways<sup>9</sup>: one method involves overcontouring of the replacement restoration, and the other method involves reshaping of the crown of the tooth and movement of the root to close the space. This latter method often helps to improve the overall shape of the final crown on the restored tooth.

### Hopeless Teeth

Patients with moderate to advanced periodontal disease may have specific teeth that are deemed hopeless and normally would be extracted before orthodontic treatment. However, these teeth can be useful for orthodontic anchorage, if the periodontal inflammation can be controlled. In moderate to advanced cases, some periodontal surgery will be necessary around a hopeless tooth. When the flaps are reflected, debridement of the roots of the hopeless tooth may be all that is necessary to control inflammation during the orthodontic process. The important factor is to maintain the health of the bone around the adjacent teeth. Rigidly enforced 3-month periodontal recall is imperative during the process.

After orthodontic treatment, there is a 6-month period of stabilization before reevaluating the periodontal status. Occasionally, the hopeless tooth may be so improved after orthodontic treatment that it is retained. However, most of the time, the hopeless tooth will require extraction, especially if other restorations are planned in the segment. Again, these decisions need to be negotiated among the specialists, restorative dentist, and the patient.

### CONCLUSION

This chapter has discussed and illustrated the benefits of integrating orthodontics and periodontics in the management of restorative patients with underlying periodontal defects. The key to treating these types of patients is communication and proper diagnosis before orthodontic therapy, as well as continued dialogue during orthodontic treatment. Not all periodontal problems are treated in the same way. Hopefully, this discussion of horizontal bone loss, intrabony defects, hemiseptal defects, furcation problems, root proximity, fractured teeth, uneven gingival levels, open gingival embrasures, periodontally hopeless teeth, single-tooth implants, and implant anchorage provides the clinician with a framework that will be helpful in treating these situations.

### REFERENCES

1. Kokich VG, Spear F, Kokich VO: Maximizing anterior esthetics: an interdisciplinary approach. In McNamara JA Jr, editor. *Frontiers in dental and facial esthetics, craniofacial growth series*. Ann Arbor, Mich, 2001, University of Michigan, Needham Press.
2. Kokich V: Esthetics and vertical tooth position: the orthodontic possibilities. *Compend Cont Educ Dent* 18:1225-1231, 1997.



3. Kokich VO, Kiyak HA, Shapiro PA: Comparing the perception of dentists and lay people to altered dental esthetics. *J Esthet Dent* 11:311-324, 1999.
4. Kokich V, Nappen D, Shapiro P: Gingival contour and clinical crown length: their effects on the esthetic appearance of maxillary anterior teeth. *Am J Orthod* 86:89-94, 1984.
5. Kokich VG, Spear F: Guidelines for managing the orthodontic-restorative patient. *Semin Orthod* 3:3-20, 1997.
6. Reitan K: Clinical and histological observations of tooth movement during and after orthodontic treatment. *Am J Orthod* 53:721-745, 1967.
7. Rufenacht C: Structural esthetic rules. In Rufenacht C, editor: *Fundamentals of esthetics*. Chicago, 1990, Quintessence.
8. Kurth JR, Kokich VG: Open gingival embrasures after orthodontic treatment in adults. Prevalence and etiology. *Am J Orthod Dentofacial Orthop* 120:116-123, 2001.
9. Kokich V: Esthetics: the orthodontic-periodontic-restorative connection. *Semin Orthod* 2:21-30, 1996.
10. Spear F, Mathews D, Kokich VG: Interdisciplinary management of single-tooth implants. *Semin Orthod* 3:35-74, 1997.
11. Fudalej P: Determining the cessation of facial growth to facilitate implant placement. Master's Thesis, Seattle, Wash, 1998, University of Washington.
12. Stepovich M: A clinical study of closing edentulous spaces in the mandible. *Angle Orthod* 49:277-283, 1979.
13. Hom B, Turley P: The effects of space closure on the mandibular first molar area in adults. *Am J Orthod* 85:475-489, 1984.
14. Esposito M: Radiological evaluation of marginal bone loss at tooth surfaces facing single-tooth implants. *Clin Oral Implants Res* 4:151-157, 1993.
15. Thilander B: Osseointegrated implants in adolescents. An alternative to replacing missing teeth?. *Eur J Orthod* 16:84-95, 1994.
16. Kokich VG: Management of complex orthodontic problems: the use of implants for orthodontic anchorage. *Semin Orthod* 2:27-35, 1996.
17. Kokich VG: Comprehensive management of implant anchorage in the multidisciplinary patient. In Higuchi KW, editor: *Orthodontic applications of osseointegrated implants*. Chicago, 2000, Quintessence.
18. Ingber J: Forced eruption: Part I. A method of treating isolated one and two wall infrabony osseous defects—rationale and case report. *J Periodontol* 45:199-206, 1974.
19. Brown IA: The effect of orthodontic therapy on certain types of periodontal defects. I. Clinical findings. *J Periodontol* 44:742-756, 1973.
20. Mathews D, Kokich VG: Managing treatment for the orthodontic patient with periodontal problems. *Semin Orthod* 3:21-38, 1997.
21. Zachrisson B, Mjor I: Remodeling of teeth by grinding. *Am J Orthod* 68:543-553, 1975.
22. Kramer GM: Surgical alternatives in regenerative therapy of the periodontium. *Int J Periodontics Restorative Dent* 12:11-21, 1992.
23. Kokich V: Enhancing restorative, esthetic and periodontal results with orthodontic therapy. In Schlager S, Youdelis R, Page R et al, editors: *Periodontal therapy*. Philadelphia, 1990, Lea and Febiger.
24. Pontoriero A, Celenza F: Rapid extrusion with fiber resection: a combined orthodontic-periodontic treatment modality. *Int J Periodontics Restorative Dent* 5:31-43, 1987.
25. Kokich V: Anterior dental esthetics: an orthodontic perspective I. Crown length. *J Esthet Dent* 5:19-23, 1993.
26. Chiche G, Kokich V, Caudill R: Diagnosis and treatment planning of esthetic problems. In Pinault A, Chiche G, editors: *Esthetics in fixed prosthodontics*. Chicago, 1994, Quintessence.