

Managing Congenitally Missing Lateral Incisors, Part I: Canine Substitution

VINCENT O. KOKICH JR, DMD, MSD*
GREGGORY A. KINZER, DDS, MSD†

ABSTRACT

Dentists often encounter patients with missing or malformed teeth. The maxillary lateral incisor is the second most common congenitally absent tooth. There are three treatment options that exist for replacing missing lateral incisors. They include canine substitution, a tooth-supported restoration, or a single-tooth implant. Selecting the appropriate option depends on the malocclusion, specific space requirements, tooth-size relationship, and size and shape of the canine. The ideal treatment is the most conservative option that satisfies individual esthetic and functional requirements. Often the ideal option is canine substitution. Although the orthodontist positions the canine in the most esthetic and functional location, the restorative dentist often needs to place a porcelain veneer or crown to re-create normal lateral incisor shape and color.

This article closely examines patient selection and illustrates the importance of interdisciplinary treatment planning to achieve optimal esthetics. It is the first in a three-part series discussing the three treatment alternatives for replacing missing lateral incisors.

CLINICAL SIGNIFICANCE

Patients with congenitally missing lateral incisors often raise difficult treatment planning issues. Therefore, to produce the most predictable esthetic results, it is important to choose the treatment that will best address the initial diagnosis. This article is the first in a three-part series that describes the different treatments available for patients with congenitally missing lateral incisors. This first article focuses on canine substitution as a method of tooth replacement for these missing teeth. The general dentist will learn to evaluate specific patient selection criteria and determine whether canine substitution is an appropriate treatment alternative for replacing missing lateral incisors. The orthodontist will understand how to position the canines to satisfy functional requirements and achieve proper esthetics. Finally, the importance of interdisciplinary team treatment planning is emphasized as a requirement for achieving optimal final esthetics.

(J Esthet Restor Dent 17:1–6, 2005)

Managing patients with congenitally missing maxillary lateral incisors raises several important issues involving the amount of space, patient's age, type of mal-

occlusion, and condition of the adjacent teeth. There are three treatment options that exist for replacing missing lateral incisors. These options include canine sub-

stitution, a tooth-supported restoration, and a single-tooth implant. There are also specific criteria that must be addressed when choosing the appropriate treatment option.

*Affiliate assistant professor, Department of Orthodontics, University of Washington, Seattle, WA, USA
†Affiliate assistant professor, Department of Prosthodontics, University of Washington, Seattle, WA, USA

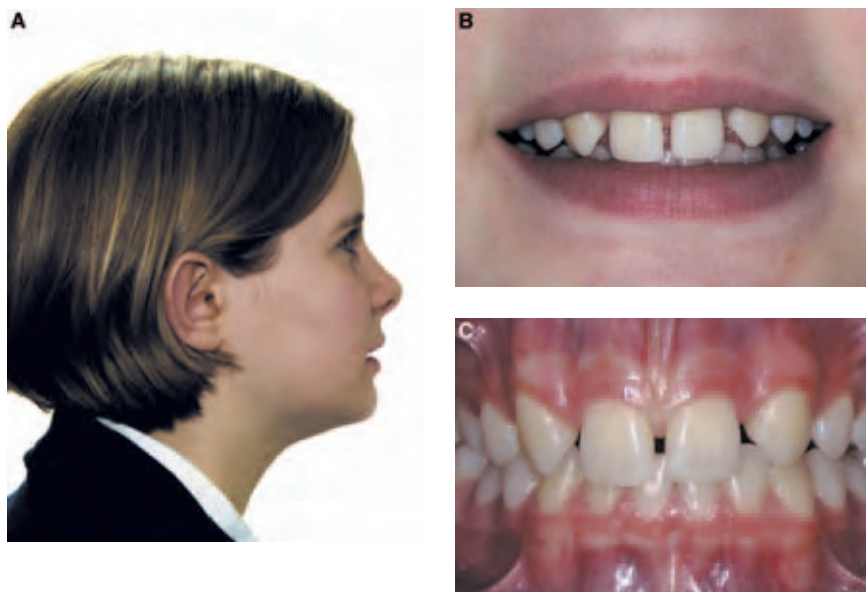


Figure 1. A–C, Evaluation of specific dental and facial criteria is necessary when selecting the appropriate patient for canine substitution.

The primary consideration among all treatment plans should be conservation. Generally, the treatment of choice should be the least invasive option that satisfies the expected esthetic and functional objectives. The orthodontist plays a key role in achieving specific space requirements by positioning teeth in an ideal restorative position. For example, canine substitution can be an excellent, esthetic treatment option for replacing missing laterals. However, if it is used in the wrong patient, the final result may be less than ideal. Ultimately, an interdisciplinary approach is the most predictable way to achieve optimal final esthetics.

SELECTING THE APPROPRIATE PATIENT

There are specific dental and facial criteria that must be evaluated

before choosing canine substitution as the treatment of choice for replacing a missing maxillary lateral incisor. They include malocclusion and amount of crowding, profile, canine shape and color, and lip level (Figure 1).^{1,2} If these selection criteria are fulfilled, the patient can expect a functional and esthetic final result.³

Malocclusion

There are two types of malocclusion that permit canine substitution. The

first is an Angle Class II malocclusion with no crowding in the mandibular arch. In this occlusal pattern, the molar relationship remains class II and the first premolars are located in the traditional canine position (Figure 2). The second alternative is an Angle Class I malocclusion with sufficient crowding to necessitate mandibular extractions. With either of these two malocclusions, the final occlusal scheme should be designed so that the lateral excursive movements are in an anterior group function.^{2,4,5}

Evaluation of the anterior tooth-size relationship is important when substituting canines for lateral incisors. The anterior tooth size excess that is created in the maxillary arch must often be reduced to establish a normal overbite and overjet relationship.¹ Therefore, a critical step in the patient selection process is completion of a diagnostic wax-up. This enables the orthodontist and dentist to evaluate the final occlusion, measure how much canine reduction is necessary, and determine whether an esthetic final result is achievable.⁴⁻⁶

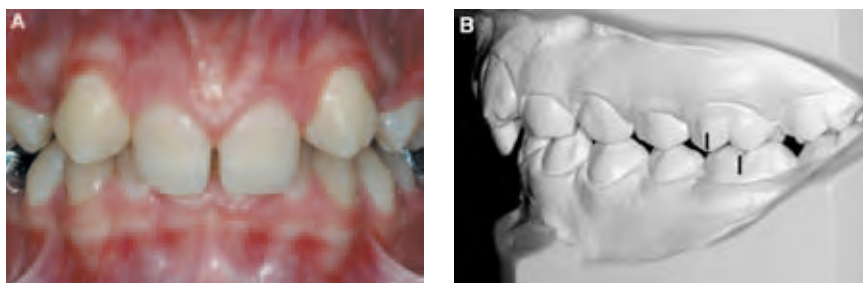


Figure 2. A, Maxillary canines erupting into the edentulous lateral incisor position. B, Class II molar relationship in canine substitution patients.

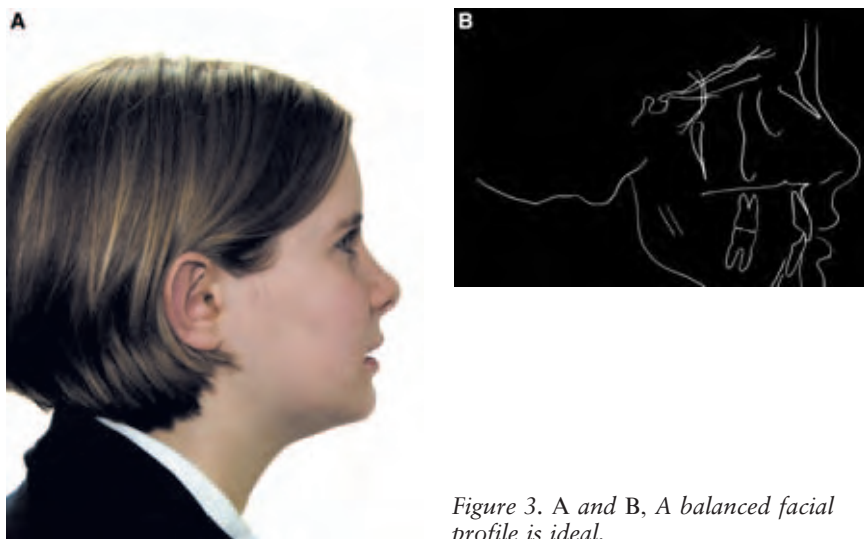


Figure 3. A and B, A balanced facial profile is ideal.

Profile

After one of the two occlusal criteria has been satisfied, the profile should be evaluated. Generally, a balanced, relatively straight profile is ideal (Figure 3). However, a mildly convex profile also may be acceptable (Figure 4). A patient with a mod-

erately convex profile, retrusive mandible, and a deficient chin prominence may not be an appropriate candidate for canine substitution. A better alternative may be one that addresses not only the dental malocclusion but the facial profile as well.

Canine Shape and Color

The shape and color of the canine are important factors to consider for canine substitution to be considered esthetic. Naturally, the canine is a much larger tooth than the lateral incisor it will be replacing. With a wider crown and a more convex labial surface, a significant amount of reduction is often required for the orthodontist to achieve a normal occlusion and acceptable esthetics (Figure 5). If a significant amount of enamel must be removed to establish proper surface contours, the underlying dentin may begin to show through the thin enamel, thereby decreasing the es-

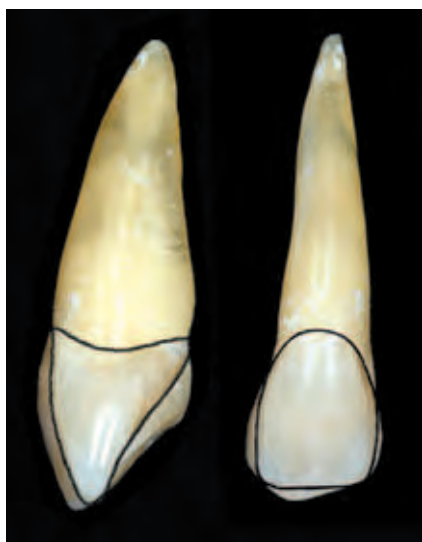

Figure 5. Significant reduction is often required to achieve an acceptable occlusion and ideal esthetics.

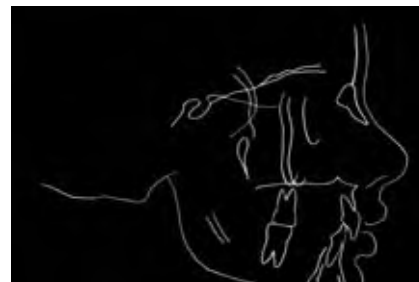

Figure 4. A mildly convex profile may also be acceptable.

thetics.⁷ In a canine with a greater degree of labial convexity, dentin exposure can occur, leading to the need for restorative intervention. Depending on the amount of incisal edge wear of the canine, it may be necessary to restore the mesioincisal and distoincisal edges to re-create normal lateral contours.^{2,8} The color of the natural canine should also be addressed and should approximate that of the central incisor (Figure 6). However, it is not uncommon for the canine to be more saturated with color, resulting in a tooth that is 1 to 2 shades darker than the central incisor. The most conservative way to correct the color difference is to individually bleach the canine. If this fails to

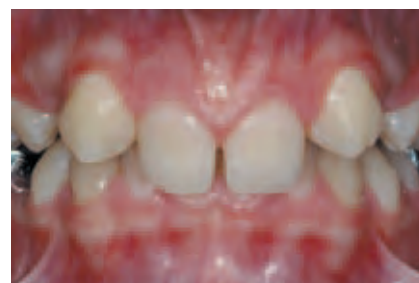

Figure 6. The color of the canine and central incisor crowns should match.

approximate the desired color, a veneer may be indicated.

A significant amount of incisal and palatal reduction generally is required for the orthodontist to vertically position the canine in the appropriate lateral incisor location. Unfortunately, this exposes dentin, which occasionally requires restorative intervention. Zachrisson has shown that extensive grinding using diamond instruments with abundant water spray cooling can be performed on young teeth without long-term changes in tooth sensitivity. However, he found that short-term increases in tooth sensitivity were noted with temperature changes for 1 to 3 days after grinding.⁷⁻⁹

Finally, crown width at the cemento-enamel junction (CEJ) should be evaluated on the pretreatment periapical radiograph to help determine the final emergence profile (Figure 7). A canine with a narrow mesiodistal width at the CEJ produces a more esthetic emergence profile than one with a wide CEJ width (Figure 8). The ideal lateral incisor substitute is a canine that is the same color as the central incisor, is narrow at the CEJ buccolingually and mesiodistally, and has a relatively flat labial surface and narrow midcrown width buccolingually.

Lip Level

If the patient has an excessive gingiva-to-lip distance on smiling, the gingival levels will be more visible. This may be due to a vertical

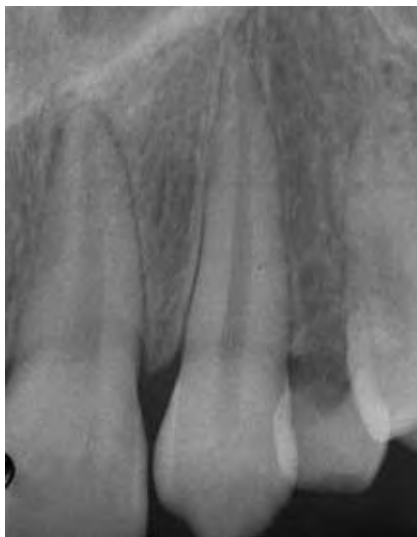

Figure 7. Radiographic evaluation of crown width at the cemento-enamel junction.

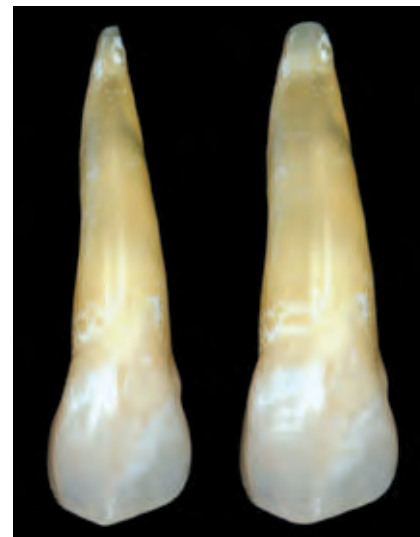

Figure 8. A narrow width at the cemento-enamel junction produces a more esthetic emergence profile than does a wide one.

maxillary excess or a hypermobile lip. The gingival margin of the natural canine should be positioned slightly incisal to the central incisor gingival margin. This helps camouflage the substituted canine. Occasionally, a gingivectomy may need to be performed to properly position the marginal gingiva (Figure 9). The gingival margin of the first premolar is naturally positioned more coronally than the central incisor. If this is a concern to the patient, crown

lengthening can be performed followed by placement of a veneer to establish ideal crown lengths and gingival margin contours. Finally, in patients with high smile lines, a prominent canine root eminence may also be an esthetic concern (Figure 10).⁵

TREATMENT

Proper bracket placement is important when treating patients with canine substitution. The orthodontist

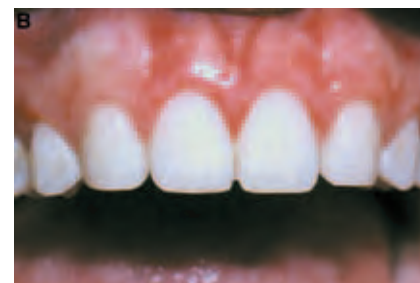
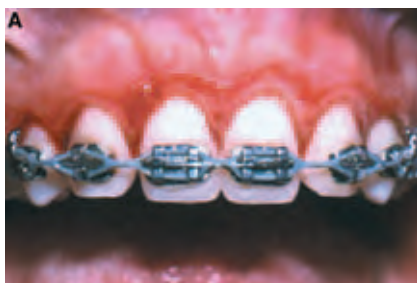
Figure 9. A, Gingivectomy reestablishes proper gingival margin contours. B, Nice gingival architecture at 1-month postgingivectomy.

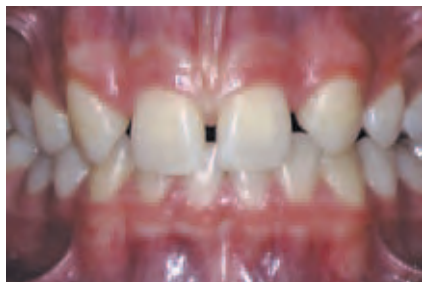

Figure 10. The canine root eminence can be prominent.

should place the brackets according to gingival margin height rather than incisal edge or cusp tip. Typically, the brackets on the canines should be placed at a distance from the gingival margin that will erupt these teeth into the appropriate lateral incisor vertical position. As they erupt, a thicker portion of the crown comes into contact with the mandibular incisors (Figure 11). This often causes premature contacts that must be equilibrated periodically during the alignment stage of ortho-



Figure 11. Significant equilibration of the labial and palatal crown surfaces is often required.

dontic treatment. During finishing the orthodontist must reduce the width of the canine interproximally to achieve optimal esthetics and a normal overjet relationship.

After the teeth have been aligned and the canines reshaped, there is frequently a need for restorative treatment to re-create ideal lateral incisor color and contour. This may

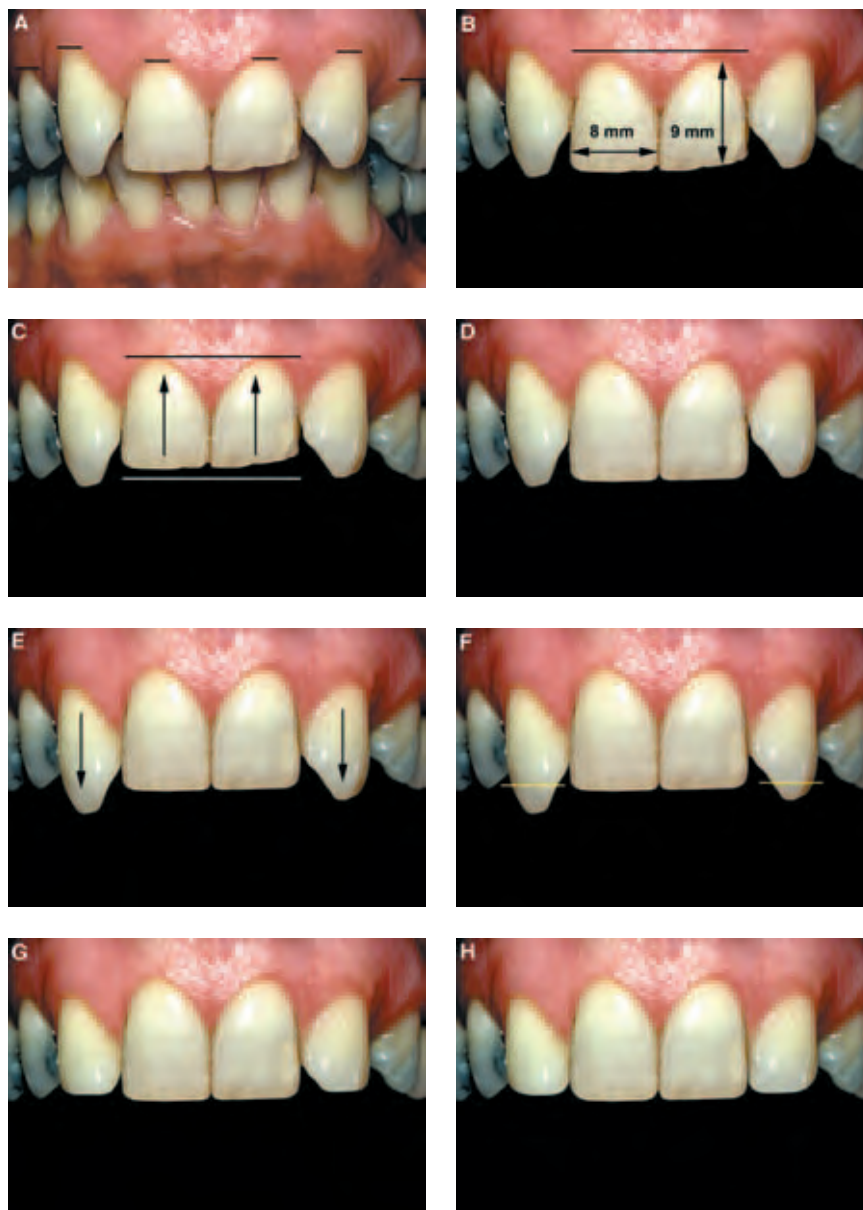


Figure 12. A, Irregular gingival architecture. B, Incisal wear affects proper crown width-to-length ratio. C, Orthodontic intrusion is necessary to facilitate restorative lengthening of the central incisors. D, Provisional composite restorations completed. E, Orthodontic extrusion of the canines. F, Ideal length of the canines as lateral incisors. G, Cuspal equilibration completed. H, Composite restoration of the mesioincisal corners.

be accomplished with bleaching, composite resin, or a porcelain veneer. Generally, the treatment of choice is the most conservative restoration that satisfies the patient's esthetic requirements. A stepwise simulation of the typical treatment sequence is shown in Figure 12.

SUMMARY

Canine substitution can be an excellent treatment alternative for congenitally missing maxillary lateral incisors. Patient selection depends on the type of malocclusion, profile, canine shape and color, and smiling lip level. Pretreatment evaluation of these selection criteria is necessary to ensure treatment success and predictable esthetics.

The orthodontist typically plays the key role in diagnosis and treatment of these patients. However, adjunctive restorative treatment is often necessary to re-create ideal lateral incisor shape and color. Therefore, interdisciplinary treatment planning is necessary to achieve optimal final esthetics.

REFERENCES

1. Kokich VG. Managing orthodontic-restorative treatment for the adolescent patient. In: McNamara JA, Brudon WL, eds. *Orthodontics and dentofacial orthopedics*. Ann Arbor, Michigan: Needham Press Inc, 2001. p. 1–30.
2. Zachrisson BU. Improving orthodontic results in cases with maxillary incisors missing. *Am J Orthod* 1978; 73:274–289.
3. Robertsson S, Mohlin B. The congenitally missing upper lateral incisor. A retrospective study of orthodontic space closure versus restorative treatment. *Eur J Orthod* 2000; 22:697–710.
4. Tuverson DL. Orthodontic treatment using canines in place of missing maxillary lateral incisors. *Am J Orthod* 1970; 58:109–127.
5. Senty EL. The maxillary cuspid and missing lateral incisors: esthetics and occlusion. *Angle Orthod* 1976; 46:365–371.
6. Zachrisson BU, Rosa M. Integrating esthetic dentistry and space closure in patients with missing maxillary lateral incisors. *J Clin Orthod* 2001; 35:221–234.
7. Zachrisson BU, Mjor IA. Remodeling of teeth by grinding. *Am J Orthod* 1975; 68:545–553.
8. Sabri R. Management of missing lateral incisors. *J Am Dent Assoc* 1999; 130: 80–84.
9. Thordarson A, Zachrisson BU, Mjor IA. Remodeling of canines to the shape of lateral incisors by grinding: a long-term clinical and radiographic evaluation. *Am J Orthod Dentofacial Orthop* 1991; 100:123–132.

Reprint requests:

©2005 BC Decker Inc