

# Managing Congenitally Missing Lateral Incisors. Part III: Single-Tooth Implants

GREGGORY A. KINZER, DDS, MSD\*

VINCENT O. KOKICH JR., DMD, MSD†

## ABSTRACT

Three treatment options exist for the replacement of congenitally missing lateral incisors. They include canine substitution, a tooth-supported restoration, and a single-tooth implant. Selecting the appropriate treatment option depends on the malocclusion, anterior relationship, specific space requirements, and condition of the adjacent teeth. The ideal treatment is the most conservative option that satisfies individual esthetic and functional requirements.

Today, the single-tooth implant has become one of the most common treatment alternatives for the replacement of missing teeth. This article closely examines the many interdisciplinary issues that arise when treatment planning the placement of single-tooth implants in patients with congenitally missing lateral incisors. The specific criteria that must be evaluated illustrate the importance of an interdisciplinary treatment approach to achieve optimal esthetics and long-term predictability. This is the final article of a three-part series discussing the three treatment alternatives for replacing congenitally missing lateral incisors.

## CLINICAL SIGNIFICANCE

When treatment planning single-tooth implants to replace congenitally missing lateral incisors, an interdisciplinary approach is necessary to provide the most predictable treatment outcome.

*(J Esthet Restor Dent 17:202–210, 2005)*

The replacement of congenitally missing lateral incisors raises several important treatment planning concerns. Therefore, no matter what treatment option is chosen, it is beneficial to use an interdisciplinary treatment approach to get the most predictable outcome. One of the primary considerations among all treatment options is conservation of tooth structure. In Part I of this series, the treatment alternative discussed was canine substitution. This typically

involves little tooth preparation other than some minor coronal reshaping to improve the esthetics and function of the maxillary canines as lateral incisors. However, there are many individuals who do not meet the qualifications necessary to be considered for canine substitution. In these patients, some form of restoration must be considered.

The restorative treatment alternatives can be divided into two cate-

gories: a single-tooth implant or a tooth-supported restoration. Part II of this series discussed the three primary types of tooth-supported restorations: a resin-bonded fixed partial denture, a cantilevered fixed partial denture, or a conventional full-coverage fixed partial denture. Although each of these restorative treatment options can be used to achieve predictable esthetics, function, and longevity, they require varying amounts of tooth structure removal.

\*Affiliate assistant professor, Department of Prosthodontics, University of Washington, Seattle, WA, USA  
†Affiliate assistant professor, Department of Orthodontics, University of Washington, Seattle, WA, USA

Today, the single-tooth implant has become one of the most common treatment alternatives for the replacement of missing teeth.<sup>1-6</sup> Various studies have shown the successful osseointegration and long-term function of restorations supported by single-tooth implants.<sup>7-10</sup> In addition to the high success rates of implant-supported single-tooth replacement, one of the main advantages of this type of restoration is the ability to leave the adjacent teeth untouched. This is particularly beneficial when dealing with young patients and unrestored dentitions. However, implants cannot be placed until facial growth is complete. Therefore, monitoring eruption in these patients at an early age is important for optimal implant site development.

This final segment of the series describes the interdisciplinary interaction between the orthodontist and the restorative dentist as they diagnose and treat patients requiring single-tooth implants to replace congenitally missing maxillary lateral incisors.

#### IMPLANT SITE DEVELOPMENT

The first person to diagnose a congenitally missing maxillary lateral incisor is often the restorative dentist. It may be discovered in patients between 7 and 10 years of age, at which time a referral may be made to see the orthodontist. Frequently, these children have retained maxillary primary lateral incisors. By

evaluating periapical or panoramic radiographs, the orthodontist can evaluate the position of the unerupted maxillary canine (Figure 1). If the crown of the permanent canine is apical to the primary canine root, it may be necessary to selectively extract the primary lateral incisor to encourage the permanent canine to erupt adjacent to the central incisor (Figure 2).<sup>11</sup>

If an implant restoration is to replace the missing lateral incisor, the thickness of the alveolus must be adequate to allow proper implant placement. Without the eruption of the permanent lateral incisor, the osseous ridge in this area does not fully develop. If the permanent canine is allowed to erupt mesially through the alveolus into the lateral position, its large buccolingual width will influence the thickness of the edentulous ridge. When the permanent canine is orthodontically moved distally, an increased buccolingual alveolar width is established (Figure 3).<sup>12</sup> Studies have shown that if the implant site is developed by this orthodontic tooth movement, its buccolingual width remains stable over time.<sup>13,14</sup> This is especially beneficial given that an implant cannot be placed until facial growth is complete. If the canine does not erupt near the central incisor or cannot be guided into this position, the osseous ridge will not fully develop. In these cases, it may be necessary to place a bone graft

either prior to or in conjunction with implant placement to achieve optimal alveolar ridge thickness.

#### Space Appropriation

As was discussed in the second part of this series, there are four methods of determining the appropriate spacing for patients with missing maxillary lateral incisors. The first is the golden proportion. This method measures teeth by evaluating a smiling or frontal intraoral photograph in a two-dimensional view. Since the maxillary teeth are positioned along an arc, each tooth should be 61.8% wider than the tooth distal to it.<sup>15</sup>

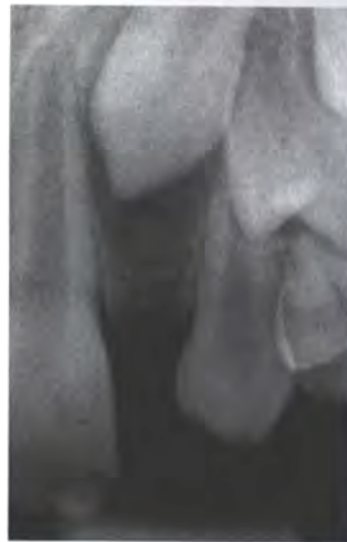


Figure 1. The goal is often selective extraction of the retained primary lateral to encourage eruption of the permanent canine into the missing lateral incisor position. This ultimately develops the alveolar ridge for implant placement.

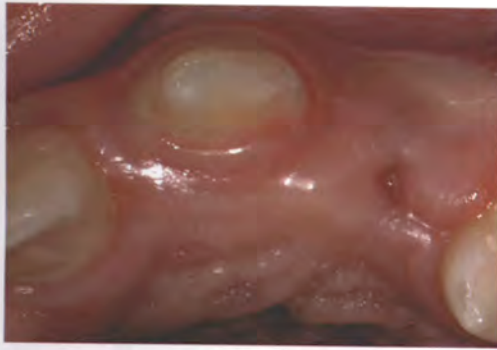

Figure 2. As the permanent canine erupts adjacent to the central incisor, its large buccolingual width begins to develop the alveolar ridge in the edentulous area.

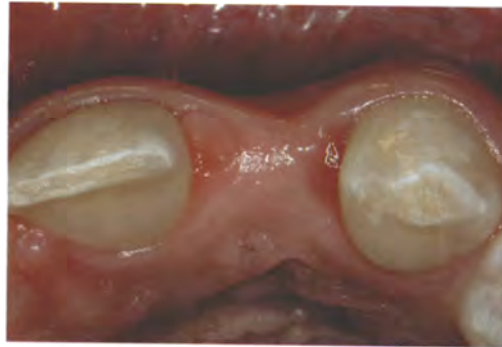

Figure 3. The canine is moved distally, leaving behind an adequate buccolingual width for implant placement.

The second method is to use the contralateral lateral incisor if it has a normal width.<sup>16</sup> However, this method is not appropriate if the contralateral tooth is missing or peg shaped.

The third method of space appropriation is to conduct a Bolton analysis.<sup>17</sup> This is a quick and reliable way to determine the proper spacing for missing or malformed teeth. Bolton introduced this method in 1958 as a way to compare the mesiodistal widths of the dental arches to achieve ideal occlusal relationships.<sup>18</sup> Use of this method is described in detail in Part II of the series (*J Esthet Restor Dent* 2005;2:76-84).

The most predictable method is to construct a diagnostic wax-up. If the anterior and posterior teeth are set in their ideal functional and esthetic relationships, the remaining

space should be ideal for a lateral incisor restoration.<sup>16,19,20</sup> Generally this width ranges from 5 to 7 mm.

It is important to evaluate the width of the edentulous space that is created for the lateral incisor when determining the appropriate size of the implant to be placed. To have adequate room for the development of the papillae, 1.5 to 2.0 mm of space is recommended between the head of the implant and the adjacent teeth.<sup>21</sup> Given the range of widths for the lateral incisor space and the current implant dimensions, this may not always be feasible. If the edentulous space for the lateral incisor is 7 mm wide, a traditional implant diameter of 3.75 mm can be used. This implant, which has a 4.1 mm platform, leaves about 1.5 mm of space between the implant and the adjacent teeth for the development and maintenance of the papilla.

On the other hand, if the edentulous space for the lateral incisor is only 5 mm wide and a traditional 3.75 mm diameter implant is used, there will be less than 0.5 mm of space between head of implant and the adjacent teeth. The result would be inadequate space for the interdental soft tissue and, hence, a compromised papillary position. In this situation, a smaller-diameter implant should be used.

After the appropriate amount of coronal space has been determined, it is necessary to evaluate the interradicular spacing.<sup>16</sup> The restorative treatment that is chosen to replace the missing lateral incisor is often based on whether adequate spacing can be established between the root apices. To place an implant, the minimum interradicular distance is generally 5 mm. This amount of interradicular space provides enough room for placement of a small-

diameter implant with approximately 0.75 mm of bone between the implant and the adjacent roots.

Problems with inadequate space between the root apices are generally due to improper mesiodistal root angulation. This is noticeable when time is not taken to align the roots properly. When the orthodontist opens space for the missing lateral incisor, the crowns of the maxillary central incisor and canine are tipped apart. Unfortunately, the roots of these teeth do not move as quickly (Figure 4). This problem of root proximity often goes unnoticed and, as a result, uncorrected, making it impossible for the surgeon to place an implant. Therefore, it is important to take a periapical radiograph of the edentulous area prior to removing orthodontic appliances to confirm the ideal root position and adequate spacing for a future implant placement (Figure 5).<sup>13,16</sup>

In certain patients it may be impossible to achieve acceptable interradicular spacing using orthodontics, even though the coronal spacing may be ideal. An example would be a patient with a Class III tendency malocclusion requiring proclination of the maxillary incisors (Figure 6). As the maxillary incisor crowns are aligned, they are tipped labially. However, their roots do not move coincidentally. They tend to converge toward each other resulting in a "wagon-wheel" effect (Figure 7). Unfortunately, these roots cannot

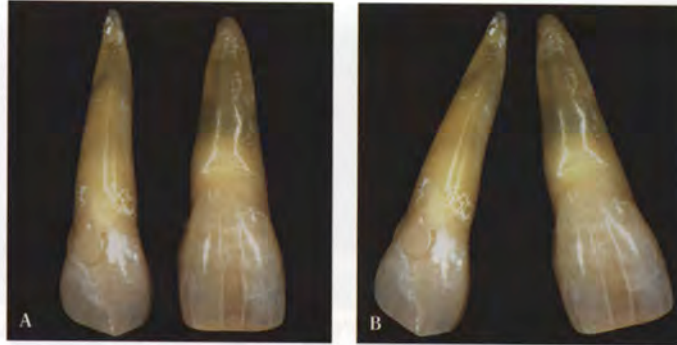


Figure 4. A, After the canine erupts adjacent to the central incisor, the appropriate amount of coronal space must be opened for the missing lateral incisor. B, When the space is opened, the crowns of the central incisor and canine are tipped apart.

be tipped labially during orthodontic treatment because of the underlying Class III skeletal tendency. The maxillary facial cortical plate limits any significant labial root movement of the maxillary incisors. Therefore, it may be impossible to achieve the interradicular spacing necessary for implant placement in these patients. In this situation, an alternate restorative option is required (Figure 8).

#### Papillary Changes during Space Appropriation

In adult patients, the direction of tooth movement affects papilla heights on the distal aspect of the central incisors and the mesial aspect of the canines. According to Atherton, as teeth are moved away from each other during space opening, the papilla remains stationary as the adjacent sulci are everted.<sup>22</sup> The exposed nonkeratinized gingiva appears red. Over time this tissue

keratinizes, but the location of the papilla does not change (Figure 9). This can pose an esthetic challenge

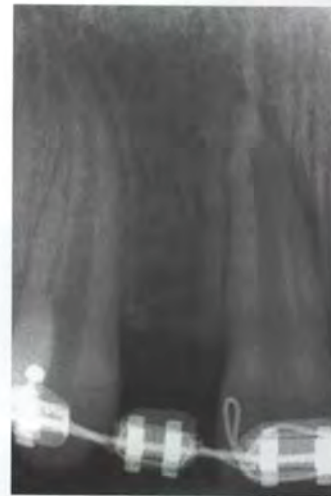

Figure 5. To confirm the clinical evaluation, a periapical radiograph is taken during orthodontic treatment to evaluate the relationship between the roots of the central incisor and the canine.

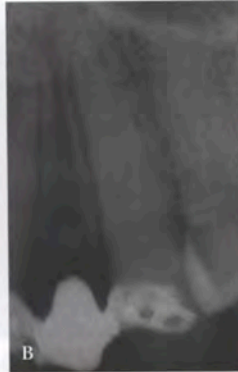
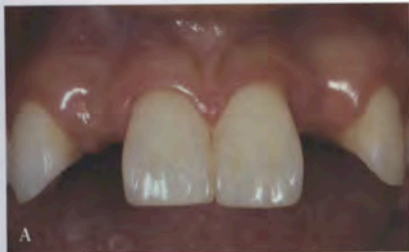
Figure 6. A, This patient had previously been restored with resin-bonded fixed partial dentures that subsequently failed. B, Inadequate interradi-  
cular spacing for implant placement necessitated the need for orthodontic treatment.

for the periodontist and restorative dentist when placing the implant and designing the restoration. Fortunately, this does not tend to occur in adolescent patients owing to the fact that as a child's face continues to grow and the teeth erupt, the bone and gingiva constantly change. As a result, the papillae adjacent to the implant site are not affected permanently.

**TIMING OF IMPLANT PLACEMENT**

What is the appropriate time to place an implant? The answer to this question is based on a patient's facial growth. As the face grows and the mandibular rami lengthen, teeth must erupt to remain in occlusion. Implants cannot erupt. If an implant is placed before a patient has completed his or her facial growth, significant periodontal,

occlusal, and restorative problems may be created.<sup>11</sup>

So, how do we determine the completion of growth for individual patients? Hand-wrist radiographs are occasionally taken to assess growth. However, they do not predictably determine the cessation of facial growth. The most predictable way to monitor facial growth is by evaluating serial cephalometric radiographs taken 6 months to 1 year apart.<sup>12</sup> These radiographs, when superimposed, illustrate any changes in vertical facial height over the specific time period. If the two sequential radiographs show no growth, then an implant can be placed and significant eruption of the adjacent teeth will not be expected.<sup>13</sup>

**INTERIM TOOTH REPLACEMENT AFTER ORTHODONTICS**

If implants cannot be placed until facial growth is complete, how is the edentulous space maintained

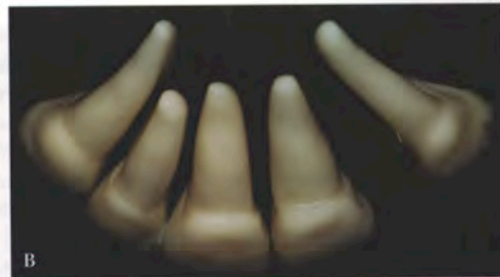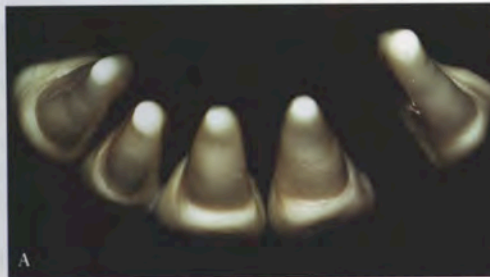


Figure 7. A, When the maxillary anterior teeth are at the proper inclination, there should be adequate interradi-  
cular space for implant placement. B, When the maxillary incisors are proclined, the root apices converge. This often creates root proximity  
problems that make implant placement difficult.

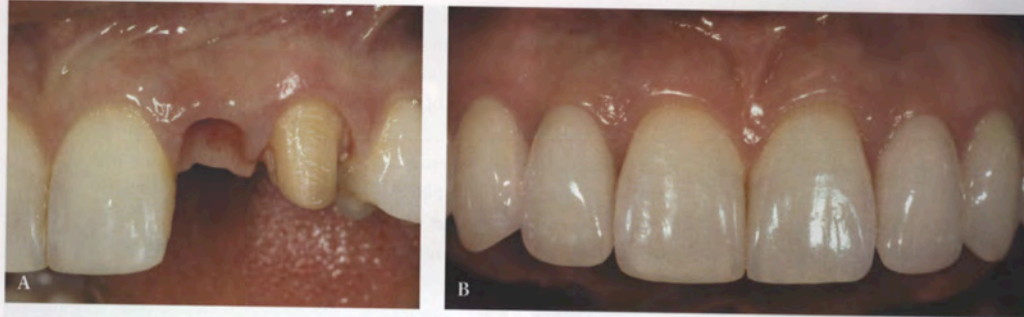

Figure 8. A, Because adequate room could not be opened apically, a cantilever fixed partial denture was chosen to replace the lateral incisors and alter the esthetics of the canines. B, The final restoration of the cantilevered fixed partial dentures replacing the lateral incisors. Connective tissue grafting was done to improve the pontic-soft tissue relationship.

from the time the orthodontic appliances are removed until the implant is able to be placed and restored?

One option is to use a removable retainer with a prosthetic tooth. This is an easy and efficient way to

replace the missing tooth as well as ensure postorthodontic retention. Care must be taken to ensure that

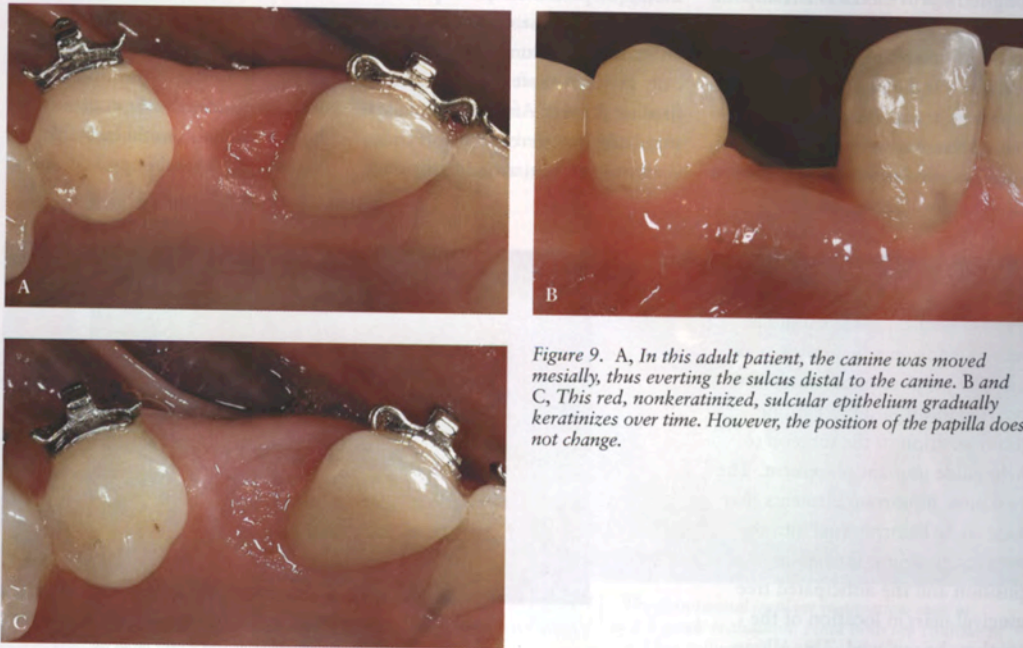


Figure 9. A, In this adult patient, the canine was moved mesially, thus everting the sulcus distal to the canine. B and C, This red, nonkeratinized, sulcular epithelium gradually keratinizes over time. However, the position of the papilla does not change.

the retainer is supported by the adjacent teeth rather than solely resting on the soft tissue in the edentulous area. This helps avoid excessive pressure and inflammation of the ridge and papillary areas.

The use of a retainer works well when a short period of time is anticipated until the implant can be placed. If it will be years before growth is completed and an implant can be placed, a more long-term provisional is recommended. With long-term use, a removable retainer can cause problems of tissue inflammation and papillary hyperplasia. As discussed in Part II of the series, a more appropriate long-term provisional is a resin-bonded fixed partial denture. This type of restoration keeps excessive pressure off the ridge and can help support the papilla. In addition, it can be removed when it is no longer needed with minimal alteration of the adjacent teeth.

#### IMPLANT PLACEMENT

To ensure proper implant placement, a surgical guide should be fabricated from a diagnostic wax-up. The purpose of the guide is to provide information regarding tooth position to the surgeon to help guide implant placement. The two most important elements that need to be incorporated into the surgical guide are the incisal edge position and the anticipated free gingival margin location of the tooth to be replaced. This allows the position of the final restoration

to dictate the placement of the implant.<sup>23</sup> The other benefit of the surgical guide is that it can easily be used to index the position of the implant for use in the fabrication of an implant-supported provisional restoration. After implant placement, 4 to 6 months should be allowed for adequate osseointegration to occur.

#### Prosthetically Guided Soft Tissue Management

Once the implant has been surgically uncovered, the restorative phase begins. Rather than proceeding directly to the final impression and fabrication of the definitive crown, a provisional restoration should be placed on the implant. The main purpose of placing a provisional restoration is to prosthetically guide the soft tissue into its final position.<sup>24</sup> After the implant is surgically uncovered, the soft tissue is allowed to heal around a healing

abutment. Typically the diameter of the healing abutment is narrower than the diameter of the tooth to be replaced (Figure 10). As a result, the tissue does not have the same scalloped architecture that is present around natural teeth.

When a provisional restoration is placed, the subgingival contours and shape of the provisional will influence the position of the soft tissue (Figure 11).<sup>25,26</sup> Adding more contour to the facial aspect of the provisional causes the facial free gingival margin to move apically, whereas adding interproximal contour to the provisional helps create a more ideal papillary form (Figure 12). The provisional restoration is generally allowed to remain in place for 4 to 6 weeks. After this amount of time, the position of the tissue, as guided by the contours of the provisional, should be stable (Figure 13). A final impression of

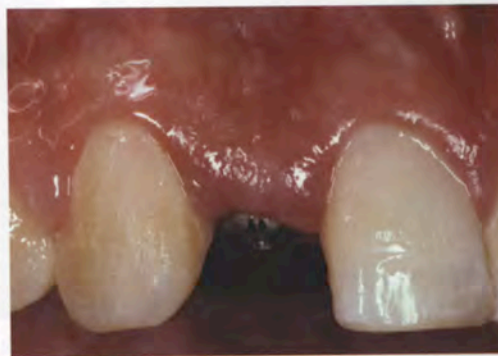

Figure 10. The tissue has healed around a 4 mm tall healing abutment. Note the height of the tissue is at the same level as the adjacent papillae.

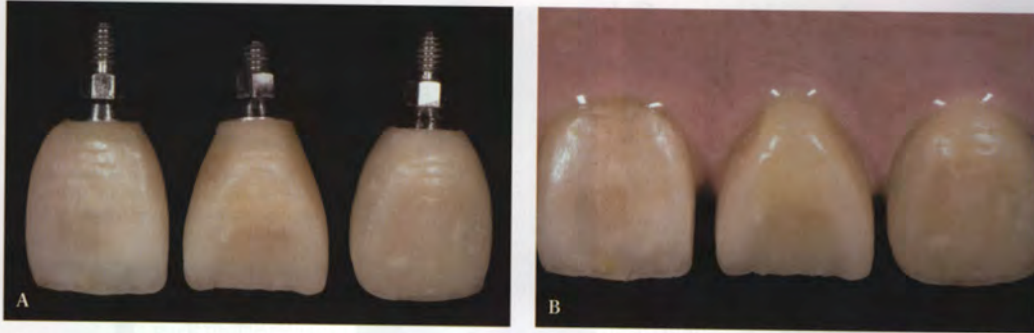


Figure 11. A, Wax was used to create the three basic tooth morphologies that are seen in natural teeth (square, triangular, and ovoid). B, Soft tissue replication material poured around the different tooth shapes illustrates the influence of tooth contour on the resulting position of the soft tissue. A square cervical tooth shape results in a more square gingival architecture, whereas a triangular cervical tooth shape leads to a more triangular gingival architecture. The amount of facial contour also influences the position of the facial free gingival margin.

the implant can then be made that transfers this information to the laboratory for fabrication of the definitive restoration (Figure 14).

#### SUMMARY

Many restorative options exist for the replacement of congenitally missing lateral incisors. Depending

on the type of final restoration that is chosen, interdisciplinary management of these patients often plays a vital role in the facilitation of treatment. One of the most common treatment alternatives for the replacement of congenitally missing teeth is a single-tooth implant. The main advantage of this type

of restoration is that it leaves the adjacent teeth intact. To provide adequate room both in the coronal and apical areas, orthodontics is often necessary. This article discusses the key points that need to be addressed when replacing congenitally missing lateral incisors with single-tooth implants.

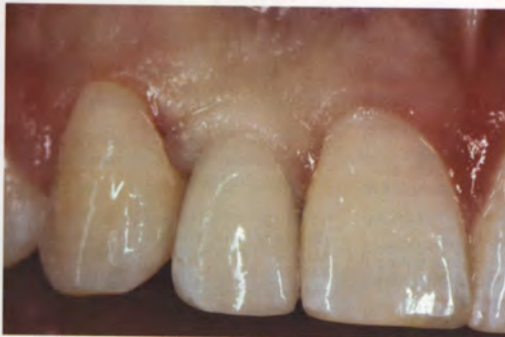

Figure 12. This photograph was taken minutes after seating the screw-retained provisional implant. The tissue blanching that is present is transient and is due to the pressure caused by the difference in the provisional's subgingival contour compared with that of the healing abutment.

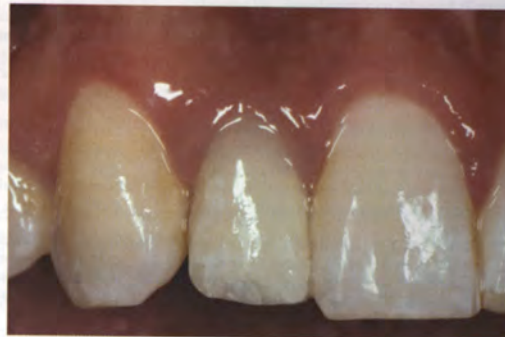

Figure 13. The provisional implant restoration seen in Figure 12 at a 6-week evaluation. Note how the contour of the provisional has influenced the form of the tissue, causing controlled recession on the facial aspect while maintaining the height of the papilla.



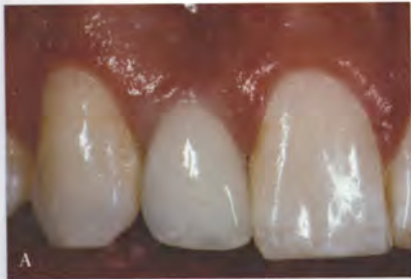

Figure 14. The final restoration (A) and radiograph (B) of the single-tooth implant replacing the congenitally missing lateral incisor at 1-year postinsertion.

REFERENCES

- Covani U, Crespi R, Cornellini R, Barone A. Immediate implants supporting single crown restoration: a 4-year prospective study. *Periodontology* 2004; 75:982-988.
- Sadan A, Blatz MB, Salinas TJ, Block MS. Single-implant restorations: a contemporary approach for achieving a predictable outcome. *Int J Oral Maxillofac Surg* 2004; 62(9 Suppl 2):73-81.
- Vermynen K, Collaert B, Linden U, Bjorn AL, De Bruyn H. Patient satisfaction and quality of single-tooth restorations. *Clin Oral Implants Res* 2003; 14(1):119-124.
- Garber DA, Salama MA, Salama H. Immediate total tooth replacement. *Compend Contin Educ Dent* 2001; 22:210-216, 218.
- Mayer TM, Hawley CE, Gunsolley JC, Feldman S. The single-tooth implant: a viable alternative for single-tooth replacement. *J Periodontol* 2002; 73:687-693.
- Naert I, Koutsikakis G, Duyck J, Quirynen M, Jacobs R, van Steenberghe D. Biologic outcome of single-implant restorations as tooth replacements: a long-term follow-up study. *Clin Implant Dent Relat Res* 2000; 2:209-218.
- Weng D, Jacobson Z, Tarnow D, et al. A prospective multicenter clinical trial of 3i machined-surface implants: results after 6 years of follow-up. *Int J Oral Maxillofac Implants* 2003; 18:417-423.
- Davarpanah M, Martinez H, Etienne D, et al. A prospective multicenter evaluation of 1,583 3i implants: 1 to 5-year data. *Int J Oral Maxillofac Implants* 2002; 17:820-828.
- Romeo E, Chiapasco M, Ghisolfi M, Vogel G. Long-term clinical effectiveness of oral implants in the treatment of partial edentulism. Seven-year life table analysis of a prospective study with ITI dental implants system used for single-tooth restorations. *Clin Oral Implants Res* 2002; 13(2):133-143.
- Noack N, Willer J, Hoffmann J. Long-term results after placement of dental implants: longitudinal study of 1,964 implants over 16 years. *Int J Oral Maxillofac Implants* 1999; 14:748-755.
- Biggerstaff RH. The orthodontic management of congenitally absent maxillary lateral incisors and second premolars: a case report. *Am J Orthod Dentofacial Orthop* 1992; 102:537-545.
- Kokich VG. Managing orthodontic-restorative treatment for the adolescent patient. In: McNamara JA, Brudon WL, eds. *Orthodontics and dentofacial orthopedics*. Ann Arbor, MI: Needham Press, 2001:423-452.
- Kokich VG. Maxillary lateral incisor implants: planning with the aid of orthodontics. *Int J Oral Maxillofac Surg* 2004; 62:48-56.
- Ostler MS, Kokich VG. Alveolar ridge changes in patients congenitally missing mandibular second premolars. *J Prosthet Dent* 1994; 71:144-149.
- Lombard RE. The principles of visual perception and their clinical application to denture esthetics. *J Prosthet Dent* 1973; 29:358-382.
- Spear F, Mathews D, Kokich VG. Interdisciplinary management of single-tooth implants. *Semin Orthod* 1997; 3:45-72.
- Freeman JE, Maskeroni AJ, Lorton L. Frequency of Bolton tooth-size discrepancies among orthodontic patients. *Am J Orthod Dentofacial Orthop* 1996; 110:24-27.
- Bolton WA. Disharmony in tooth size and its relation to the analysis and treatment of malocclusion. *Angle Orthod* 1958; 28:113-130.
- McNeill RW, Joondeph DR. Congenitally absent maxillary lateral incisors: treatment planning considerations. *Angle Orthod* 1973; 43:24-29.
- Nordquist GG, McNeil RW. Orthodontic vs. restorative treatment of the congenitally absent lateral incisor—long term periodontal and occlusal evaluation. *J Periodontol* 1975; 46:139-143.
- Saadun AP, LeGall M, Touati B. Current trends in implantology: part II—treatment planning and tissue regeneration. *Pract Periodontics Aesthet Dent* 2004; 16:707-714.
- Atherton JD. The gingival response to orthodontic tooth movement. *Am J Orthod Dentofacial Orthop* 1970; 58:179-186.
- Garber DA. The esthetic implant: letting restoration be the guide. *J Am Dent Assoc* 1995; 126:319-325.
- Touati B, Guez G, Saadoun A. Aesthetic soft tissue integration and optimized emergence profile: provisionalization and customized impression coping. *Pract Periodontics Aesthet Dent* 1999; 11:305-314.
- Yamamoto M, Miyoshi Y, Kataoka S. Special discussion—fundamentals of esthetics: contouring techniques for metal ceramic restorations. *Quintessence Dent Technol* 1990/1991; 14:10-81.
- Williams JL. The temperamental selection of artificial teeth, a fallacy. *Dent Dig* 1914; 20:243-259.

Reprint requests: Gregory A. Kinzer, DDS, MSD, 600 Broadway, Suite 490, Seattle, WA, USA 98122; e-mail: gkinzer@seanet.com  
©2005 BC Decker Inc