

# Temporary Restoration of Maxillary Lateral Incisor Implant Sites

Guest Expert

**VINCENT G. KOKICH, DDS, MSD\***

Associate Editor

**EDWARD J. SWIFT, JR., DMD, MS**

When finishing orthodontic treatment for an adolescent patient who is missing a maxillary lateral incisor, and the eventual plan is to place an implant restoration in this site, some clinicians use a miniscrew with a provisional crown as an appropriate temporary restoration.

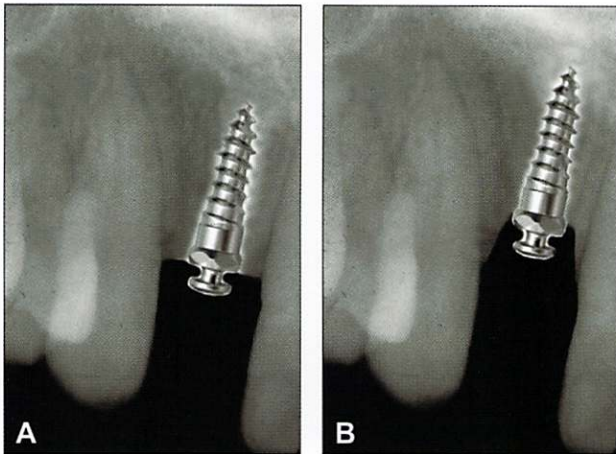
However, personally, I would not recommend placing a miniscrew in an adolescent orthodontic patient who will eventually receive an implant restoration to replace a missing maxillary lateral incisor. Two primary reasons support this perspective.

First, if the post-orthodontic patient were an adolescent between the ages of 15 and 20 years, we would expect continued facial growth until the patient reaches maturity.<sup>1,2</sup> This facial growth occurs primarily at the mandibular condyle. This is cartilaginous growth, similar to, but not exactly the same as growth of the long bones of the legs and arms. As the condyle/ramus grows in length, this creates interocclusal space between the maxillary and mandibular teeth. The teeth will erupt to fill this space as the patient continues to grow. As teeth erupt, the adjacent alveolar bone will move in the same direction as the teeth. This phenomenon occurs because of the force exerted by the periodontal ligament on the periosteum that covers the alveolar crest during the process of tooth eruption.<sup>3</sup> In the site of the missing maxillary lateral incisor, the eruption of the adjacent central incisor and canine will produce a similar stretching of the periosteum, allowing the alveolar crest to follow the teeth as they erupt.

However, if an implant or miniscrew were placed in this edentulous site in a growing adolescent, the head of the miniscrew would perforate the periosteum (Figure 1A). As the adjacent teeth erupt, the bone would follow the erupting teeth, except where the periosteum has been penetrated by the miniscrew. This would produce a vertical osseous defect in the crest of the alveolar ridge (Figure 1B). The younger the patient, the greater the growth potential, and therefore the greater the potential for a significant vertical alveolar defect. If surgeons or periodontists could predictably graft vertical alveolar defects, then this difference in ridge height would not be a serious problem. But the surgeons and periodontists that I have questioned tell me that vertical alveolar defects, especially in the esthetic zone, are difficult to overcome.

A second reason for avoiding a miniscrew and provisional crown as a temporary restoration is the lack of versatility of the miniscrew for restorative purposes. Traditional implant systems have a broad array of options for abutments upon which to cement or affix the porcelain crown. These abutments permit a gradual increase in the circumference of the restoration as it emanates from the alveolar crest to the level of the gingival region of the restoration. This gradual progression is called the emergence profile and it affects the esthetic appearance of the implant restoration. Most miniscrew systems do not have the capability to receive standard or custom abutments. Furthermore, if there were the possibility for a custom abutment, the diameter of the miniscrew is about 1.5 mm, whereas the

\*Professor, Department of Orthodontics, School of Dentistry, University of Washington, Seattle, WA 98195, USA, and Orthodontic Section Editor, JERD



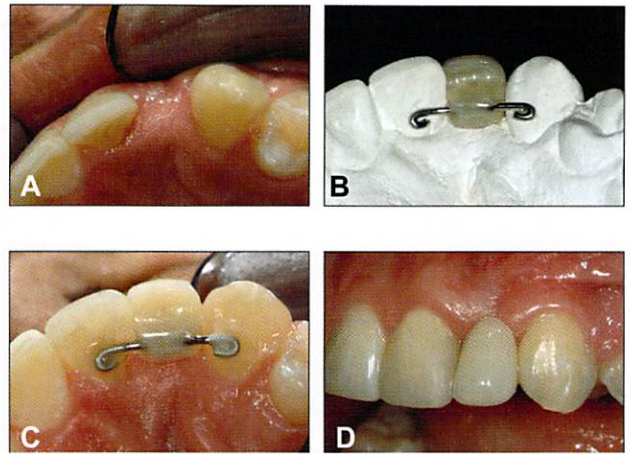
**FIGURE 1.** This simulation shows what would happen to the alveolar crest if an implant perforated the periosteum in a 15-year-old boy who was still experiencing active facial growth. As the condyle grows, the teeth erupt, causing the bone adjacent to the central incisor and lateral incisor to move incisally with the teeth. If a miniscrew perforates the periosteum (A), as the teeth erupt, the implant is left behind and vertical angular defects are created in the implant site (B).

traditional implant platform is about 4 mm wide. The emergence profile emanating from a narrow miniscrew could seriously compromise the esthetic appearance of the provisional crown.

Because of these two potential problems, I would avoid using a miniscrew and provisional crown in a maxillary lateral incisor implant site. I prefer to restore this area with a temporary bonded bridge (Figure 2) until the patient has completed facial growth and is at the appropriate age for a traditional implant and crown to replace the missing lateral incisor.

## REFERENCES

1. Heij D, Opdebeeck H, van Steenberghe D, et al. Facial development, continuous tooth eruption and mesial drift as compromising factors for implant placement. *Int J Oral Maxillofac Implants* 2006;21:867–78.
2. Fudalej P, Kokich V, Leroux B. Determining the cessation of vertical growth of the craniofacial structures to facilitate



**FIGURE 2.** A method of temporarily restoring a maxillary lateral incisor edentulous site is to place a temporary bonded bridge. This method will allow the adjacent teeth to erupt and also permit the alveolar crest to follow the teeth and move incisally under the influence of the periodontal ligament, which places a gradual incisally directed force on the periosteum.

placement of single-tooth implants. *Am J Orthod Dentofacial Orthop* 2007;131(Suppl):59–67.

3. Kokich VG. Maxillary lateral incisor implants. Planning with the aid of orthodontics. *J Oral Maxillofac Surg* 2004;62:48–56.

## EDITOR'S NOTE

If you have a question on any aspect of esthetic dentistry, please direct it to the Associate Editor, Dr. Edward J. Swift, Jr. We will forward questions to appropriate experts and print the answers in this regular feature.

Contemporary Issues  
 Dr. Edward J. Swift, Jr.  
 Department of Operative Dentistry  
 University of North Carolina  
 CB#7450, Brauer Hall  
 Chapel Hill, NC 27599-7450  
 Telephone: 919-966-2770  
 Fax: 919-966-5660  
 E-mail: ed\_swift@dentistry.unc.edu