

Esthetics and Anterior Tooth Position: An Orthodontic Perspective Part II: Vertical Position

VINCENT KOKICH, DDS*

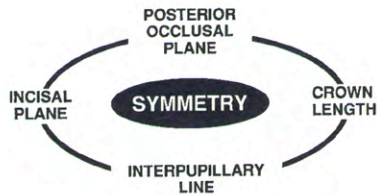


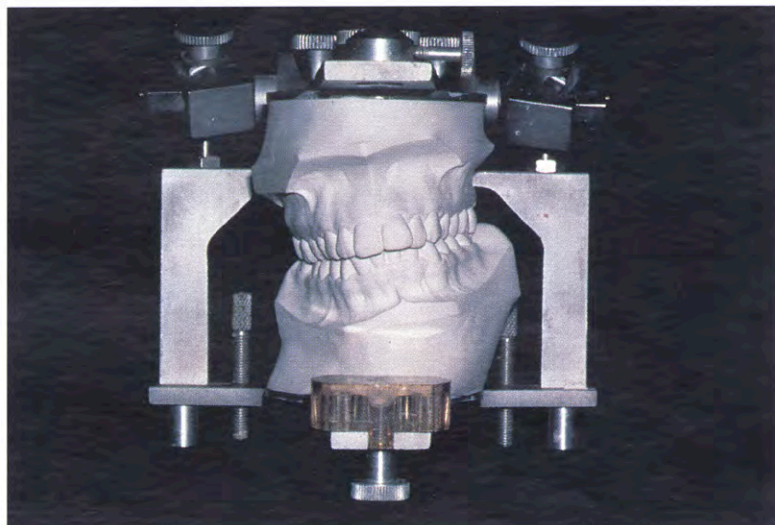
Figure 1. Symmetry in the maxillary incisal plane is based on the interrelationship of the posterior occlusal plane, the incisal plane, the interpupillary line, and the crown lengths of the maxillary central and lateral incisors.

Orthodontics plays a major role in dental esthetics. In Part I of this series the evaluation and treatment of discrepancies in crown length were discussed. Part II describes the assessment and correction of vertical malposition of the maxillary anterior teeth.

INCISAL PLANE DISCREPANCIES

Discrepancies in the maxillary anterior incisal plane have various causes. The treatment of these problems may require surgical movement of the maxilla, orthodontic intrusion or extrusion of the incisors, or orthodontics in combination with restorative care. The correct solution depends on the interrelationship of the following four factors:

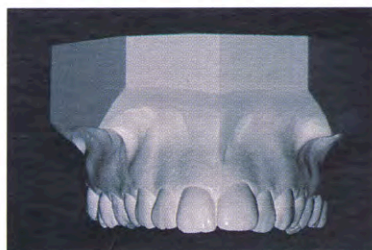1. Posterior occlusal plane,
2. Incisal plane,
3. Interpupillary line, or
4. Crown length of the maxillary incisors (Figure 1).



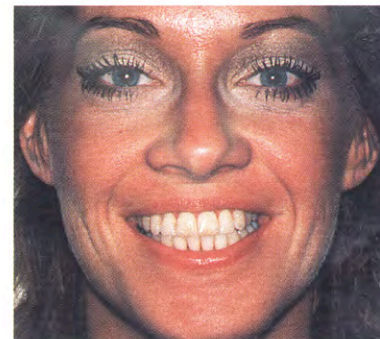A



B



C

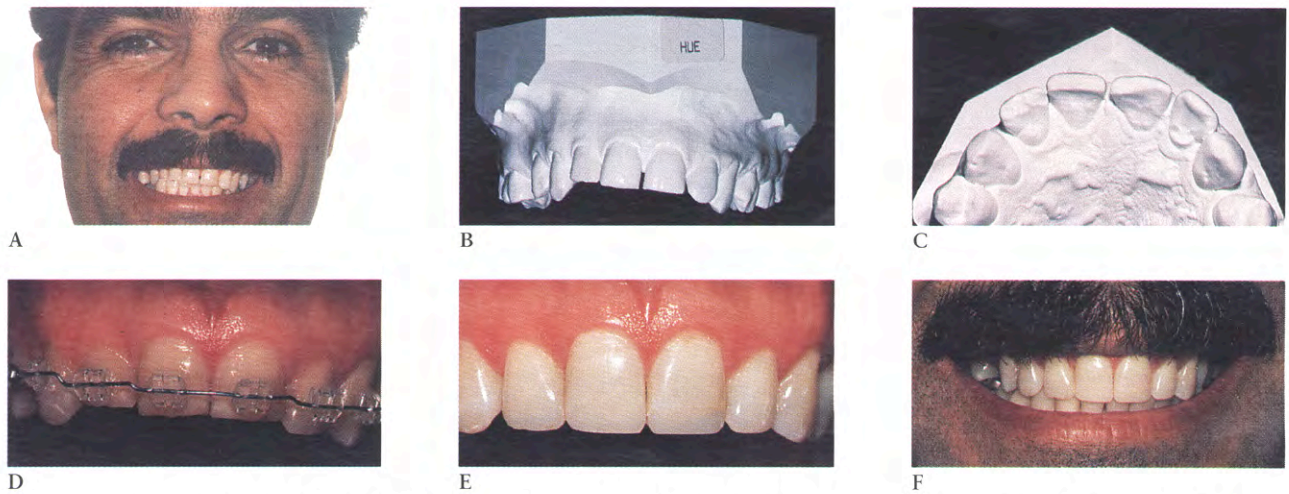


D

Figures 2A to 2D. A and B, The maxillary incisal plane deviates from the interpupillary line. C, The incisal plane coincides with the posterior occlusal plane indicating uneven growth of the mandibular rami. D, Postoperative correction of maxilla.

*Professor and Director, Graduate Orthodontic Research, University of Washington School of Dentistry, Seattle, Washington

Esthetics and Anterior Tooth Position: An Orthodontic Perspective. Part II: Vertical Position



Figures 4A to 4F. The incisal plane does not coincide with the occlusal plane or the interpupillary line. The incisal edges on the right side have been worn due to an anterior crossbite. Leveling the gingival margins orthodontically is followed by restoration of the incisal edges.

GUMMY SMILE

The correction of an excessive display of gingival tissue and mucosa during smiling may require surgery, orthodontics, restorative dentistry, or a combination thereof depending on the interrelationship of the posterior occlusal plane, the incisal plane, the crown lengths of the maxillary incisors, and the level of the maxillary incisor gingival margins (Figure 5).

If a gummy smile occurs when the incisal and occlusal planes are coincident, correction usually requires maxillary surgery due to vertical overdevelopment of the maxilla. Removal of a wedge of bone permits intrusion of the maxilla to its proper position (Figures 6A to 6C).

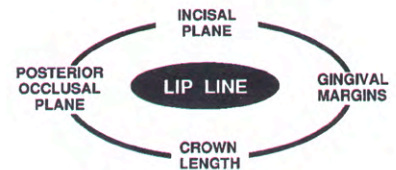
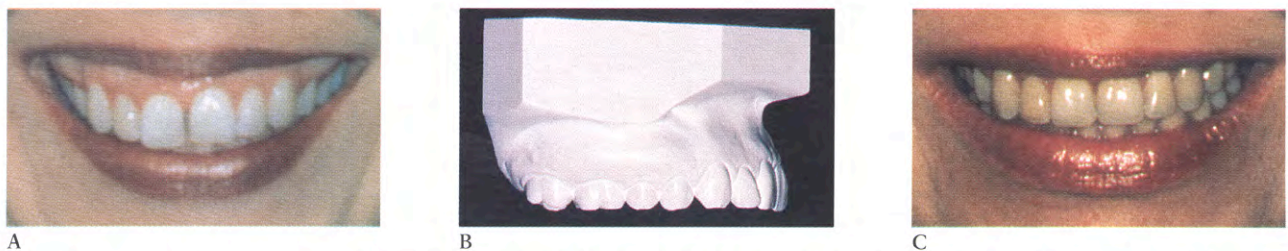


Figure 5. Lip line discrepancies are a function of the maxillary incisal and occlusal planes, the gingival margins of the maxillary teeth, and the crown lengths of the maxillary incisors.

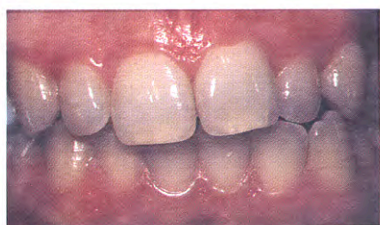

Figures 6A to 6C. This patient displays a gummy smile, but the incisal and occlusal planes are coincident. The maxilla was intruded to eliminate the gingival display.

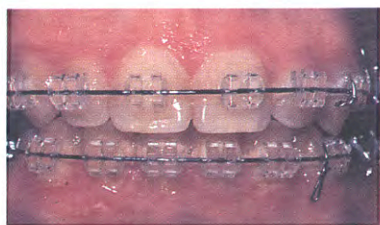

A

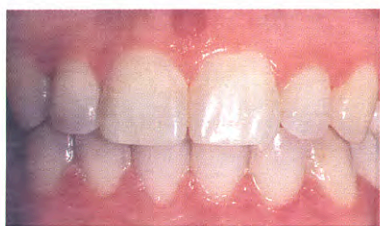Figures 3A to 3D. If the incisal plane and the occlusal plane are not coincident, but the crown lengths of the central and lateral incisors are bilaterally symmetrical, orthodontics are indicated to level the incisal plane. Note that the maxillary incisal plane deviates from the interpupillary line preoperatively.



B



C

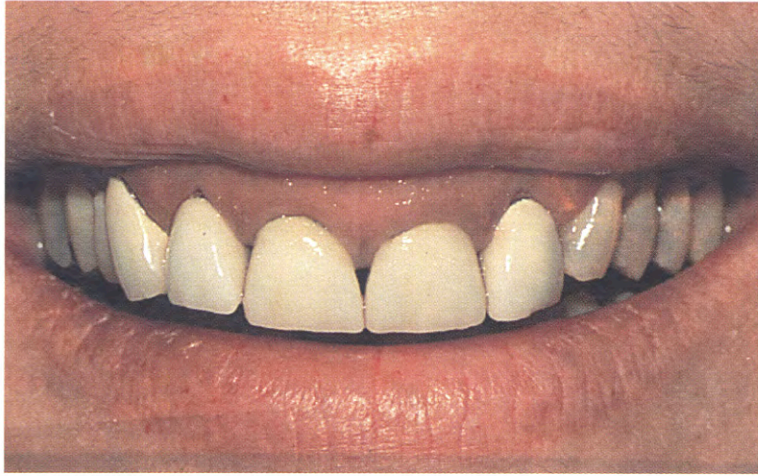

D

If the maxillary incisal plane deviates from the interpupillary line, but coincides with the maxillary occlusal (posterior) plane, the entire maxilla developed asymmetrically (Figures 2A to 2D) due to uneven growth of the mandibular rami. This causes the maxillary teeth on one side of the arch to erupt more than the other. This problem cannot be treated orthodontically. It requires maxillary surgery to intrude the maxilla on the overerupted side, level the occlusal and incisal planes, and correct the vertical discrepancy.

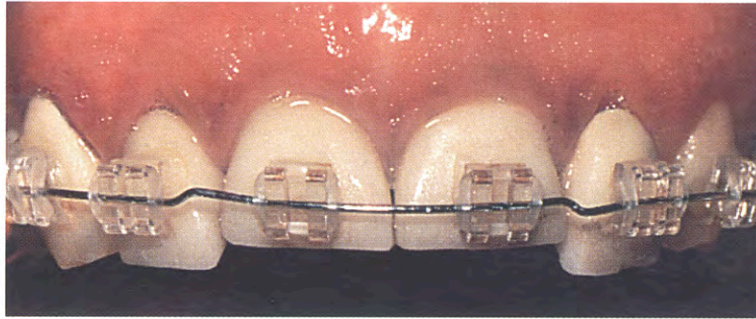
If the maxillary incisal plane deviates from the interpupillary line and does not coincide with the maxillary occlusal (posterior) plane, the problem does not require surgery. If the lengths of the right and left centrals are bilaterally symmetrical, then the problem can be corrected orthodontically by extruding or intruding teeth (Figures 3A to 3D).

If the posterior occlusal plane coincides with the interpupillary line, but the incisal plane deviates from both of these landmarks, and the lengths of the central and lateral incisors are uneven, there has been oblique wear of the anterior teeth requiring restorative care following completion of the orthodontics (Figures 4A to 4F).

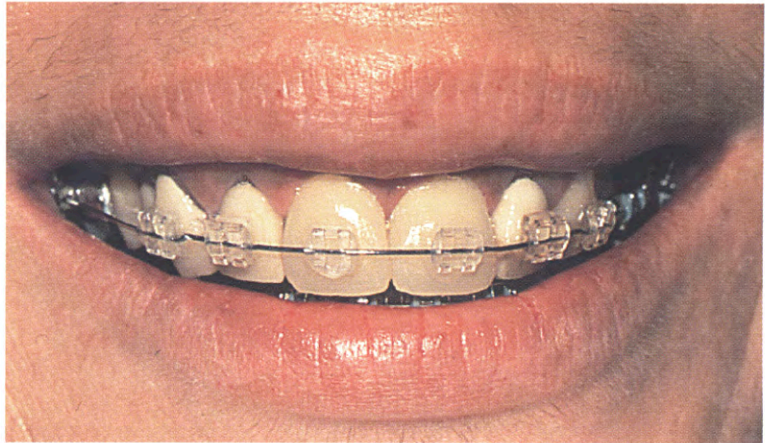


A

Figures 8A to 8C. The gummy smile in this patient is due to overeruption of the incisors, with a step between the incisal and occlusal planes. Since the incisors are short, orthodontic intrusion will eliminate the gingival display, but restorative dentistry is necessary to recreate the proper crown length.

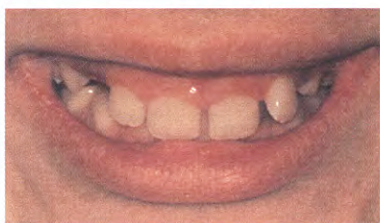

B

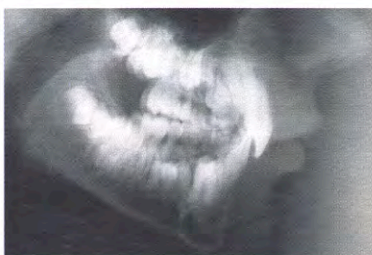


C

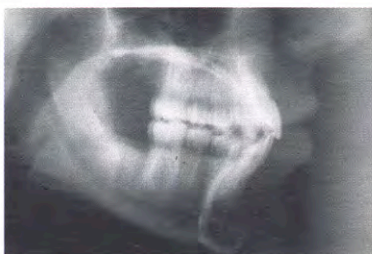
Reprint requests: Vincent Kokich, DDS,
Director, Graduate Orthodontic Research,
University of Washington School of
Dentistry, Seattle, WA 98095.
© 1993 Decker Periodicals Inc.



A

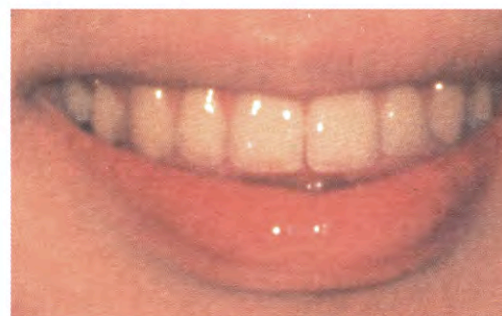

B



C

Figures 7A to 7D. This patient has a gummy smile due to over-eruption of the maxillary incisors. A step exists between the incisal and occlusal planes. The maxillary incisors were intruded coincident to the occlusal plane, thereby reducing the gingival display.



D

Maxillary anterior teeth can over-erupt creating a deep overbite and a different type of gummy smile in which there is a step between the incisal and occlusal planes. If the incisal edges are not abraded, the maxillary incisors are intruded orthodontically, simultaneously moving the gingival margins apically, thereby reducing the amount of gingiva visible upon smiling (Figures 7A to 7D).

If the maxillary incisors are over-erupted in the presence of a protrusive bruxing habit, a gummy smile may develop with short abraded incisors. Orthodontic intrusion of the short teeth is followed by restoration of the incisal edges to improve the incisor crown lengths (Figures 8A to 8C).

SUMMARY

This article discusses the vertical position of the maxillary incisors and its relationship to esthetics. Two situations are discussed. The first, a discrepancy between the incisal plane and the interpupillary line, is corrected by maxillary surgery, orthodontic intrusion/extrusion, or orthodontics and restorative dentistry. The correct decision depends on the interrelationship of the posterior occlusal plane, incisal plane, interpupillary line, and the crown length of the incisors.

The second discrepancy in the vertical position of the maxillary incisors is the "gummy" smile. This problem, due to either overdevelopment of the entire maxilla or over-eruption of the maxillary incisors, is solved by maxillary surgery, orthodontic intrusion of the over-erupted teeth, or orthodontics and restorative dentistry. The proper choice of treatment depends on the interrelationship of the posterior occlusal plane, incisal plane, crown length of the maxillary incisors, and the level of the gingival margins of the maxillary anterior teeth.