

Managing Treatment for the Orthodontic Patient With Periodontal Problems

David P. Mathews and Vincent G. Kokich

Some adult patients have mild to moderate periodontal disease before orthodontic treatment. These patients may be at risk of developing further periodontal breakdown during orthodontic therapy. However, careful diagnosis and judicious management of these potentially volatile patients can alleviate the risk. In this article, the diagnosis and management of several periodontal problems is discussed. The need for and timing of preorthodontic periodontal surgery for these situations is elucidated. In addition, the types of tooth movement that will ameliorate these problematic situations is described. This information is valuable for the orthodontist who treats patients with underlying periodontal problems. (Semin Orthod 1997;3:21-38.) Copyright © 1997 by W.B. Saunders Company

Most orthodontic patients are children and adolescents between the ages of 8 and 16 years. Except in unusual situations, younger patients generally have a healthy periodontium. Although some uncooperative patients may develop gingival inflammation, the majority of children and adolescents do not experience alveolar bone loss during orthodontics. Currently, orthodontists are treating more adult patients. The percentage of adults in some orthodontic offices is more than 40%. Many of these patients have underlying periodontal problems that could become worse during orthodontic therapy. It is important for orthodontists to identify periodontal problems before orthodontic treatment, determine the correct treatment plan to ameliorate these problems, and sequence the orthodontic and periodontal therapy correctly to enhance the patient's periodontal health. This article describes the responsibilities of orthodontists for diagnosing periodontal problems and discusses the interdisciplinary management of several periodontal problems requiring orthodontic intervention.

From the Department of Orthodontics, School of Dentistry, University of Washington, Seattle, WA.

Address correspondence to Vincent G. Kokich, DDS, MSD, Department of Orthodontics, School of Dentistry, University of Washington, Seattle, WA 98195.

Copyright © 1997 by W.B. Saunders Company
1073-8746/97/0301-0003\$5.00/0

Periodontal Examination by the Orthodontist

Because orthodontists are treating more adult patients, they must take an active role in diagnosing periodontal problems before initiating orthodontic treatment. The orthodontist should incorporate a cursory 5 minute periodontal examination during the initial consultation with the patient. This is a simple screening examination. If problems are discovered, then referral to a periodontist for a more detailed diagnosis is appropriate. The screening examination involves probing key indicator teeth, evaluating attached gingiva, and studying appropriate radiographs.

Periodontal Screening and Recording

Periodontal screening and recording (PSR) is a rapid and effective method to screen adult patients for periodontal diseases.¹ It summarizes necessary information with minimum documentation. A special small plastic probe is used to assess each sextant. A score is given for each area and a summary chart will help the examiner to determine whether further periodontal examination and treatment are necessary. PSR is easy to carry out and understand and is a highly sensitive technique for detecting deviations from periodontal health. It can be readily incorporated into routine oral examinations without increasing appointment time.

Periodontal Probing

Another means of detecting periodontal disease is to use a standard periodontal probe.² The Michigan "O" and the Marquis probe are thin, and easy to read and record measurements. Common areas for periodontal disease in adults are found in the upper molar interproximal regions, buccal furcations, and in the lower canine/lateral area, especially in patients with crowding.³ It is important to find the depth of the interproximal osseous defect, and this can be achieved with proper angulation of the probe (Fig 1). Radiographs can also help delineate areas that should be evaluated with the probe.

Attached Gingiva

Areas of minimal gingiva can be easily evaluated by one of two simple techniques. First, a periodontal probe can be used horizontally in the vestibule and gently raised toward the gingiva to delineate the mucogingival junction. The width of gingiva can be measured with a probe. Areas with less than 2 mm of gingiva will require further evaluation by the periodontist.⁴ Another technique to assess the amount of gingiva is to use light finger touch in the vestibule and ruffle the mucosal tissue to assess the mucogingival junction and amount of gingiva. Delineation of the mucogingival junction is more difficult in patients with inflammation and very thin mucosal-like tissue (Fig 2B). Patients with a very thin periodontium and prominent roots are candidates for further evaluation.

Radiographs

Most orthodontists use a panoramic radiograph which is excellent for generalized screening. However, panoramic radiographs are not as diag-

nostic as a vertical bitewing radiograph for the evaluation of periodontal osseous lesions. Common areas that are missed on the panoramic radiograph are interproximal craters between upper molars, infrabony defects on the mesial of the upper first bicuspid, and defects around the lower incisors. In adult patients with moderate to advanced periodontal disease, regular bitewings are of minimal diagnostic value. A vertical bitewing is more diagnostic and will show the crestal bone more clearly.

Parafunction

It is extremely important for the orthodontist to identify those adult patients who may be bruxers or clenchers. A cursory evaluation of advanced mobility is imperative. Clenchers and bruxers can cause extensive osseous breakdown during orthodontic therapy.⁵ These patients may need a biteplate appliance (nightguard) while they are undergoing active orthodontic treatment.

Preorthodontic Periodontal Therapy

Preorthodontic periodontal therapy is directed toward the etiologic factors including plaque, subgingival calculus, and occlusal trauma. The initial phase of periodontal treatment involves an individualized home-care program. Use of an automatic toothbrush (Oral B [Braun, Lynnfield, MA]; Sonicare [Optiva Corp; Bellevue, WA]; or Interplak [Bausch & Lomb, Tucker, GA]) may be recommended for patients with compromised home-care ability.

Root planing and subgingival debridement are performed to help diminish inflammation, bleeding, and suppuration. This initial stage of treatment is usually about 3 months. Occasion-

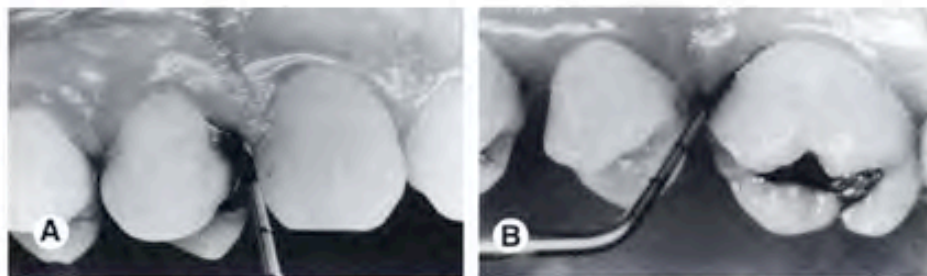


Figure 1. The orientation of the probe is important. The probe should be directed into the interproximal and along the long-axis of the root to determine accurate sulcular depths (A and B).

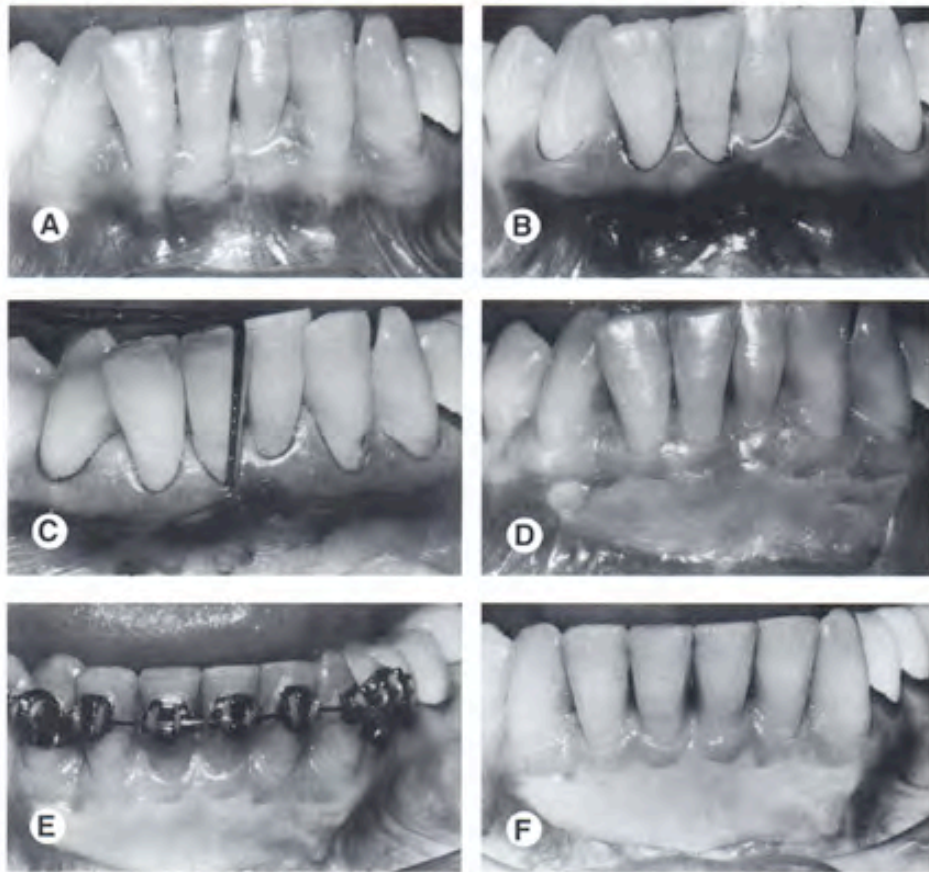


Figure 2. Evaluation of amount of attached gingiva. Before orthodontic treatment (A) the patient had moderate crowding. Staining of the gingiva with Schiller's solution (B) showed minimal gingiva labial to the mandibular right central incisor. Periodontal sounding of the bone (C), showed a 5 mm depth signifying a dehiscence over this tooth. A gingival graft was placed before orthodontic therapy (D), which helped to prevent gingival recession during (E) and after orthodontic treatment (F).

ally an antibiotic is used, especially in more refractory periodontal diseases. The patient is reevaluated a few months after this initial debridement, and the tissue response is assessed. Disease activity is evaluated. Usually there will be a significant decrease in bleeding, suppuration, and pocket depth.⁶ The periodontist will determine if the patient is stable enough periodontally to proceed with orthodontic treatment. Some areas in the mouth may require periodontal surgical treatment before the initiation of orthodontic treatment.

Preorthodontic Gingival Surgery

Gingiva Grafting

Areas of minimal attached gingiva should be evaluated by the periodontist before initiating orthodontic treatment. Teeth with less than 2 mm of gingiva may require grafting (Fig 2). However, there are some factors that need to be considered in making this decision.⁷ The periodontist can "sound" these areas of thin, narrow gingiva to ascertain the attachment and bone level (Fig 2). This is performed with a thin

probe, inserted in the sulcus and gently pressed through the attachment apparatus to the labial crest of the bone. Teeth with underlying dehiscences are more prone to recession and loss of attachment.

Other factors such as home care, gingival inflammation, and the direction of proposed tooth movement will influence the decision to graft in areas of minimal gingiva. During orthodontic treatment there is a greater likelihood of inflammation because of compromised home care access around orthodontic appliances. Areas of minimal gingiva that are inflamed are at greater risk for attachment loss.

Teeth that will be proclined orthodontically have a greater risk of recession.⁸ As the tooth is moved labially, a bony dehiscence could be created. When areas of minimal gingiva lose their underlying bony scaffold, there is a greater risk of subsequent recession.⁹ Also, teeth with prominent roots have a higher incidence of recession through mechanical and toothbrush trauma.

All of these factors need to be considered by the periodontist in treatment planning. The prudent therapist will weigh the combination of these factors to decide what is best for the patient. The benefits of grafting far outweigh the disadvantages. Often, areas that were grafted will have coronal "creeping attachment" of the gingival margin when evaluated years later¹⁰ (Fig 2E).

Gingival Recession and Root Coverage

Areas of recession and root exposure can be predictably covered with various grafting techniques.¹¹ Gingival grafting and pedicle grafting were the traditional methods for root coverage. At the present time the connective tissue graft has become the treatment of choice to cover denuded roots.¹² The connective tissue graft gives a greater degree of root coverage, is more esthetic, and the procedure is less traumatic than conventional gingival grafting.

If grafting procedures are done for cosmetic reasons, it is best to perform them when orthodontic treatment has been completed. However, if the area has recession and inadequate gingiva, then the procedure may be done before or during orthodontic treatment (Fig 3). The decision to perform a root coverage procedure is

based on esthetics, tooth sensitivity, the depth of erosion in the root, the presence of composite gingival restorations, and the patient's wishes concerning the esthetic outcome.

Preorthodontic Osseous Surgery

The extent of the osseous surgery will depend on the type of defect, ie, crater, hemiseptal defect, three-walled defect, and/or furcation lesion. The prudent therapist will know which defects can be improved with orthodontic treatment and which defects will require preorthodontic periodontal surgical intervention.

Osseous Craters

An osseous crater is an interproximal two-wall defect that will not improve with orthodontic treatment. Some shallow craters (4 to 5 mm pocket) may be maintainable nonsurgically. However, if the periodontist believes that surgical correction is necessary, this type of osseous lesion can easily be eliminated by reshaping the defect and reducing the pocket depth^{13,14} (Fig 4). This in turn will enhance the ability to maintain these interproximal areas during orthodontic treatment. The need for surgery is based on the patient's response to initial treatment, the patient's periodontal resistance, the location of the defect and the predictability of maintaining defects nonsurgically while the patient is wearing orthodontic appliances.

Three-Wall Intrabony Defects

Three-wall defects are amenable to pocket reduction with regenerative periodontal therapy.¹⁵ Bone grafts using either autogenous bone from the surgery site, or allografts, along with the use of resorbable or nonresorbable membranes have been very successful in filling three-wall defects.¹⁶ Buccal and lingual flaps are reflected, and the osseous defect is debrided (Fig 5). The root is prepared with an appropriate material, either citric acid, ethylene diaminetetraacetic acid (EDTA), or tetracycline. The bone graft is packed into the defect, the membrane is placed over the site, and the flaps are returned to their original location. If a nonresorbable membrane is used, it must be removed in 4 to 6 weeks. After membrane removal, another 2 to 3 months is necessary for further maturation of the graft. At

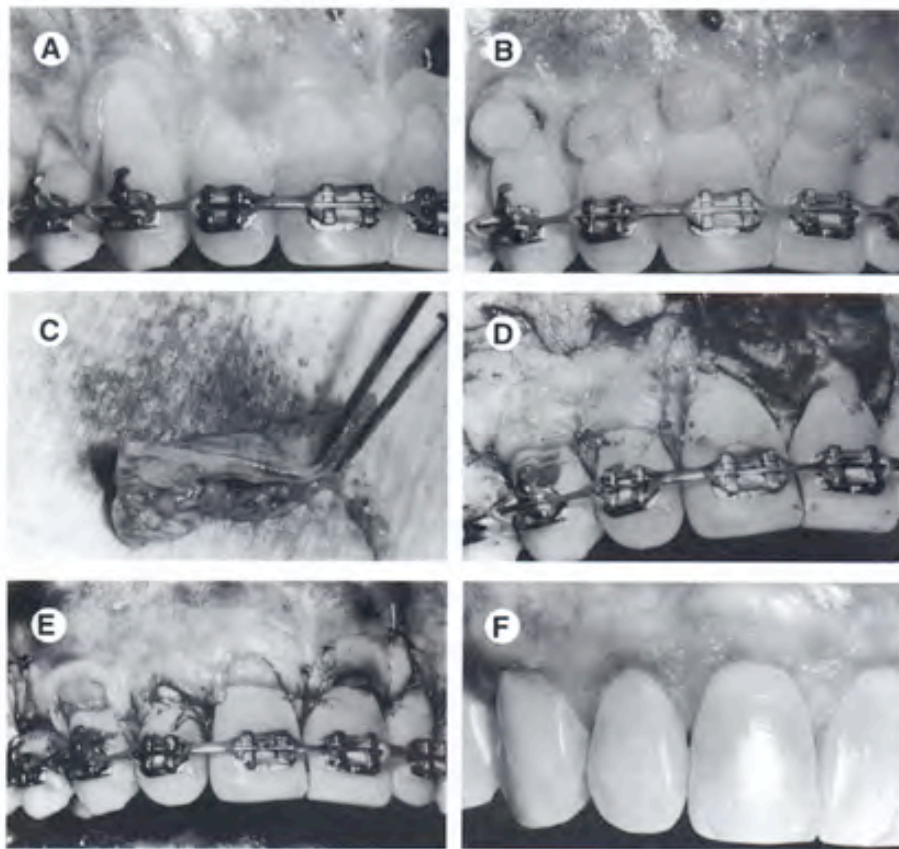


Figure 3. This patient had significant recession (A). During orthodontics, the root surface was etched (B) and connective tissue was obtained from the palate (C) and placed over the etched roots (D). The flap was replaced (E) and the postorthodontic photograph shows complete coverage of the denuded roots (F).

this time, the sulcular depth is reevaluated and a periapical radiograph is made to assess the amount of bone regeneration. If the patient remains periodontally stable over the next 3 to 6 months, the orthodontic phase of therapy can be initiated.

Hemiseptal Defects

Hemiseptal defects are one to two wall osseous defects. These are often found around mesially tipped teeth or teeth that have supererupted. Often these defects can be eliminated with appropriate orthodontic treatment. In the case of the

tipped tooth, uprighting and eruption of the tooth will level the bony defect^{17,18} (Fig 6). In the case of the supererupted tooth, intrusion and leveling of the adjacent cemento-enamel junctions (CEJs) can help level the osseous defect.

It is imperative that periodontal inflammation be controlled before orthodontic treatment. This can usually be achieved with initial debridement and rarely requires any preorthodontic surgery. After the completion of orthodontic treatment, these teeth should be stabilized for at least 6 months and reassessed periodontally. Often, the pocket has been reduced or eliminated, and no further periodontal treatment is needed. It would

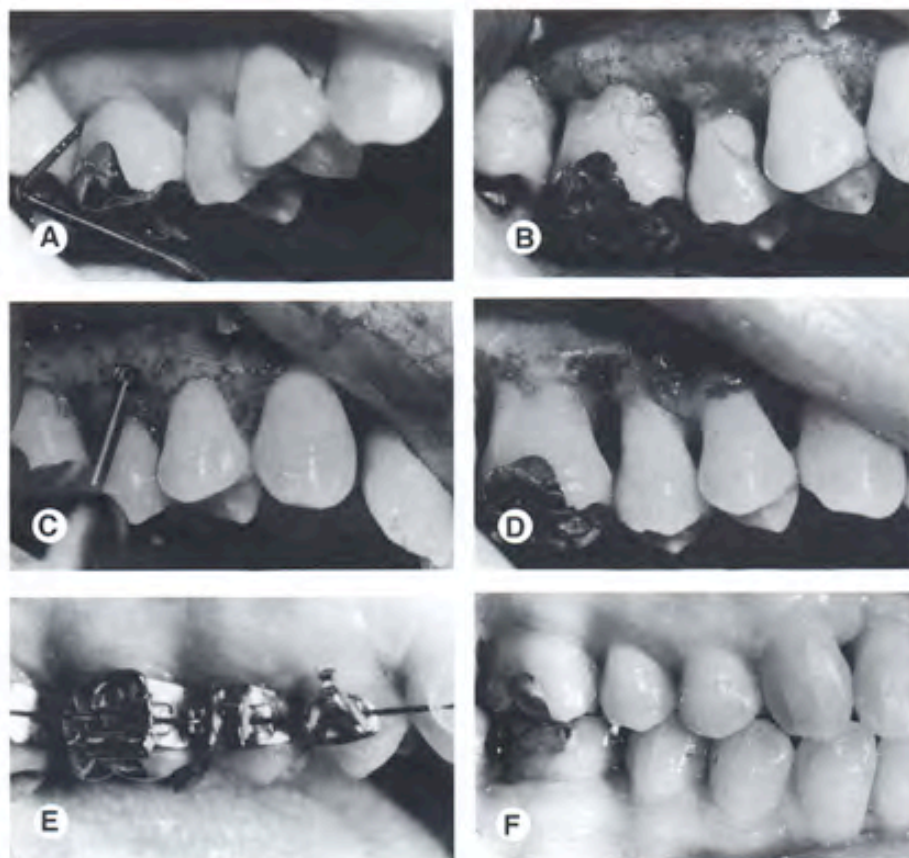


Figure 4. Before orthodontic treatment (A), this patient had a 5 mm pocket distal to the maxillary right first molar. This defect did not improve after preorthodontic periodontal therapy. A flap was elevated (B), revealing a crater mesial to the maxillary right first molar. Osseous resective surgery was performed (C and D) to eliminate the osseous defect. Surgical elimination of the crater helped to improve the patient's ability to clean interproximally during (E), and after orthodontic treatment (F).

be injudicious to do preorthodontic osseous corrective surgery in lesions such as these if orthodontics is a part of the overall treatment plan.

Furcation Defects

Furcation defects can be classified as incipient (Class I), moderate (Class II) and advanced (Class III). These lesions require special attention in the patient undergoing orthodontic treatment. Often the molars will require bands with tubes and other attachments which will impede

the patient's access to the buccal furcation for home care and instrumentation at the time of recall (Fig 4E).

Class I defects are amenable to osseous surgical correction with a good prognosis. Class II furcation defects can be treated with grafting and regenerative therapy with barrier membranes. Class III furcation defects are more difficult to treat and use of grafting and membranes in these lesions is not as predictable. Treatment of Class III furcation lesions in the lower arch can range from open-flap-curettage

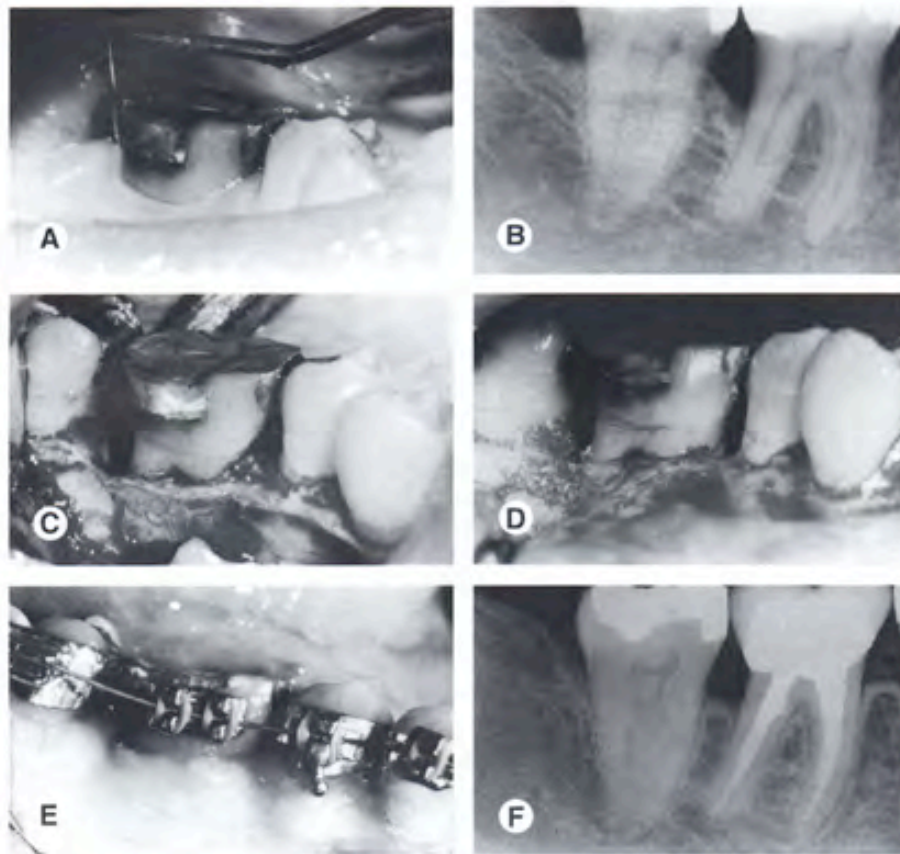


Figure 5. This patient had a significant periodontal pocket (A) distal to the mandibular right first molar. A periapical radiograph (B) confirmed the osseous defect. A flap was elevated (C) revealing a deep three-wall osseous defect. Freeze-dried bone (D) was placed in the defect. Six months after the bone graft, orthodontic treatment was initiated (E). The final periapical radiograph shows that the preorthodontic bone graft helped to regenerate bone and eliminate the defect distal to the molar (F).

to create a through and through furcation for easier cleaning, to hemisection, or even extraction and replacement with an implant.¹⁹ In the upper arch, Class II and III furcations can sometimes be treated with root amputation. The most favorable root to remove is the distobuccal root of an upper molar. This treatment has a good prognosis. The disadvantage of root amputation is that it requires endodontic therapy and full-coverage restoration.

Furcation lesions need special attention because they are the most difficult lesions to

maintain and can worsen during orthodontic therapy. These patients will need to be maintained on a 2 to 3 month recall schedule. Detailed instrumentation of these furcations will help minimize further periodontal breakdown.

Root Proximity

Areas of root proximity are difficult for the patient to clean and restrict the hygienist during periodontal maintenance.²⁰ They are also very difficult to prepare when interproximal areas

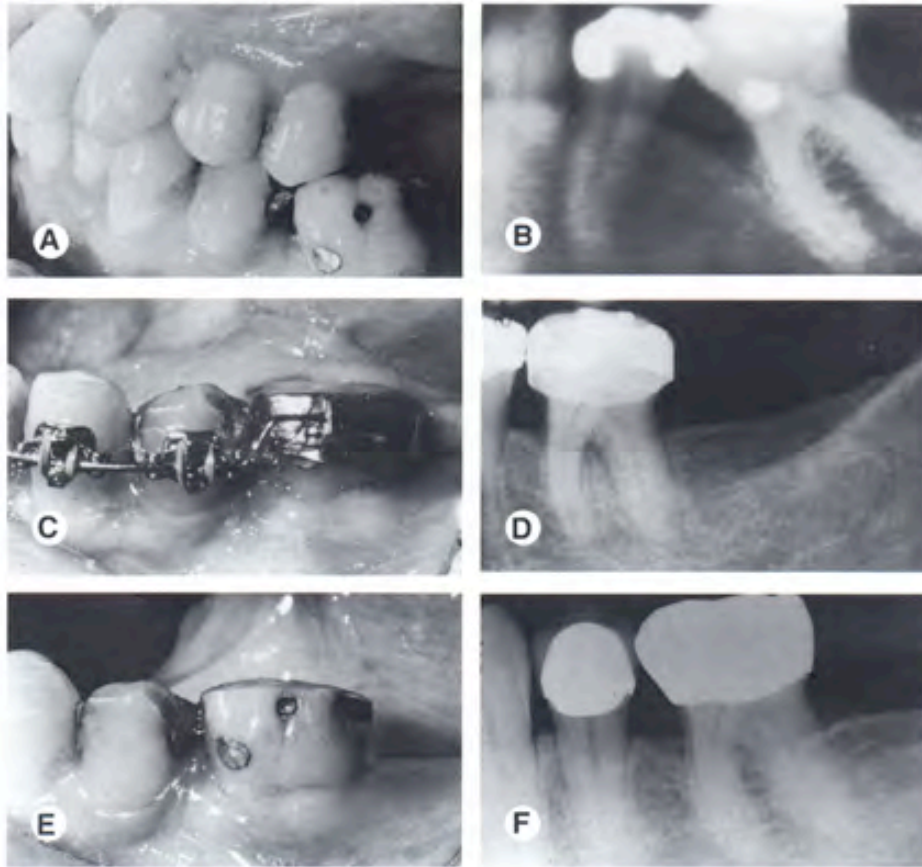


Figure 6. This patient was missing the mandibular left second premolar and the first molar had tipped mesially (A). A pretreatment periapical radiograph (B) revealed a significant hemiseptal osseous defect on the mesial of the molar. To eliminate the defect, the molar was erupted and the occlusal surface was equilibrated (C). The eruption was stopped when the bone defect was leveled (D). The posttreatment intraoral photograph (E) and periapical radiograph (F) show that the periodontal health had been improved by correcting the hemiseptal defect orthodontically.

need to be restored. Generally, anterior teeth are easier to maintain with a root proximity because of access and the narrower buccolingual width of the alveolus.

However, in the upper molar region, a root proximity problem is more difficult to maintain. Access for home care, and a wider buccolingual width make these areas more prone to osseous breakdown. Root proximity can be exacerbated when a molar supererupts. The distobuccal root of an upper first molar can touch the mesiobuccal root of the upper second molar creating a

difficult situation to treat surgically without root amputation. However, with appropriate orthodontic treatment, this situation can be corrected without periodontal surgery by intruding the first molar, leveling the bone, and opening up the embrasure space between the first and second molar roots.

In a very crowded situation in the upper or lower anterior region, simply unraveling the rotated teeth will improve the embrasure form and simplify home care and instrumentation. Also, if any ceramic restorations are to be placed

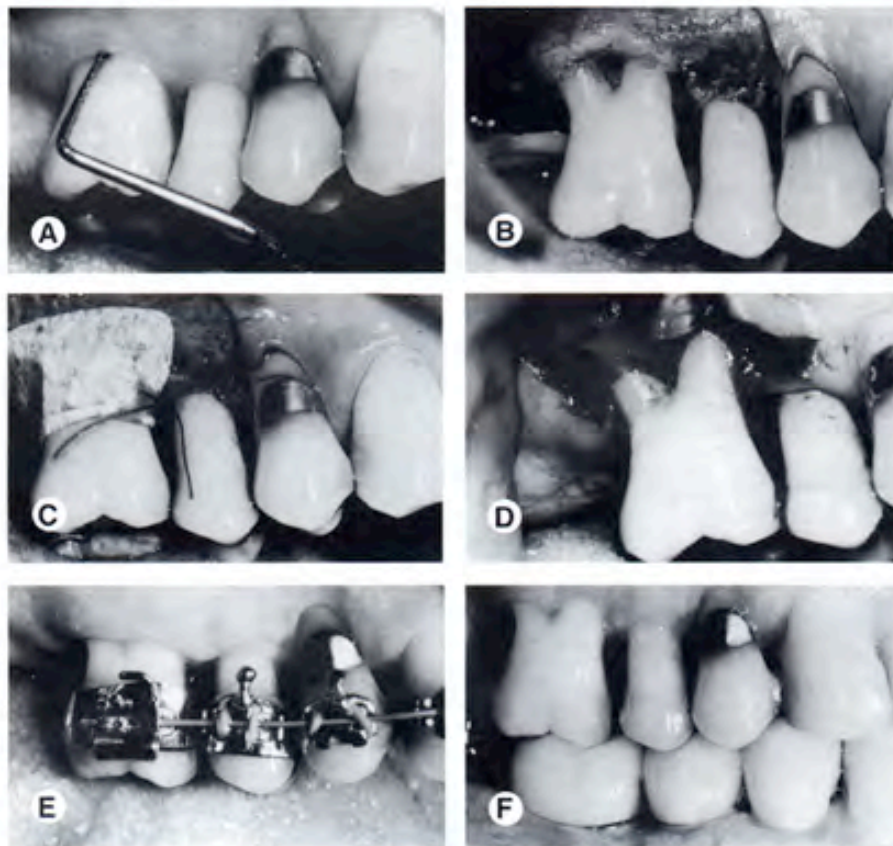


Figure 7. This patient had a 5 mm probing defect in the furca of the maxillary right first molar (A). When this area was flapped (B), the extent of the defect was apparent. A polytetrafluoroethylene membrane was placed over the defect (C) and the flap was sutured. After 6 weeks, the area was opened (D) showing that osteoid had filled in the furcation defect. The furcation remained closed during (E) and after orthodontic therapy (F).

after orthodontic treatment, this will facilitate the restorative procedures. It will also help maintain a more normal, healthy, and esthetic papillary form.

Orthodontic Treatment of Periodontal Defects

Advanced Horizontal Bone Loss

After the treatment has been planned, one of the most important factors that determines the outcome of orthodontic therapy, is the location of

the bands and brackets on the teeth. In a periodontally healthy individual, the position of the bracket is usually determined by the anatomy of the crown of the tooth. Anterior brackets should be positioned relative to the incisal edges. Posterior bands or brackets are positioned relative to the marginal ridges. If the incisal edges and marginal ridges are at the correct level, the CEJs will also be at the same level. This relationship will create a flat bony contour between the teeth. However, if a patient has underlying periodontal problems and significant alveolar bone loss around certain teeth, using the anatomy of

the crown to determine bracket placement is inappropriate.

In a patient with advanced horizontal bone loss, the bone level may have receded several millimeters from the CEJ. As this occurs, the crown to root ratio will become less favorable. By aligning the crowns of the teeth, the clinician may perpetuate tooth mobility by maintaining an unfavorable crown to root ratio. In addition, by aligning the crowns of the teeth and disregarding the bone level, there will be significant bony

discrepancies between healthy and periodontally diseased roots. This could require periodontal surgery to ameliorate the discrepancies.

The orthodontist can correct many of these problems by using the bone level as a guide to positioning the brackets on the teeth. In these situations, the crowns of the teeth may require considerable equilibration (Fig 8). If the tooth is vital, the equilibration should be performed gradually to allow the pulp to form secondary dentin to insulate the tooth during the equilibra-

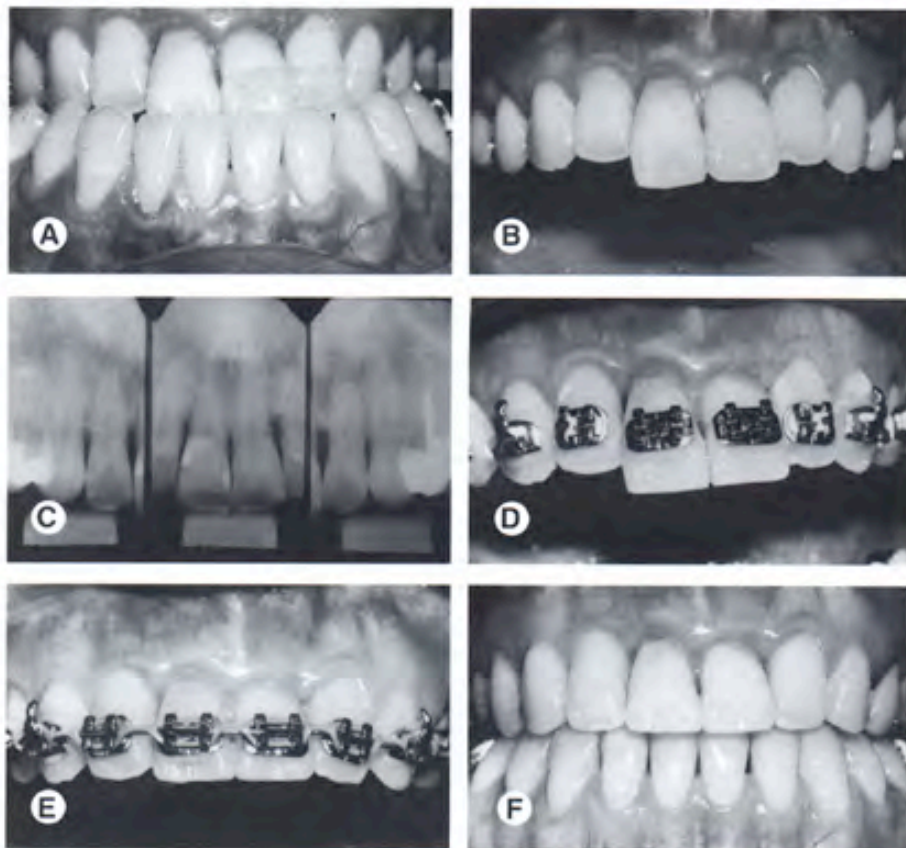


Figure 8. Before orthodontic treatment, this patient had a significant Class III malocclusion (A). The maxillary central incisors had overerupted (B) relative to the occlusal plane. A pretreatment periapical radiograph (C) showed that significant horizontal bone loss had occurred. To avoid creating a vertical periodontal defect by intruding the central incisors, the brackets were placed to maintain the bone height (D). The incisal edges of the centrals were equilibrated (E) and the orthodontic treatment was completed without intruding the incisors (F).

tion process. The goal of equilibration and creative bracket placement is to provide a more favorable bony architecture as well as a more favorable crown to root ratio. In some of these patients, the periodontal defects that were apparent initially may not require periodontal surgery following orthodontic treatment.

Hemiseptal Defect

In the periodontally healthy patient, orthodontic brackets are positioned on the posterior teeth relative to the marginal ridges and cusps. However, some adult patients may have marginal ridge discrepancies caused by uneven tooth eruption before orthodontic treatment. When the orthodontist encounters marginal ridge discrepancies, the decision as to where to place the bracket or band is not determined by the anatomy of the tooth. In these situations, it is important for the orthodontist to assess bite wing or periapical radiographs of these teeth in order to determine the bone level interproximally.

If the bone level is oriented in the same direction as the marginal ridge discrepancy, then leveling the marginal ridges will level the bone. However, if the bone level is flat between adjacent teeth and the marginal ridges are at significantly different levels, correction of the marginal ridge discrepancy orthodontically will produce a hemiseptal defect in the bone. This could cause a periodontal pocket between the two teeth.

If the bone is flat and a marginal ridge discrepancy is present, the orthodontist should not level the marginal ridges orthodontically (Fig 9). In these situations, it may be necessary to equilibrate the crown of the tooth. In some patients, the latter may require endodontic therapy and restoration of the tooth resulting from the amount of reduction of the length of the crown that is required. This approach is acceptable, if the treatment results in a more favorable bony contour between the teeth.

In some patients, a discrepancy may exist between both the marginal ridges and the bone levels between two teeth (Fig 10). These discrepancies may however not be of equal magnitude. In these patients, orthodontic leveling of the bone may still leave a discrepancy in the marginal ridges. In these situations, the clinician must not use the crowns of the teeth as a guide for completing orthodontic therapy. The clinician

should level the bone orthodontically and equilibrate any remaining discrepancies between the marginal ridges. This method will produce the best occlusal result and improve the periodontal health.

During orthodontic treatment, when teeth are being extruded to level hemiseptal defects, the patient should be regularly monitored by the periodontist. Initially, the hemiseptal defect will have a greater sulcular depth and be more difficult for the patient to clean. As the defect is ameliorated through tooth extrusion, interproximal cleaning becomes easier. The periodontist should recall the patient every 2 to 3 months during the leveling process to control inflammation in the interproximal region.

Furcation Defects

Regenerative therapy using polytetrafluoroethylene membranes and/or bone grafting, has been successful in Class I and II furcations. However, in Class III furcations, the use of membranes has not produced consistently satisfactory results. Therefore, another method of treatment must be used for orthodontic patients with Class III furcations in the mandibular arch.

If a patient with a Class III furcation defect will be undergoing orthodontic treatment, a possible method for treating the furcation is to eliminate it by hemisecting the crown and root of the tooth. This procedure will, however, require endodontic, periodontic, and restorative treatment. If the patient will be undergoing orthodontic treatment, it is advisable to perform the orthodontic treatment first. This is especially true if the roots of the teeth will not be separated or moved apart (Fig 11). In these patients, the molar to be hemisected remains intact during orthodontics. This patient would require 2 to 3 month recall visits with the periodontist to ensure that the furcation defect does not lose bone during orthodontic treatment. By keeping the tooth intact during the orthodontics, it simplifies the finishing and tooth movement for the orthodontist.

After orthodontics, endodontic therapy must be performed on both roots of the tooth (Fig 11). Following this, periodontal surgery is necessary to divide the tooth. Sulcular incisions are made, a flap is elevated buccal and lingual to the molar, and a fissure bur is used to carefully divide the

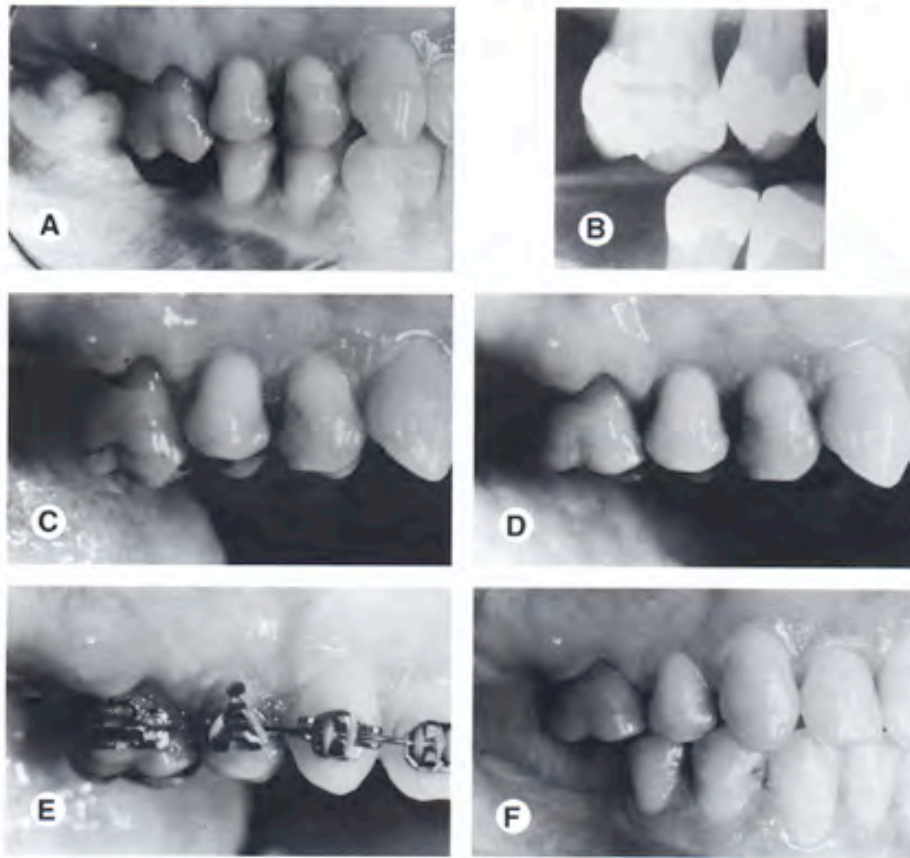


Figure 9. This patient showed overeruption of the maxillary right first molar and a marginal ridge defect between the second premolar and first molar (A). A pretreatment periapical radiograph (B) showed that the interproximal bone was flat. To avoid creating a hemiseptal defect, the occlusal surface of the first molar was equilibrated (C and D) and the malocclusion was corrected orthodontically (E and F).

crown and roots of the teeth. In some situations, the process is more difficult if the furcation is positioned toward the apices of the tooth. After the tooth has been divided, the bone is recontoured around each of the roots and the tissue is allowed to heal. If the roots are short and tapered, the crowns that restore the two halves of the tooth could be splinted together. If the solder joint of the splinted teeth is positioned toward the occlusal, the patient can clean interproximally in the area of the previous furcation.

In some patients requiring hemisection of a mandibular molar with a Class III furcation, it may be advantageous to push the roots apart during orthodontic treatment (Fig 12). If the hemisected molar will be used as an abutment for a bridge following orthodontics, moving the roots apart orthodontically will permit more favorable restoration and splinting across the adjacent edentulous space.

In the latter situation, hemisecting the tooth, endodontic therapy, and periodontal surgery

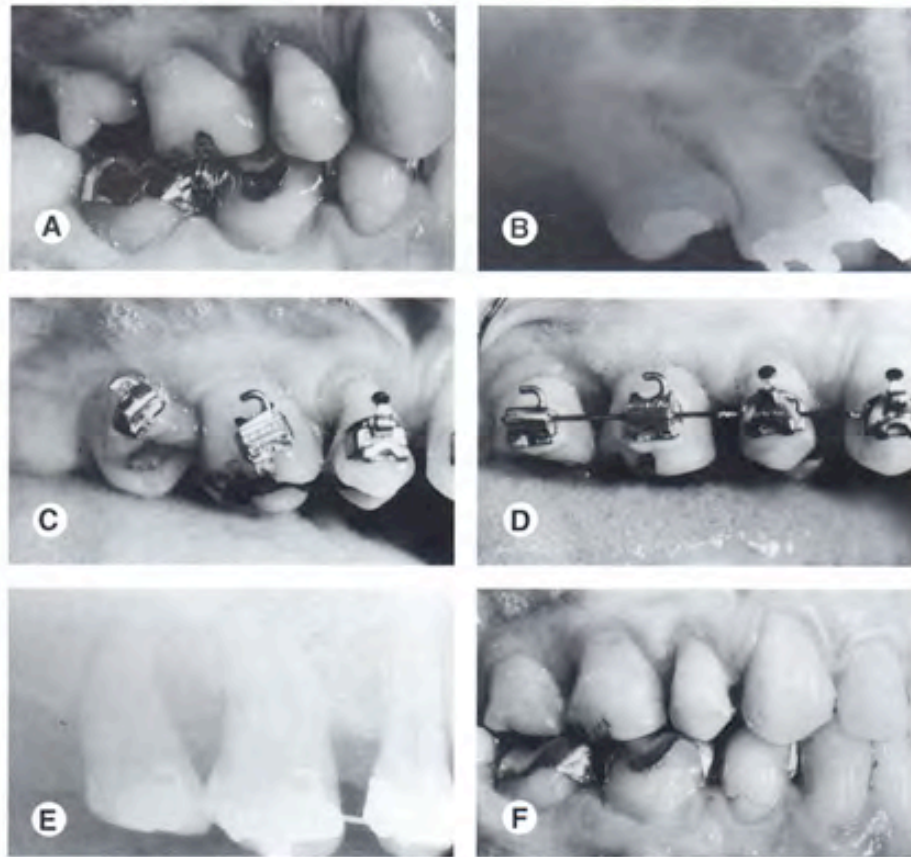


Figure 10. Before orthodontic treatment, this patient had significant mesial tipping of the maxillary right first and second molars causing marginal ridge discrepancies (A). The tipping produced root proximity between the molars (B). To eliminate the root proximity, the brackets were placed perpendicular to the long axis of the teeth (C). This method of bracket placement facilitated root alignment and elimination of the root proximity, as well as leveling of the marginal ridge discrepancies (D, E and F).

must be completed before the start of orthodontic treatment (Fig 12). After these procedures have been completed, the orthodontist may place bands or brackets on the root fragments and use a coil spring to separate the roots. The amount of separation is determined by the adjacent edentulous space and the occlusion in the opposing arch. About 7 or 8 mm of space may be created between the roots of the hemisected molar. This process eliminates the origi-

nal furcation problem and allows the patient to clean the area with greater efficiency.

In some molars with a Class III furcation, the tooth will have short roots, advanced bone loss, fused roots, or some other problem that prevents hemisection and crowning of the fragments. In these patients, it may be more advisable to extract the tooth with a furcation defect and place an osseointegrated implant (Fig 13). If this type of plan has been adopted, the timing of the ex-

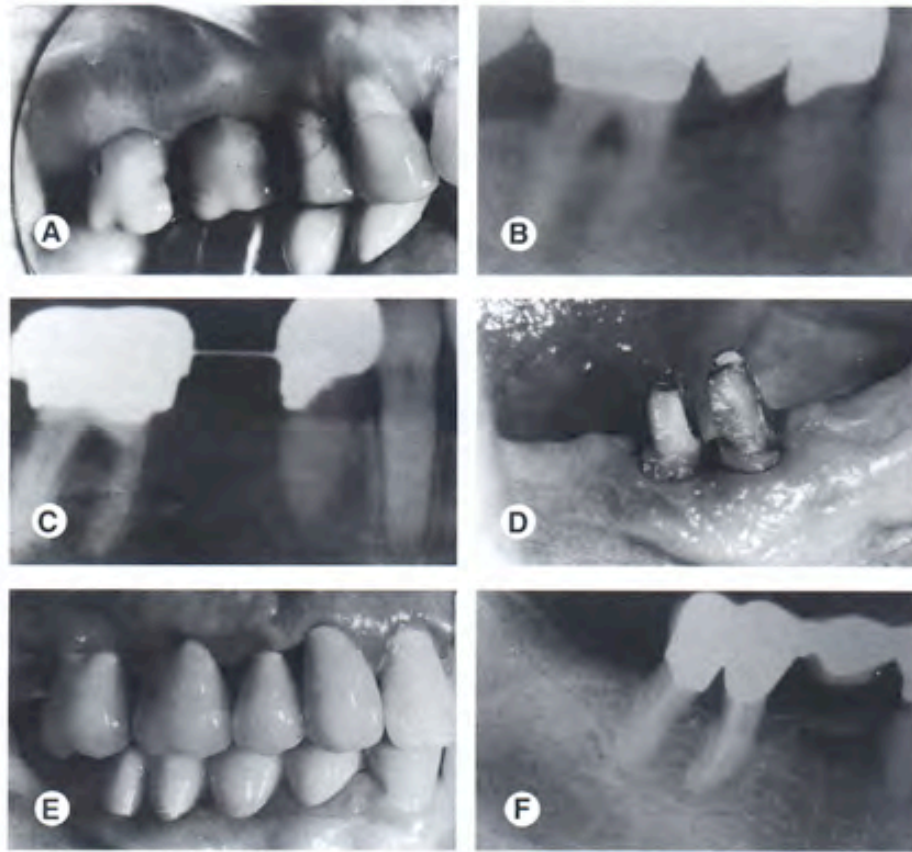


Figure 11. This patient had a Class III furcation defect before orthodontic treatment (A and B). Orthodontic treatment was performed and the furcation defect was maintained by the periodontist on 2 month recalls until after orthodontic treatment (C). After appliance removal, the tooth was hemisected (D) and the roots were restored, and splinted together (E). The final periapical radiograph (F) shows that the furcation defect has been eliminated by hemisecting and restoring the two root fragments.

traction and placement of the implant can occur at any time relative to the orthodontic treatment. In some situations, the implant could be used as an anchor to facilitate orthodontic treatment.

The implant must remain embedded in the bone for 6 months after placement before it can be loaded as an orthodontic anchor. It must be placed precisely so that it will not only provide an anchor for tooth movement, but may also be used as an eventual abutment for a crown or bridge. If the implant will not be used as an anchor for orthodontic movement, the implant

may be placed after the orthodontic treatment has been completed. Considerations regarding timing will be determined by the patient's restorative treatment plan.

Root Proximity

When roots of posterior teeth are in close proximity, the ability to maintain the periodontal health and the accessibility for restoration of these adjacent teeth may be compromised. However, if the patient is undergoing orthodontic therapy, the roots can be moved apart and bone

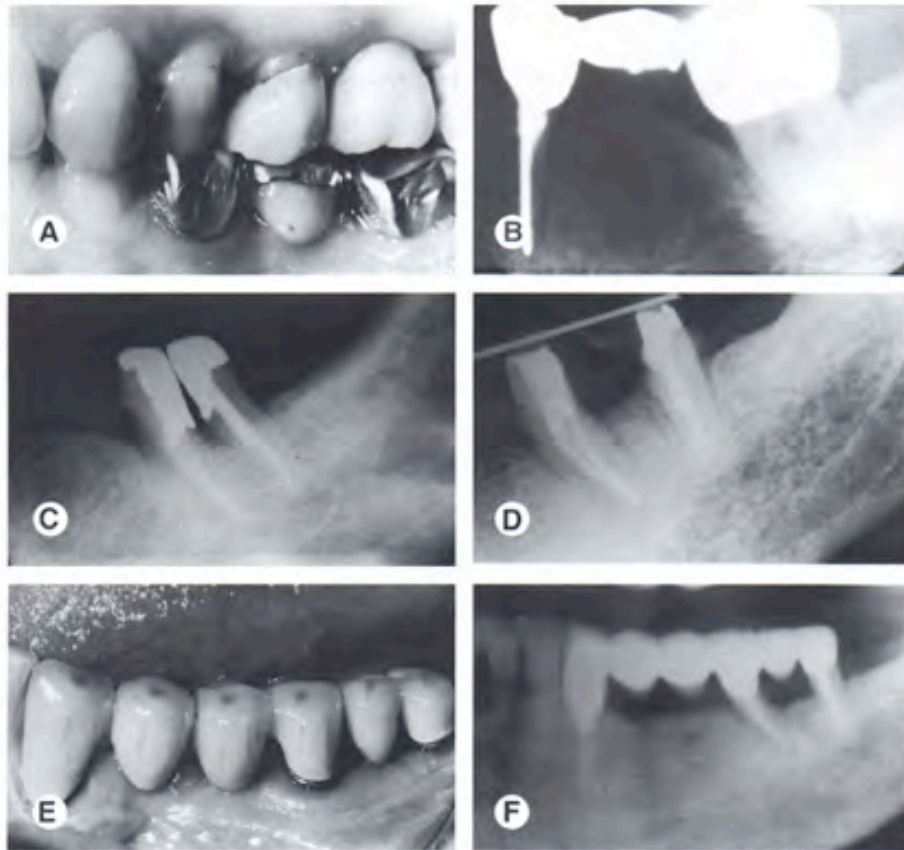


Figure 12. Before orthodontic treatment, this patient had a Class III furcation defect in the mandibular left second molar (A and B). Because the patient had an edentulous space mesial to the molar, the tooth was hemisected (C) and the root fragments were separated orthodontically (D). After orthodontic treatment, the root fragments were used as abutments to stabilize a multi-unit posterior bridge (E and F).

will be laid down between the adjacent roots. This will open the embrasure beneath the tooth contact, provide additional bone support, and enhance the patient's access to the interproximal region. This generally improves the periodontal health of this area.

If orthodontic treatment will be used to move roots apart, the orthodontist must be aware of this plan before bracket placement. It is advantageous to place the brackets so that the orthodontic movement to separate the roots will begin with the initial archwires. Therefore, brackets

must be placed obliquely to facilitate this process. To determine the progress of orthodontic root separation, radiographs will be needed to monitor the status. Generally, 2 to 3 mm of root separation will provide adequate bone and embrasure space to improve periodontal health. During this time, the patient should be maintained by their restorative dentist or periodontist to ensure that a favorable bone response will occur as the roots are moved apart. In addition, these patients will need occasional occlusal adjustment to recontour the crown as

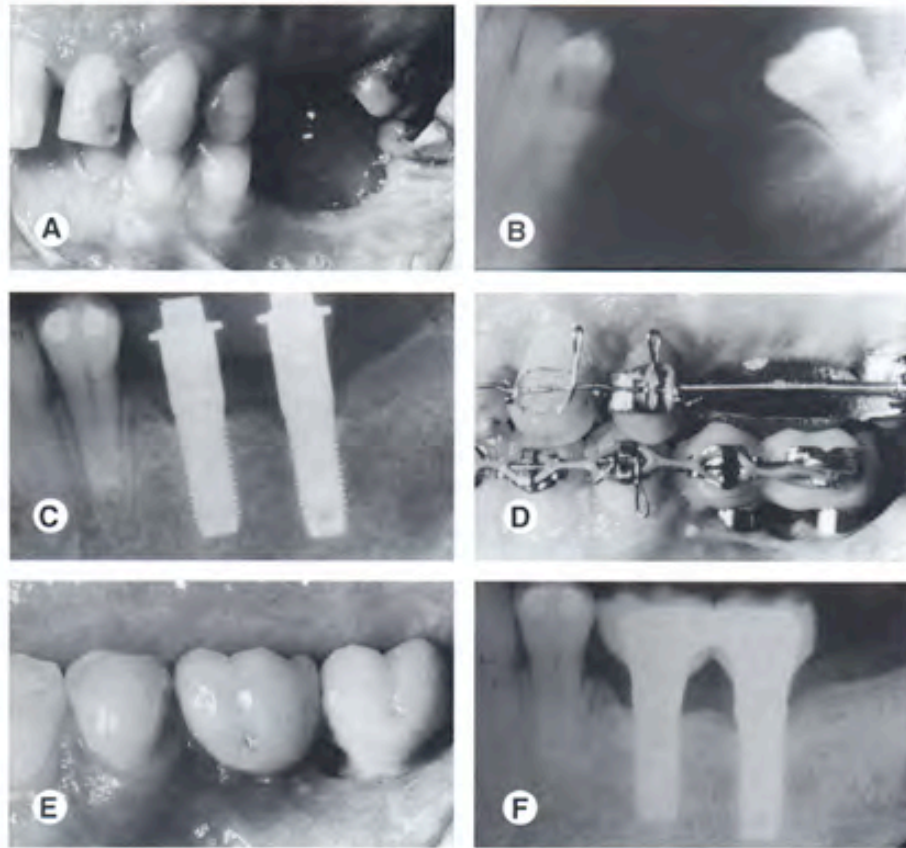


Figure 13. This patient was missing several teeth in the mandibular left posterior quadrant (A). The mandibular left third molar had a Class III furcation defect and short roots (B). The third molar was extracted and two implants were placed in the mandibular left posterior quadrant (C). The implants were used as anchors to facilitate orthodontic treatment (D) and to help reestablish the left posterior occlusion (E and F).

the roots are moving apart. As this happens, the crowns may develop an unusual occlusal contact with the opposing arch. This should be equilibrated to improve the occlusion.

Hopeless Teeth

Patients with moderate to advanced periodontal disease may have specific teeth that are deemed hopeless and normally would be extracted before orthodontics. However, these teeth can be useful for orthodontic anchorage, if the periodontal inflammation can be controlled (Fig 14).

In moderate to advanced cases, some periodontal surgery will be necessary around the hopeless tooth. When the flaps are reflected, debridement of the roots of the hopeless tooth may be all that is necessary to control inflammation during the orthodontic process. The important factor is to maintain the health of the bone on the adjacent teeth. Rigidly enforced 3 month periodontal recall is imperative during this process.

Following orthodontic treatment, there is a six month period of stabilization before reevaluating the periodontal status. Occasionally, the

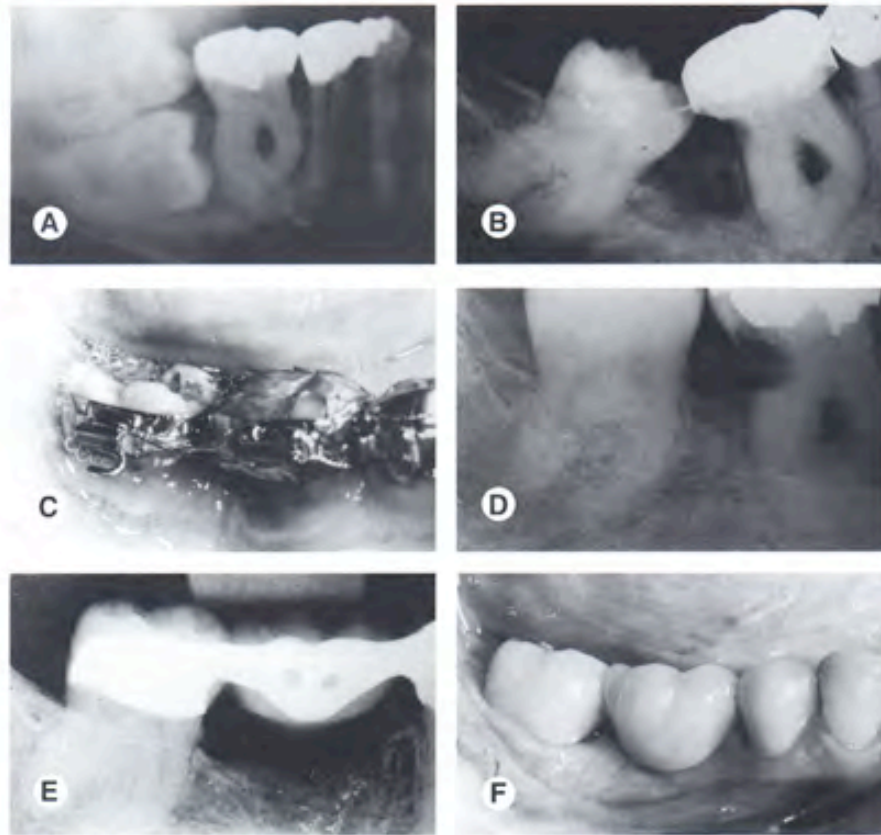


Figure 14. This patient had an impacted mandibular right second molar (A). The mandibular right first molar was periodontally hopeless because of an advanced Class III furcation defect. The impacted second molar was extracted, but the first molar was maintained as an anchor to help upright the third molar orthodontically (B, C and D). After orthodontic uprighting of the third molar, the first molar was extracted and a bridge was placed to restore the edentulous space (E and F).

hopeless tooth may be so improved after orthodontic treatment that it is retained. However, most of the time, it will require extraction (Fig 14), especially if other restorations are planned in the segment. Again, these decisions need to be negotiated between the specialists, restorative dentist and the patient.

Postorthodontic Periodontal Treatment

After orthodontic treatment has been completed, the patient should remain on a 3 month

periodontal maintenance program.⁷³ It takes at least 6 months after band removal for adequate bone remodeling, cessation of mobilities, and narrowing of the periodontal ligaments. It is advisable at this point to take a new set of periapical radiographs. A reexamination is scheduled with the periodontist and a total periodontal reassessment of the patient is performed to evaluate further periodontal needs. Borderline pocket depth areas that may have been maintained during orthodontic treatment are potential candidates for osseous correction at this

time. Also, there may be areas of borderline attached gingiva that can become narrower during orthodontic treatment. These areas may require tissue grafting.

Occlusal adjustment is helpful to fine-tune the occlusion and diminish any fremitus from lateral interferences. This will further aid in healing of any widened periodontal ligament spaces. Occasionally, a nightguard is indicated to control parafunction. A maxillary nightguard is an excellent appliance for this purpose, and can also be used as a postorthodontic retainer. It may take up to a year after orthodontic treatment to complete the final phase of periodontal therapy. When the patient is periodontally stable, the restorative dentist can proceed with any restorative treatment.

Summary

This article has discussed and illustrated the benefits of integrating orthodontics and periodontics in the management of adult patients with underlying periodontal defects. The key to treating these types of patients is communication and proper diagnosis before orthodontic therapy as well as continued dialogue during orthodontic treatment. Not all periodontal problems are treated in the same way. Hopefully, this discussion of gingival recession, horizontal bone loss, intrabony defects, hemiseptal defects, furcation problems, root proximity, and periodontally hopeless teeth provides the clinician with a framework that will be helpful in treating these situations.

References

1. Knoch A, Zohn H, Deasy M, et al. Screening for periodontal disease: Radiographs versus PSR. *J Am Dent Assoc* 1996;127:749-756.
2. Van der Velden U. Probing force and the relationship of the probe tip to the periodontal tissues. *J Clin Periodontol* 1979;6:106-114.
3. Ramfjord SP. Indices for prevalence and incidence of periodontal disease. *J Periodontol* 1959;30:51-59.
4. Lang NP, Löe H. The relationship between the width of keratinized gingiva and gingival health. *J Periodontol* 1972;43:623.
5. Lindhe J, Swanberg G. Influence of trauma from occlusion on progression of experimental periodontitis in the beagle dog. *J Clin Periodontol* 1974;1:3.
6. Lindhe J, Nyman S. Long-term maintenance of patients treated for advanced periodontal disease. *J Clin Periodontol* 1984;11:504-514.
7. Gartrell JG, Mathews DP. Gingival recession: The condition, process, and treatment. *Dental Clin North Am* 1976;1:199-215.
8. Steiner GG, Pearson JK, Ainamo J. Changes of the marginal periodontium as a result of labial tooth movement in monkeys. *J Periodontol* 1981;52:514.
9. Dorfman HS. Mucogingival changes resulting from mandibular incisor tooth movement. *Am J Orthod* 1978;74:286.
10. Dorfmann H, Kennedy J, Bird W. Longitudinal evaluation of free autogenous gingival grafts: A four-year report. *J Periodontol* 1982;53:349-352.
11. Miller PD. Root coverage using a free soft tissue autograft following citric acid application. Part I. *Int J Periodont Rest Dent* 1982;2:65-70.
12. Langer B, Langer I. Subepithelial connective tissue graft technique for root coverage. *J Periodontol* 1985;56:715-720.
13. Schlager S. Osseous resection—a basic principle in periodontal surgery. *Oral Surg* 1949;2:316.
14. Ochsenheim C, Ross S. A re-evaluation of osseous surgery. *Dent Clin North Am* 1969;13:87.
15. Becker W, Becker BE. Treatment of mandibular 3-wall intrabony defects by flap debridement and expanded polytetrafluoroethylene barrier membranes. Long-term evaluation of 32 treated patients. *J Periodontol* 1993;64:1138-1144.
16. Shallhorn R, McClain P. Combined osseous composite grafting, root conditioning and guided tissue regeneration. *Int J Periodont Rest Dent* 1988;8:9-31.
17. Ingber J. Forced eruption. Part I. A method of treating isolated one and two wall intrabony osseous defects - rationale and case report. *J Periodontol* 1974;45:199-206.
18. Brown IS. The effect of orthodontic therapy on certain types of periodontal defects. I. Clinical findings. *J Periodontol* 1973;44:742-756.
19. Kramer GM. Surgical alternatives in regenerative therapy of the periodontium. *Int J Periodont Rest Dent* 1992;12:11-31.
20. Gould MSE, Picton DCA. The relation between irregularities of the teeth and periodontal disease. *Br Dent J* 1966;121:21.
21. Axelsson P, Lindhe J. The significance of maintenance care in the treatment of periodontal disease. *J Clin Periodontol* 1981;8:281.