

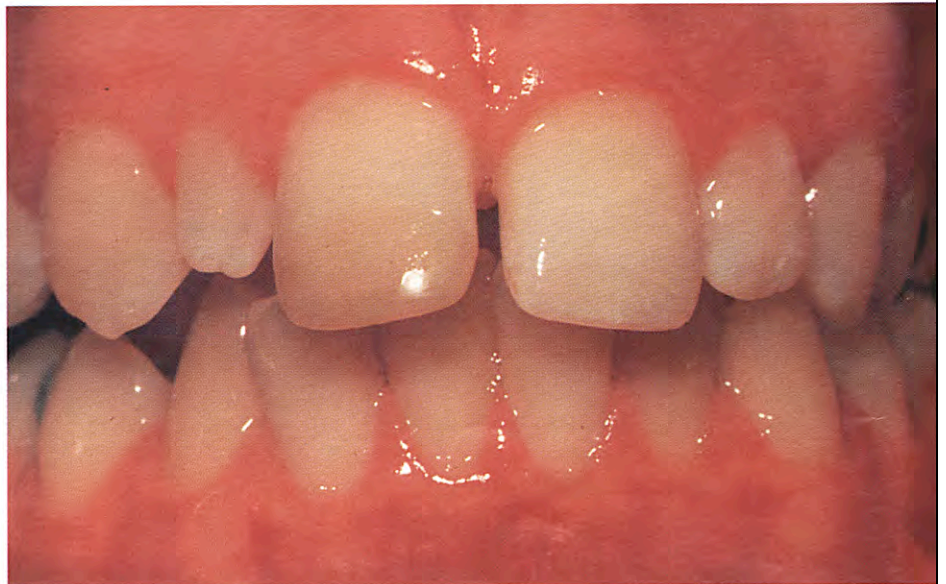Esthetics and Anterior Tooth Position: An Orthodontic Perspective Part III: Mediolateral Relationships

VINCENT KOKICH, DDS, MSD*

Tooth position plays a vital role in anterior dental esthetics. Part I in this series discussed the interdisciplinary treatment of uneven crown lengths of the maxillary incisors. In Part II, problems with the vertical location of anterior teeth were addressed. In the final portion of this three-part series, problems in the mediolateral position of the maxillary anterior teeth are identified.

ASYMMETRIC CROWN WIDTHS

Usually, the widths of the maxillary central and lateral incisors are symmetric. In other words, the widths of contralateral incisors are equal. In addition, there is generally a balanced proportion between the widths of the maxillary central incisor, lateral incisor, and canine. This balanced relationship is generally referred to as the "golden proportion." However, occasionally the width of the maxillary lateral incisor is smaller than normal (peg-shaped). This negatively affects the balance, proportion, and symmetry of the maxillary anterior teeth. This hereditary defect in tooth width is unesthetic.

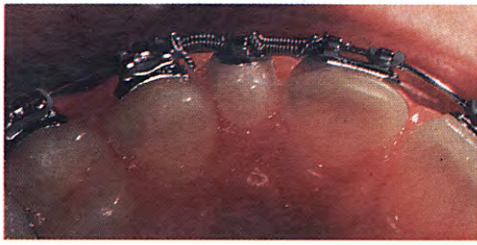


A

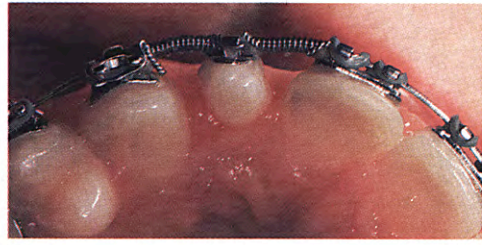In some situations, there is sufficient space to restore the narrower peg-shaped lateral incisor. However, in some patients, there is insufficient interproximal space for the restoration. In these situations, the adjacent central incisor and canine may be moved apart orthodontically. This simple and rapid tooth movement will provide sufficient space to temporarily restore the lateral incisor. Immediate temporary

restoration of proper tooth width is advisable to avoid shifting of the adjacent teeth during the final portion of the orthodontic therapy. Extra space should be created to permit adequate finishing of the interproximal surfaces of the temporary restoration. Final restoration of the tooth should follow orthodontic stabilization with decreased postorthodontic mobility and altered gingival form.

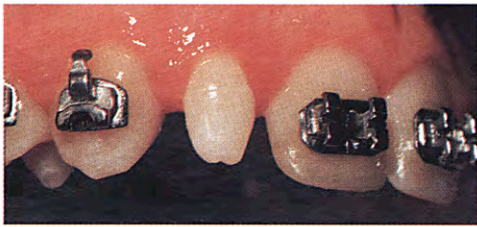
*Professor and Director, Graduate Orthodontic Research, University of Washington School of Dentistry, Seattle, Washington



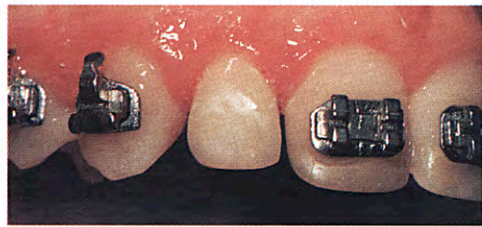
B



C

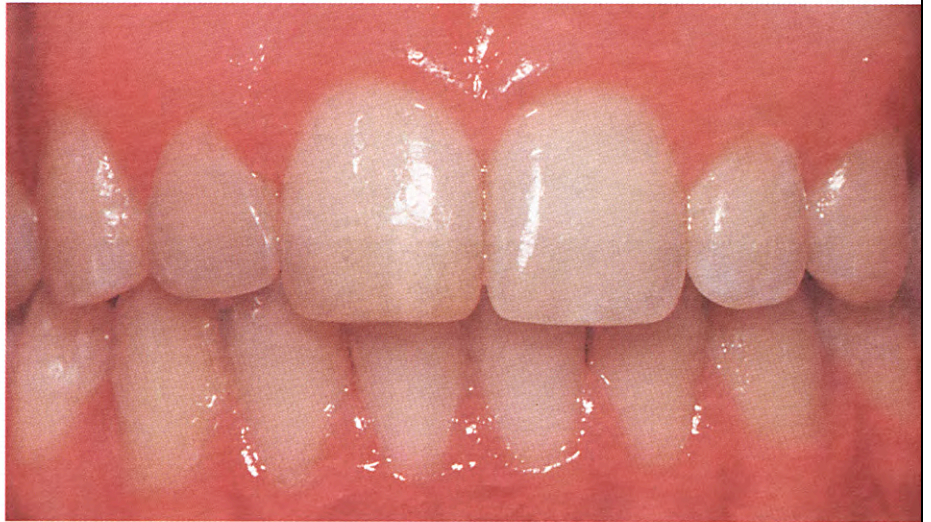

D



E

Figure 1A–F. This patient had a malformed, peg-shaped maxillary right lateral incisor. There was not enough space to restore the tooth to its proper width. Coil springs were used to open space interproximally. After space opening, the bracket was removed and the tooth was temporarily restored during the orthodontic therapy. Symmetry and balance have been recreated by restoring the maxillary right lateral incisor to its proper width.

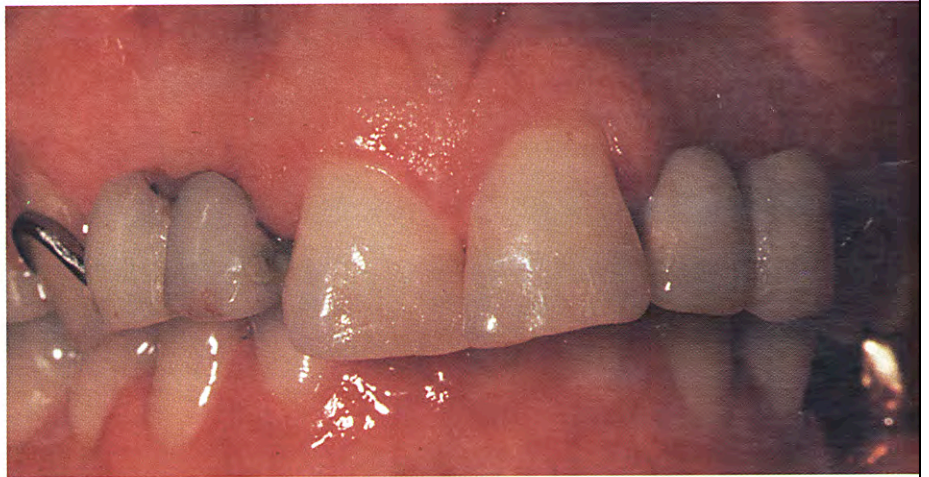

F

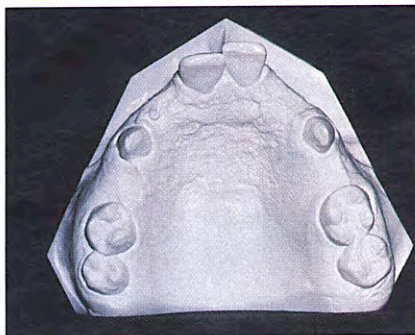
Esthetics and Anterior Tooth Position: An Orthodontic Perspective. Part III: Mediolateral Relationships

INADEQUATE PONTIC WIDTH

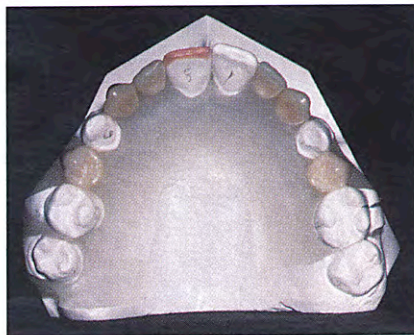
When patients are missing several anterior teeth, the remaining teeth can drift, resulting in insufficient pontic width. As mentioned in the previous section, the proportional widths of the anterior teeth should exhibit not only symmetry, but also proportional balance. If abutments have drifted significantly, the restorative dentist must compromise pontic width. However, it is possible to recreate adequate pontic width orthodontically. In this situation, evaluation of the case with the prosthetic requirements in mind is critical. Consultation with the restorative dentist in combination with a diagnostic wax set-up is beneficial to determine not only the proper pontic widths for adequate esthetics, but also to ensure that the teeth will occlude correctly.



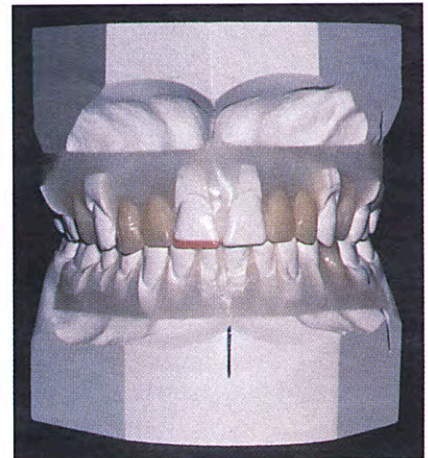
A



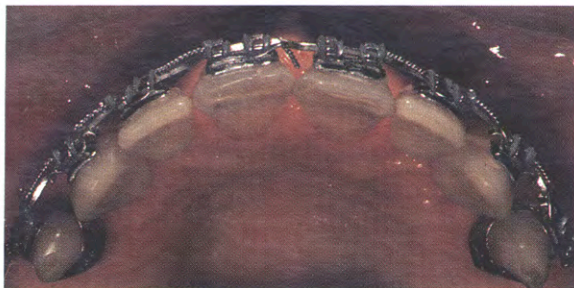
B



C



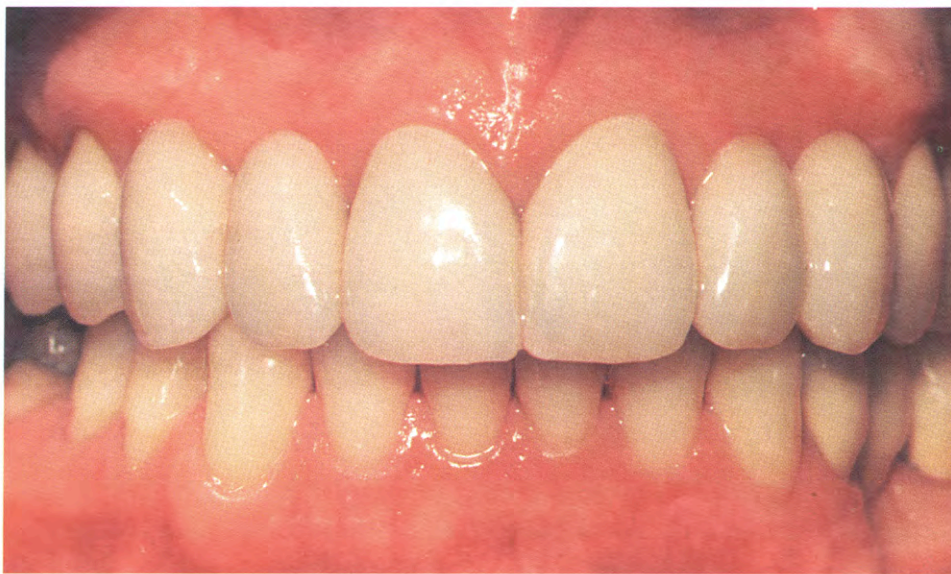D



E

Figure 2A–F. This patient is congenitally missing the maxillary right and left lateral incisors, and the first and second premolars. There was insufficient space for properly sized lateral incisor and canine pontics. A diagnostic wax set-up was created to determine not only the proper esthetic width of the pontics, but also confirm proper occlusion. Plastic teeth of the proper width were selected and placed in the set-up. During orthodontic therapy, these teeth were contoured and placed on the orthodontic arch wire. This careful coordination of treatment resulted in the best esthetic result by producing symmetric and balanced anterior pontic width.

Plastic teeth should be incorporated into the diagnostic set-up. These may be removed by the orthodontist, bracketed, and attached to the orthodontic arch wire to maintain proper pontic width during orthodontic finishing. In this way, the proper balance and symmetry of pontic width can be obtained in an interdisciplinary manner, producing the best esthetic result for the patient.



F

Esthetics and Anterior Tooth Position: An Orthodontic Perspective. Part III: Mediolateral Relationships

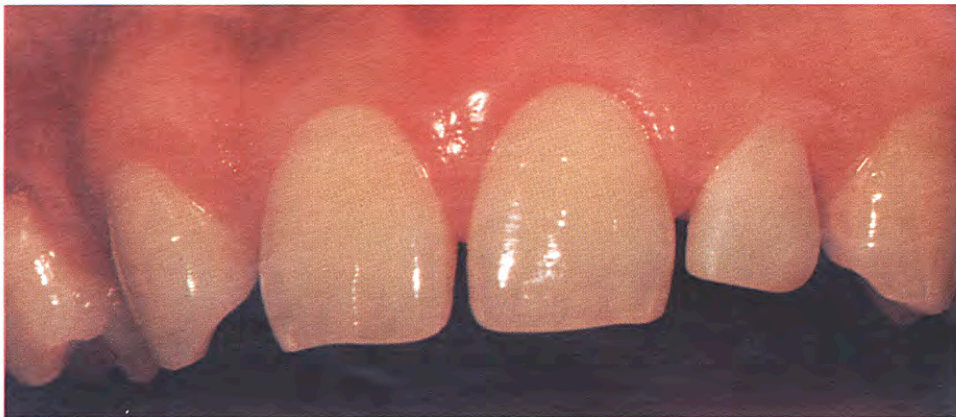MIDLINE DEVIATION

In most patients, the maxillary dental midline will coincide with the facial midline. The maxillary dental midline is assessed by locating the tip of the papilla between the maxillary central incisors. The papilla should be located beneath the center of the philtrum of the upper lip. In most situations, the contact point between the central incisors will lie immediately beneath the central incisor papilla. However, in some patients, the papilla and the contact point may deviate to the left or right of the facial midline. Deviations in the maxillary dental midline are always due to missing teeth. If maxillary teeth have been extracted or are

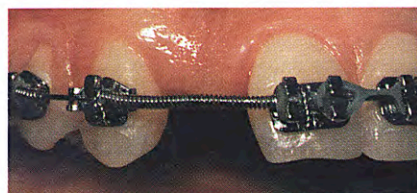
congenitally missing unilaterally, the maxillary anterior dental midline will naturally shift toward the affected side. If the tooth is missing in the anterior region, the midline deviation will be greater. If a tooth is missing from the posterior portion of the dental arch, the midline deviation will be less significant.

The most common midline deviation is due to congenitally missing maxillary lateral incisors. When this problem occurs unilaterally at a young age, the adjacent teeth shift toward the affected side. These problems may be corrected through an interdisciplinary approach of orthodontics and restorative dentistry. The midline may be corrected

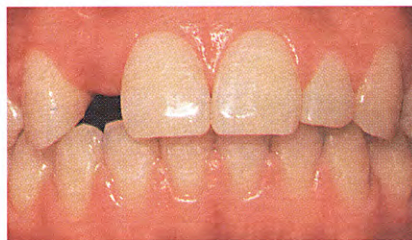and space may be opened for the maxillary lateral incisor by placing a coil spring between the central incisor and canine. As the space is opened, the central incisor contact point will shift toward the center of the upper lip. After the midline has been centered, a plastic tooth should be placed on the arch wire to maintain the proper midline relationship during orthodontic finishing. At the conclusion of orthodontic therapy, either a conventional anterior bridge, a resin-bonded bridge, a cantilevered bridge, or an implant may be placed in the edentulous space. The final restoration will naturally be enhanced by not only correcting the midline, but also creating the appropriate pontic width.



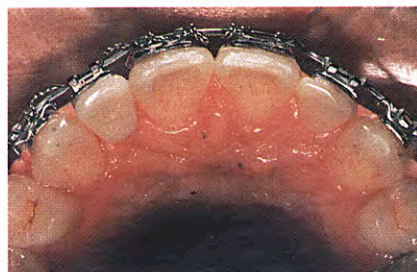A



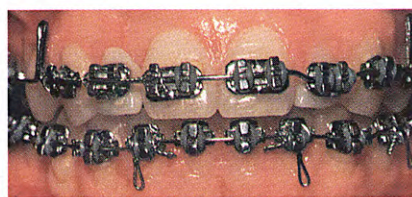B



E

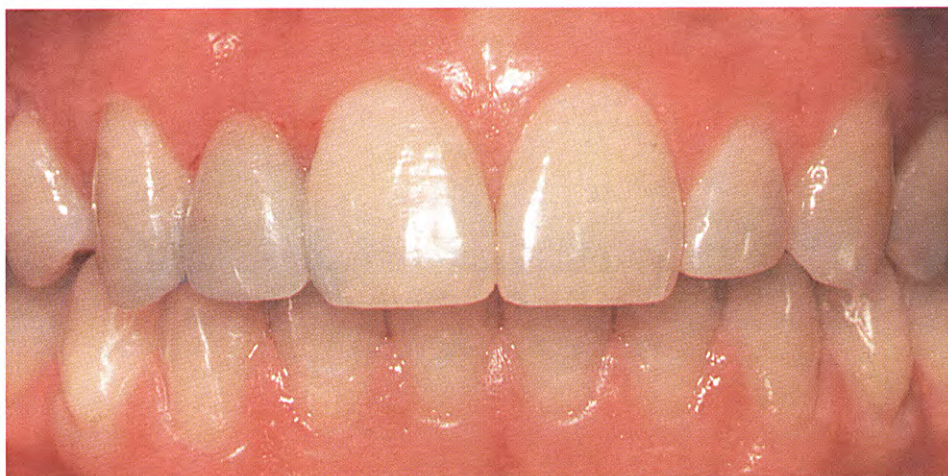

C



D

Figure 3A-F. This patient is congenitally missing the maxillary right lateral incisor. As a result, the maxillary dental midline deviated significantly to the right side. A coil spring was used to orthodontically push the maxillary central incisor toward the facial midline. This created pontic space for the right lateral incisor. The space was maintained temporarily during orthodontics with a plastic tooth. After orthodontic therapy, a resin-bonded bridge was placed to restore the edentulous space.



F

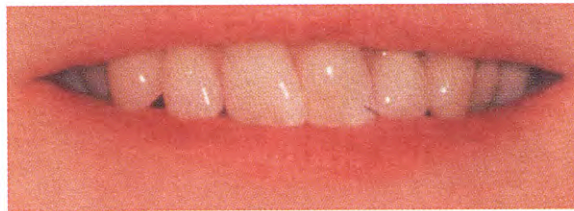Esthetics and Anterior Tooth Position: An Orthodontic Perspective. Part III: Mediolateral Relationships

IMPROPER INCISAL ANGULATION

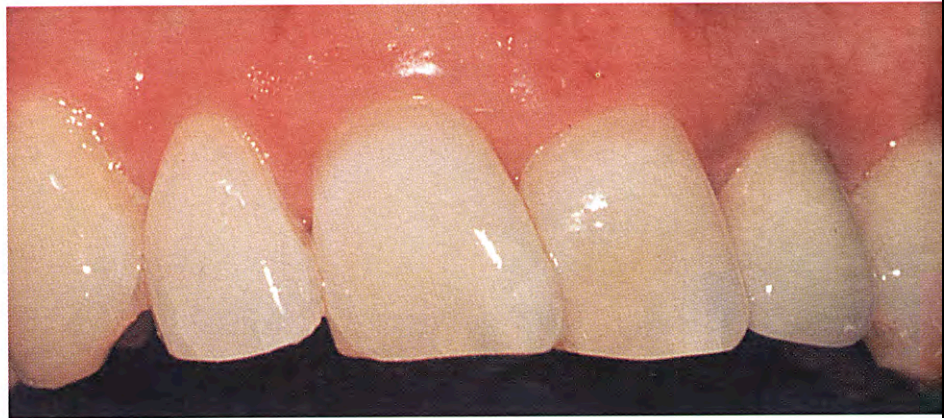In some patients, the mediolateral inclination of the maxillary incisors will deviate from the long axis of the face. In some patients, this is not readily apparent because of asymmetric wear of the incisal edge. In these patients, the papilla is located immediately beneath the philtrum of the lip. However, the incisal contact may be located lateral to its proper midline position. This is not a midline deviation. This problem is due to axial tipping of the maxillary incisors.

In this situation, if the incisal edge has worn unevenly, interdisciplinary orthodontics and restorative dentistry are required to recreate proper axial inclination and incisal morphology. In this unusual situation, the brackets on the maxillary incisors are not placed parallel to the incisal edges of the teeth. The bracket slot is placed perpendicular to the long axis of the tooth. It is important to place the bracket using a radiograph that depicts the true axial inclination of the central incisors. As the tooth root realigns, the true incisal edge discrepancy will be recognized. In this situation, after proper root positioning has been achieved, the incisal edges should be temporarily restored to facilitate proper orthodontic finishing and tooth positioning. After the completion of orthodontic therapy, the patient will eventually require final restoration of the unevenly abraded

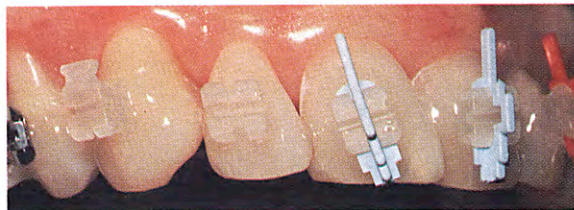
incisors with either ceramic crowns or porcelain laminate veneers. By proper mediolateral positioning of the roots of the central incisors, maxillary anterior dental esthetics can be enhanced.



A



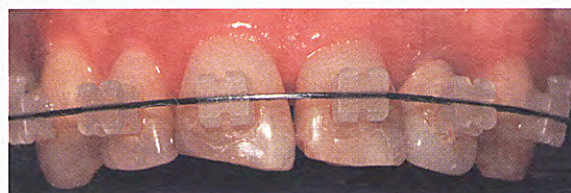
B



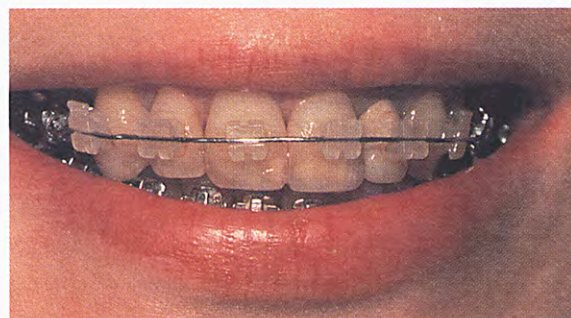
C

SUMMARY

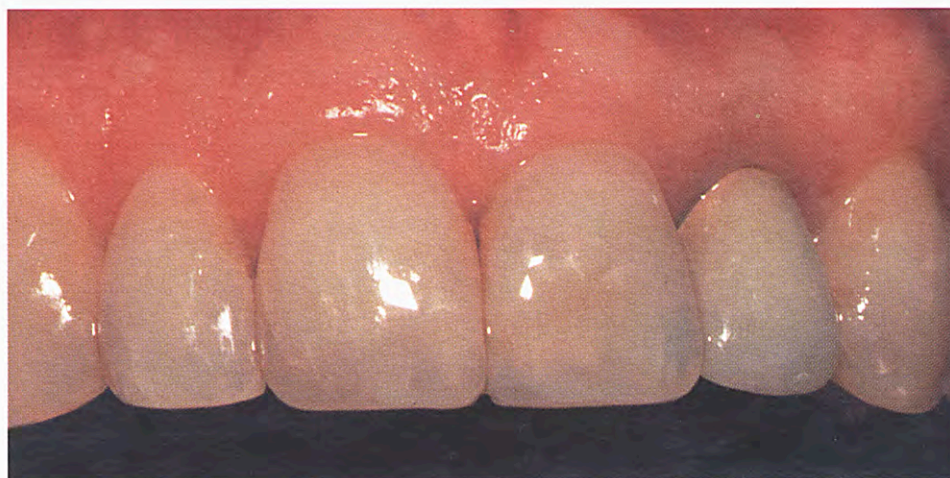This article has discussed the mediolateral relationship of the maxillary anterior teeth relative to esthetics. In this dimension, common problems include asymmetric crown widths, inadequate pontic width, midline deviation, and improper angulation of the maxillary incisors. In all four of these situations, the proper solution depends on a coordinated, interdisciplinary approach involving well-planned and well-choreographed orthodontics and restorative dentistry.



D



E



F

Figure 4A–F. The mediolateral inclination of the maxillary central incisors does not coincide with the long axis of the face. This axial deviation is masked by the uneven wear of the incisal edges of the centrals. In order to correct the axial inclination and place the roots in their proper orientation, the slots on the orthodontic brackets are aligned perpendicular to the long axis of the roots. This magnified the uneven wear of the central incisors, requiring temporary composite restoration and eventual permanent restoration with either a porcelain crown or a porcelain laminate.

Reprint requests: Vincent G. Kokich, DDS, MSD, University of Washington School of Dentistry, Department of Orthodontics, SM-46, Seattle, WA 98195
© 1993 Decker Periodicals Inc.